

Widefield Imaging: A Review of Current Technology

Editor's Note: A wealth of research in the past few years has centered on the use of widefield imaging of the retina for a number of applications: to identify potential biomarkers of disease progression and/or early harbingers of disease development or progression; to discern if there may be distinct phenotypic presentations of common pathologies; and to better understand the pathophysiology of many retinal diseases. According to many experts, widefield imaging techniques may some day have a significant impact on patient care, although much research is still needed to determine the clinical relevance of peripheral findings and to overcome optical shortcomings inherent to widefield imaging (eg, flattening a three-dimensional image to a two-dimensional image with resulting image distortion). Nevertheless, this intriguing technology has sparked much interest and discussion.

Currently, 3 manufacturers of imaging devices produce platforms capable of imaging beyond the typical field of view. Retina Today invited researchers using each platform to discuss the rationale for widefield imaging and enumerate particular advantages each platform has in this application. What follows is by no means an exhaustive review of widefield imaging in retina; rather, it is intended to provide a starting point for comparing current technologies and modalities.

Applications of Ultra-Widefield Imaging Are Likely to Expand in the Future and Significantly Alter Patient Care



By Rishi P. Singh, MD

The understanding of retinal disease has accelerated rapidly with a growing foundation of clinical evidence supplied by ultra-widefield (UWF) retinal imaging. As we continue to validate the diagnostic and prognostic significance of pathology in the retinal periphery, the ability to visualize and evaluate these features in an efficient and patient-friendly manner will become more important. Furthermore, with an aging population swelling the ranks of patients with retinal disorders and related systemic diseases, the need to distribute care across specialties and delivery systems will increase the demand for efficient sharing of UWF retinal images and their full integration with electronic medical records.

Optos UWF retinal imaging systems, including the 200Tx and Daytona, use a scanning laser ophthalmoscope and a unique ellipsoid mirror to create a virtual focal point inside the eye that enables a single-shot capture of

the central retina and periphery. Both systems offer multimodal UWF imaging, including color and fundus autofluorescence (AF; Figure 1). For color images, green and red lasers are engaged simultaneously to allow visualization of retinal substructures from the sensory retina and retinal pigment epithelium to the choroid. The 200Tx also adds fluorescein angiography (FA), allowing visualization of the retinal circulation.

Based on experience with the 200Tx, 4 capabilities—the breadth of the images themselves, the ease with which they can be manipulated and shared, the availability of both FA and AF imaging modalities, and the complete registration of images across these modalities—make these Optos UWF systems particularly useful in contemporary practice and ongoing research.

THE WIDEST UWF

Optos UWF imaging systems produce a 200° view of the retina (about 82% of the surface area) in a single non-contact digital capture. This is the widest imaging capability of any available digital imaging system.¹ The equivalence in sensitivity between optomap images and dilated ETDRS standard 7-field photography for evaluating the severity of retinal pathology, such as diabetic retinopathy

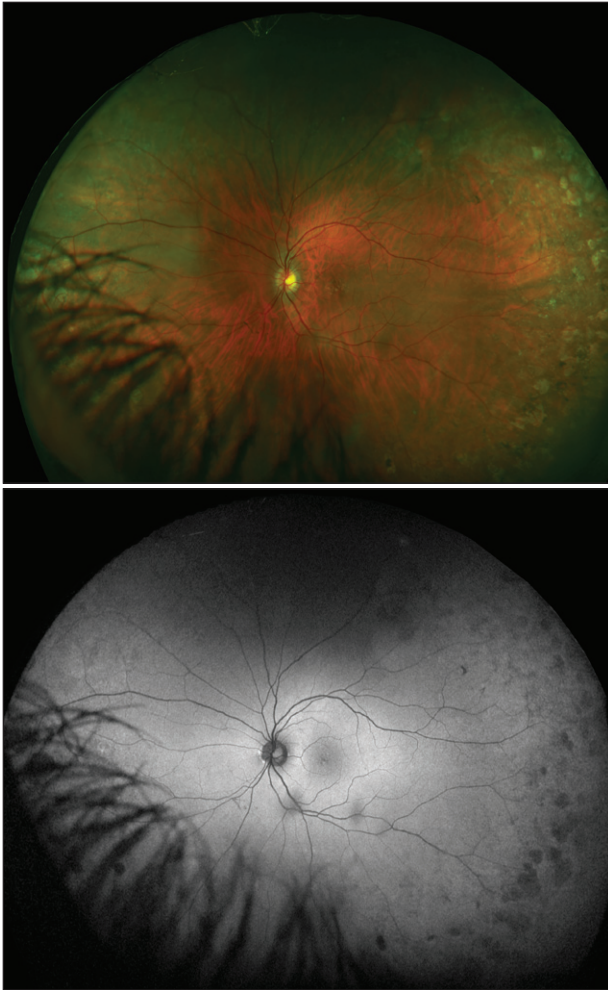


Figure 1. Images showing the peripheral changes associated with age-related macular degeneration in optomap color (top) and AF (bottom).

and diabetic macular edema, has been established by several studies.²⁻⁴ Findings on optomap FA images have also been correlated with evidence of macular pathology identified by spectral-domain optical coherence tomography in patients with central retinal vein occlusion.⁵ A number of authors have noted that the faster image capture and wider retinal area that can be visualized in an optomap provide a distinct advantage in clinical practice. There is growing confirmation that Optos UWF imaging provides information not readily available with traditional imaging techniques, including identification of pathology that might otherwise be missed in a variety of retinal diseases.⁶⁻⁸ The significantly greater amount of information about retinal pathologies available with optomap images, compared with ETDRS standard 7-field photography, could alter the classification schemes and management approaches for diseases like diabetic retinopathy (DR; Figure 2).⁹

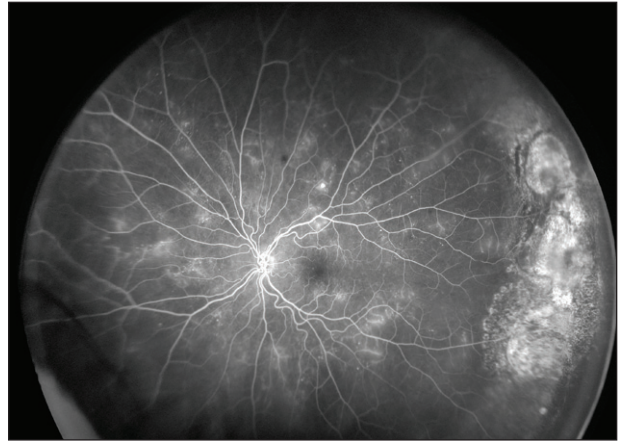


Figure 2. Ultra-widefield optomap FA image illustrating the varied peripheral changes associated with DR.

To validate this potential, the clinical significance of pathologic findings in the periphery and their correlation with disease course and treatment selection are being investigated extensively on the Optos UWF platform. In 1 study, the additional peripheral lesions identified on optomap images resulted in a more severe assessment of DR than that suggested by ETDRS fields in 10% of eyes evaluated.¹⁰ There is ongoing research to determine the impact of these peripheral lesions on the progression of the disease. A recent study highlighted that in 48% of patients with noninfectious uveitis, additional information captured with the optomap technology led to different treatment decisions than those based on traditional imaging and clinical examination.¹¹ Other researchers have examined the relationship of peripheral retinal non-perfusion and the disease course in patients with retinal vein occlusion,¹² and a multicenter research project is beginning this year to investigate the utility in a larger patient population. UWF imaging could prove particularly useful in changing how and when we use panretinal photocoagulation or anti-VEGF therapy (Figure 3). For example, laser is not typically used in patients with significant peripheral nonperfusion, but this practice may change as we learn more from clinical studies with UWF.

Optos is now developing eye steering and auto montage functionality to further expand the ability to examine the retinal periphery. Software enhancements are also helping to make these high-resolution UWF images more clinically precise. The latest update to the image viewing software includes functionality that addresses the bias inherent in projecting a curved surface on a flat plane (the “Greenland effect” familiar to map makers). Because it registers all Optos UWF imaging modalities, this functionality provides the ability to overlay images and compare changes over time or between modalities;

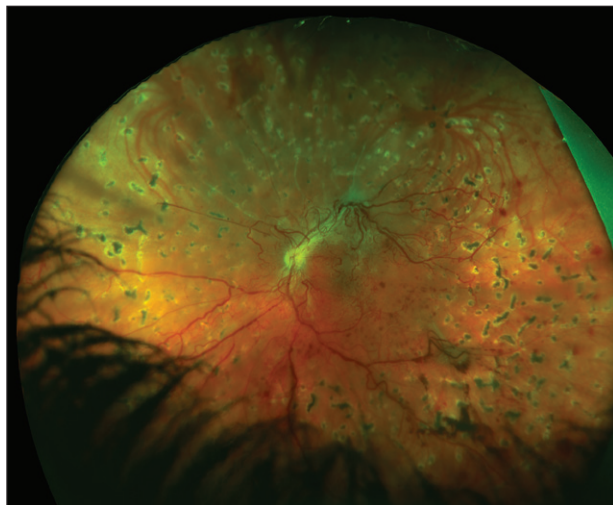


Figure 3. Color optomap image of diabetic retinopathy treated with panretinal photocoagulation.

it also makes possible the system's three-dimensional simulation feature. Optos is already developing technology to expand imaging capabilities even further into the periphery, and research efforts are underway to determine if retinal surface area, including regions of nonperfusion in DR, can be precisely measured in square millimeters.^{13,14} Such quantification would be an important addition to our ability to diagnose and manage retinal disease with UWF images.

EASY UWF IMAGE ACCESS

In a busy multioffice practice or an integrated care setting, the ability to annotate, share, and store UWF images is nearly as important to their clinical utility as is the quality of the images. Furthermore, compatibility of imaging systems with electronic medical record platforms has become essential. The 200Tx and Daytona feature OptosAdvance, a sophisticated image management system that is compatible with all types of computers and tablets, that allows manipulation of optomap images and the importation of DICOM-compatible images and reports from other diagnostic equipment. Images can be uploaded and stored in Optos' secure cloud-based archive, so these large files can be readily viewed at any workstation in the practice or shared with other offices. In addition, permanent storage in Optos' cloud obviates the need for archiving on portable media at the office. The system also facilitates referrals because the optomap images can be accessed remotely over the Internet without the need to install software in the receiving practice.

These capabilities make the Optos UWF imaging systems particularly well suited for emerging telehealth screening and disease management programs. In pub-

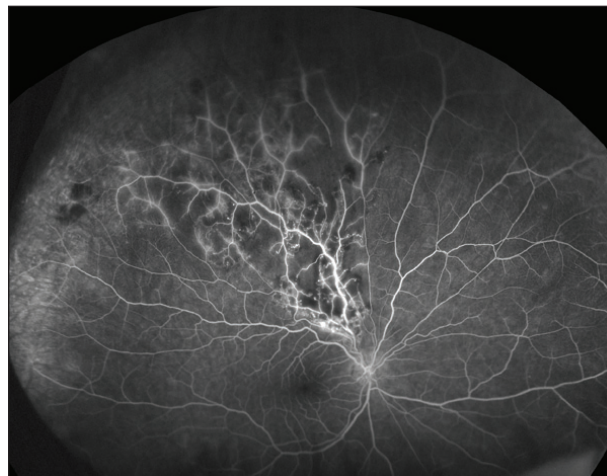

Figure 4. Ultra-widefield optomap FA image of a branch retinal vein occlusion showing the extent of peripheral nonperfusion.

lished results from a recent evaluation in such a setting, use of Optos UWF imaging increased the identification of DR by 17%, with lesions documented in the periphery suggesting greater disease severity in 9% of cases. From a practice efficiency standpoint, less than 3% of the UWF images were considered ungradable (a reduction of 71% from standard imaging), and image evaluation time was decreased by 28%.¹⁵ In a similar telescreening study, 22% of patients with diabetes were found to have nondiabetic retinal pathology.¹⁶

For several years, Cleveland Clinic has provided remote readings of nonmydriatic retinal images produced by a commercial system that allows visualization of 20% of the retina for an executive health program that manages 4000 patients in concierge medical practices. Because of the potential advantages of UWF imaging in screening programs, we are now comparing the Optos Daytona system to standard fundus photography in a 6-month evaluation.

MULTIMODAL UWF IMAGING

The ability to perform both UWF FA and AF on the same platform is another key advantage of the 200Tx. The use of UWF FA to document peripheral ischemia in patients with DR is becoming more widespread. Studies have correlated peripheral ischemia with diabetic macular edema and other vascular complications in the central macula (Figure 4).^{17,18} UWF FA has also been shown to enhance the detection and determination of severity of vascular changes associated with uveitis.¹⁹

Optos UWF AF imaging has been employed to identify several distinct patterns of peripheral abnormalities in age-related macular degeneration that correlate with clinical findings and risk factors for the disease's

“Because each imaging modality provides a different picture of retinal pathology, the ability to accurately compare images has great clinical value. It is common to have to toggle between images and locate disease findings based on retinal landmarks.”

progression²⁰; it has also shown utility in the characterization and management of rhegmatogenous retinal detachments.²¹ Optos' next-generation UWF system will reportedly also include indocyanine green angiography capability, thus further enhancing the clinical potential of multimodal imaging.^{22,23}

PANMODAL IMAGE REGISTRATION

Because each imaging modality provides a different picture of retinal pathology, the ability to accurately compare images has great clinical value. It is common to have to toggle between images and locate disease findings based on retinal landmarks; however, Optos' UWF imaging systems provide complete registration of optomap images across all modalities, permitting the clinician to localize features of interest and utilize complementary imaging techniques to perform a complete evaluation. For example, we often compare areas of vascular leakage identified in UWF FA with the UWF color image of the same region in order to accurately assess structural features. Because each of these image types is obtained in a single, noncontact capture, the Optos UWF systems become useful, for example, in the evaluation of infants and children. Optos UWF systems have allowed successful capture of UWF FA images in retinopathy of prematurity, incontinentia pigmenti, and other childhood retinal disorders.²⁴⁻²⁷

CONCLUSION

Although it is not yet the standard of care for diagnosis or management of retinal disease, there are many clinical situations in which I already incorporate UWF imaging in my practice. With the explosion of research in the area—there were more than 75 papers reporting results from investigational applications of Optos UWF retinal imaging at the 2014 Association for Research in Vision and Ophthalmology meeting alone—it is evident that UWF technology will take a more prominent role in the clinical care of patients with retinal disease.

Rishi P. Singh, MD, is a staff physician and medical director of the clinical systems office in Cleveland Clinic, and an assistant professor of ophthalmology at Case Western Reserve University. He has served as a consultant to and/or served on the speakers boards for Bausch + Lomb, Genentech, Regeneron, Thrombogenics, and Zeiss. His institution has received grants from Alcon, Genentech, and Regeneron. Dr. Singh may be reached at rrishisingh@gmail.com.

1. Witmer MT, Parlitsis G, Patel S, et al. Comparison of ultra-widefield fluorescein angiography with the Heidelberg Spectralis noncontact ultra-widefield module versus the Optos Optomap. *Clin Ophthalmol*. 2013;7:389-394.
2. Kernt M, Hadi I, Pinter F, et al. Assessment of diabetic retinopathy using nonmydriatic ultra-widefield scanning laser ophthalmoscopy (optomap) compared with ETDRS 7-field stereo photography. *Diabetes Care*. 2012;35(12):2459-2463.
3. Silva PS, Cavallerano JD, Sun JK, et al. Nonmydriatic ultrawide field retinal imaging compared with dilated standard 7-field 35-mm photography and retinal specialist examination for evaluation of diabetic retinopathy. *Am J Ophthalmol*. 2012;154(3):549-559.e2.
4. Liegl R, Liegl K, Cekic L, et al. Nonmydriatic ultra-wide-field scanning laser ophthalmoscopy (optomap) versus two-field fundus photography in diabetic retinopathy. *Ophthalmologica*. 2014;231(1):31-36.
5. Tsui I, Franco-Cardenas V, Hubschman J, et al. Ultra wide field fluorescein angiography can detect macular pathology in central retinal vein occlusion. *Ophthalmic Surg Lasers Imaging* 2012;43:257-262.
6. Brown K, Sewell JM, Trempe C, et al. Comparison of image-assisted versus traditional fundus examination. *Eye and Brain*. 2013;5(1):1-8.
7. Leder HA, Campbell JP, Sepah YJ, et al. Ultra-wide-field retinal imaging in the management of non-infectious retinal vasculitis. *J Ophthalmic Inflamm Infect*. 2013;3(1):30.
8. Nicholson BP, Nigam D, Miller D, et al. Comparison of wide-field fluorescein angiography and nine-field montage angiography in uveitis. *Am J Ophthalmol*. 2014;157(3):673-677.
9. Wessel MM, Aaker GD, Parlitsis G, et al. Ultra-wide-field angiography improves the detection and classification of diabetic retinopathy. *Retina*. 2012; 32:785-791.
10. Silva PS, Cavallerano JD, Sun JK, et al. Peripheral lesions identified by mydriatic ultrawide field imaging: distribution and potential impact on diabetic retinopathy severity. *Ophthalmology*. 2013;120(12):2587-2595.
11. Campbell JP, Leder HA, Sepah YJ, et al. Wide-field retinal imaging in the management of noninfectious posterior uveitis. *Am J Ophthalmol*. 2012;154:908-911.e2.
12. Singer M, Tan CS, Bell D, et al. Area of peripheral retinal nonperfusion and treatment response in branch and central retinal vein occlusion [published online ahead of print, April 11, 2014]. *Retina*.
13. Croft DE, Van Hemert J, Wykoff CC, et al. Precise montage and metric quantification of retinal surface area from ultra-widefield fundus photography and fluorescein angiography. *Ophthalmic Surg Lasers Imaging Retina*. 2014;45:312-317.
14. Croft DE, Wykoff CC, Brown DM, et al. Quantification of ultra-widefield retinal images. *Retina Today*. 2014;9(4):59-62.
15. Silva PS, Cavallerano JD, Tolls D, et al. Potential efficiency benefits of nonmydriatic ultrawide field retinal imaging in an ocular telehealth diabetic retinopathy program. *Diabetes Care*. 2014;37(1):50-55.
16. Haddad NMN, Silva PS, Cavallerano J, et al. Nondiabetic retinal findings using ultrawide field imaging in a diabetes ocular telehealth program. Poster presented at: Association for Research in Vision and Ophthalmology Annual Meeting; May 4-8, 2014; Orlando, FL.
17. Wessel MM, Nair N, Aaker GD, et al. Peripheral retinal ischaemia, as evaluated by ultra-widefield fluorescein angiography, is associated with diabetic macular oedema. *Br J Ophthalmol*. 2012;96(5):694-698.
18. Sim DA, Keane PA, Rajendram R, et al. Patterns of peripheral retinal and central macula ischemia in diabetic retinopathy as evaluated by ultra widefield fluorescein angiography. *Am J Ophthalmol*. 2014;158(1):144-153.e1.
19. Hong BK, Khanamiri HN, Rao NA. Role of ultra-widefield fluorescein angiography in the management of uveitis. *Can J Ophthalmol*. 2013;48:489-493.
20. Tan CS, Heussen F, Sadda SR. Peripheral autofluorescence and clinical findings in neovascular age-related macular degeneration. *Ophthalmology*. 2013;120(6):1271-1277.
21. Witmer MT, Cho M, Favarone G, et al. Ultra-wide-field autofluorescence imaging in non-traumatic rhegmatogenous retinal detachment. *Eye*. 2012;26:1209-1216.
22. Pang CE, Shah VP, Sarraf D, et al. Ultra-widefield imaging with autofluorescence and indocyanine green angiography in central serous chorioretinopathy. *Am J Ophthalmol*. 2014;158(2):362-371.e2.
23. Klufas MA, Yannuzzi NA, Pang CE, et al. Feasibility and clinical utility of ultra-widefield indocyanine green angiography. *Retina*. [in press].
24. Fung THM, Muqit MMK, Mordant DJ, et al. Noncontact high-resolution ultra-wide-field oral fluorescein angiography in premature infants with retinopathy of prematurity. *JAMA Ophthalmol*. 2014;132(11):108-110.
25. Patel CK, Fung THM, Muqit MMK, et al. Non-contact ultra-widefield imaging of retinopathy of prematurity using the Optos dual wavelength scanning laser ophthalmoscope. *Eye (Lond)*. 2013; 27(5):589-596.
26. Patel CK, Fung THM, Muqit MMK, et al. Noncontact ultra-widefield retinal imaging and fundus fluorescein angiography of an infant with incontinentia pigmenti without sedation in an ophthalmic office setting. *J AAPOS*. 2013;17(3):309-311.
27. Tsui I, Valentina F, Hubschman J, et al. Pediatric retinal conditions imaged by ultra wide field fluorescein angiography. *Ophthalmic Surg Lasers Imaging Retina*. 2013;44(1):59-67.

Widefield Capability Adds Versatility to Imaging



By Giovanni Staurengi, MD

Since the first fundus camera became commercially available in 1926, scientists and manufacturers have been working to expand its 20° field of view to show more of the retina.¹ For years, clinicians relied on mosaic images made up of 7 standard fields, which together provided approximately 75° of view. However, this technique does not provide a view of the entire periphery, and peripheral pathology is often missed. Additionally, mosaic images are combined from different time points, meaning dynamic imaging processes such as fluorescein angiography (FA) cannot be acquired in mosaic form.

The development of confocal scanning laser ophthalmoscopy (cSLO) in the early 1980s spurred significant advances in both widefield imaging and angiography. The use of confocal technology to suppress scattered light results in very high-resolution retinal images. The advent of cSLO also made possible simultaneous acquisition of indocyanine green (ICG) and fluorescein angiographies.

With Heidelberg Engineering's Spectralis and HRA systems, widefield imaging is possible with 2 different add-on lenses. The first option is the Staurengi 230 retina lens (Optical Instruments), a contact lens that provides a 150° field of view. The second, newer option is the noncontact Ultra Widefield Module, which delivers evenly illuminated, undistorted, high contrast images in the far periphery.

STAURENGHI LENS

I developed the Staurengi lens to be used in conjunction with the HRA. The lens is a contact system that provides a 5-fold increase in the fields of view of the cSLO and allows imaging with minimal dilation of the eyes. It is able to detect retinal details well beyond the traditional fundus camera and SLO. As well, this lens has been successful in confirming findings from indirect ophthalmoscopy and in facilitating retinal photocoagulation and vitreoretinal surgery. The HRA with the Staurengi lens has the ability to acquire dynamic high-speed angiography, including simultaneous FA and ICG angiography.

By their nature, contact lenses are generally able to offer a wider view than noncontact lenses. In my clinic, I perform all of the imaging myself using both contact and noncontact lenses interchangeably. An example of 1 advantage of the Staurengi contact lens is the ability

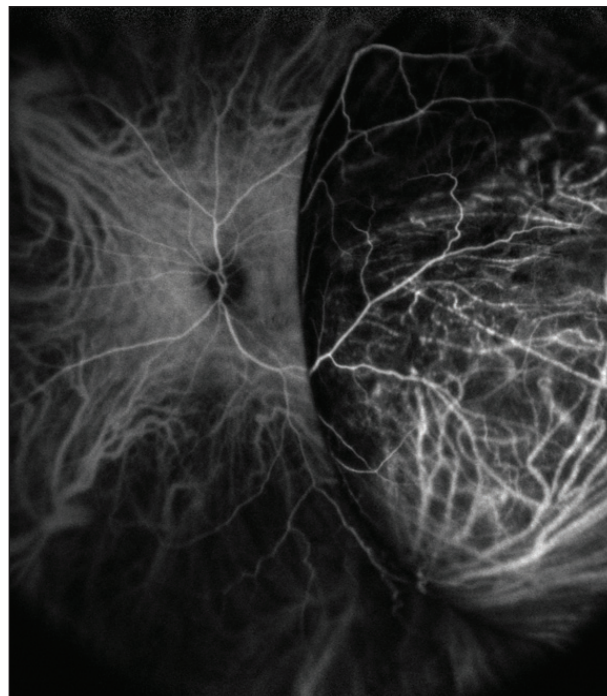


Figure 1. An ocular melanoma as depicted with ICG angiography widefield imaging.

to perform a dynamic examination on a vortex vein varix. By applying pressure with the lens, injecting the dye, and then releasing the pressure created with the lens, it is possible to see all of the changes of the vessels.

NONCONTACT ULTRA WIDEFIELD MODULE

The newer Ultra Widefield Module from Heidelberg is a noncontact lens, which has a number of advantages over contact lenses. The primary advantage is ease of use. Imaging with the Ultra Widefield Module is very simple. It is less invasive and more comfortable for the patient.

Perhaps the most significant feature of the Heidelberg system is its value in performing widefield video angiography. Pathology that may be missed when capturing single frames can often be caught with video imaging, and review of the dynamic video offers a better opportunity to detect small leaks.

In addition, with the multimodal Heidelberg system, it is possible to capture simultaneous FA and ICG angiography on video. With this system, angiography can also be combined with OCT, multicolor, or any of the other cSLO imaging modalities.

UTILITY

Since the early days of widefield imaging, we have discovered that there is often influential pathology in the far

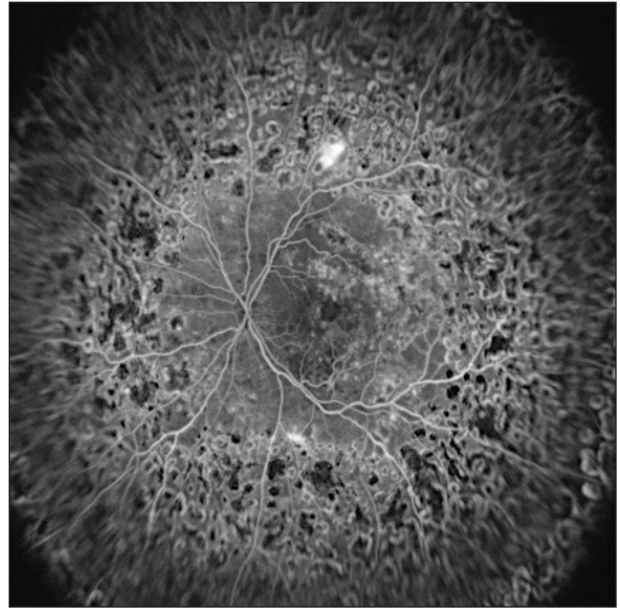
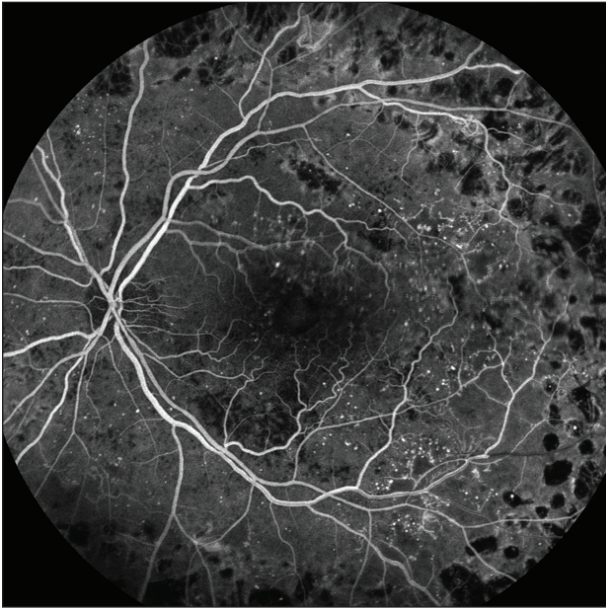


Figure 2. An example of a diabetic retinopathy patient who was treated with laser. The difference between the 55° field of view (left) and the widefield FA (Starengchi lens, right) is obvious.

periphery that cannot be detected with a conventional fundus camera. We previously thought that the most important ischemic changes in cases of retinal vascular disease, such as vein occlusions and diabetic retinopathies, were in the midperiphery, but we have found that this is not true. Widefield imaging often shows choroidal neovascularization that is not visible in other approaches, and these disease characteristics may in turn influence disease persistence and progression.

Widefield imaging is also important in detecting and managing uveitis since the disease begins in the periphery. Pars planitis, an often asymptomatic intermediate stage of uveitis, may be characterized by an accumulation of exudate in the anterior periphery. This condition is likely to go undetected without widefield imaging.

Widefield imaging also allows physicians to find tumors in the far periphery. Ocular tumors can be easily misidentified, and treatment is based heavily on tumor appearance. If I see a brownish elevation, it is critical to distinguish whether it is a choroidal nevus or a choroidal melanoma, and the Spectralis allows for switching between imaging modalities for closer inspection.

When I first started using widefield imaging, 1 big advantage was the ability to perform targeted retinal photocoagulation. A complete widefield image generally reveals significantly more disease burden than a composite image of the 7 traditional fields developed in the ETDRS.² This enables surgeons to apply targeted

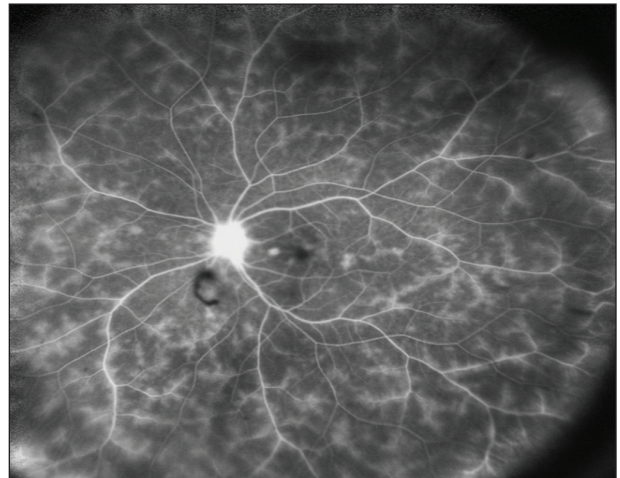


Figure 4. Widefield FA (Starengchi lens) of a patient with syphilis. Note that vasculitis is evident in the periphery.

laser treatment point-by-point where it is needed, rather than in a traditional panretinal mode.

CONCLUSION

Although there is still some conflicting data on how peripheral pathologies should impact treatment, the increased information provided with widefield imaging is invaluable. With noncontact lens technology, it is just as simple to acquire widefield imaging as a traditional fundus image, and Heidelberg makes it possible to do so without a large capital investment in a new imaging system. The more we use widefield imaging and ana-

lyze treatments and outcomes, the more precisely and effectively we will be able to treat our patients.

Giovanni Staurenghi, MD, is a professor of ophthalmology in the department of clinical science at Luigi Sacco Hospital at University of Milan, Italy. He developed the Staurenghi contact lens together with Ocular Instruments. Dr. Staurenghi may be reached via e-mail at giovanni.staurenghi@unimi.it.

1. Ciardella A, Brown D. Wide field imaging. In: Agarwal A, ed. *Fundus Fluorescein and Indocyanine Green Angiography: A Textbook and Atlas*. Thorofare, NJ: Slack Inc.; 2007:79-83.
2. Wessel MM, Aaker GD, Paritsis G, et al. Ultra-wide-field angiography improves the detection and classification of diabetic retinopathy. *Retina*. 2012;32:785-791.

En Face Imaging and the Ability to Perform OCT Angiography May Alter Patient Care



By Richard Rosen, MD,
and Patricia Garcia, MD

Widefield optical coherence tomography (OCT) imaging offers access to retinal details beyond the scope

of conventional macular OCT scanning. The ability to see the full optic nerve and macula along with lesions anywhere within the vascular arcades and beyond is an important addition to ophthalmologists' clinical diagnostic arsenal.

TECHNOLOGY OVERVIEW

The Avanti RTVue XR (Optovue) has become an increasingly important imaging resource in our busy retina center. Its high-speed 70 kHz OCT spectral-domain engine provides the ability to capture scans of 12 x 9 mm, as compared with the 6 mm scans typical of most OCT devices. The speed of image capture improves motion control, reducing movement artifacts and enabling near-instant image reconstruction. On-board proprietary software, developed in the laboratory of James Fujimoto, PhD, at Massachusetts Institute of Technology, can rapidly interlace 2 sets of OCT images, 1 horizontal and 1 vertical, to create a *fundus perspective* or *en face* image. This combined image delivers details from a broad area of the retina with the ability to display individual layers, such as the retinal pigment epithelium, choriocapillaris, nerve fiber layer, or ellipsoid layer, for selective examination. This function expands the clinician's visualization of the fovea or a lesion in the macula beyond the representation delivered by a slice from a single B-scan. Seeing details at their depth within the retina, over a wide expanse, provides a more

accurate picture of the extent of pathology and avoids the possibility of missing small lesions that appear only in certain slices. Because individual slices are typically only 10 to 12 μm in thickness with spaces in between, sampling errors are not uncommon, and certain small pathologies can be missed as the physician moves from one slice to the next.

The concept of en face OCT imaging was introduced in the early 2000s by Adrian Podoleanu, PhD, at the University of Kent. However, because they were constructed using time-domain OCT platforms, with each scan taking about 1 second, these first attempts at en face imaging were prone to motion artifacts. Additionally, the images could not be easily flattened to allow segmentation of individual retinal layers, making interpretation challenging and uninviting to busy clinicians. The imaging capabilities of the Avanti RTVue XR OCT have solved these limitations, enabling en face OCT imaging to become a practical clinical instrument.

OCT ANGIOGRAPHY

While en face imaging is a clinically useful tool on its own, it also enables the generation of OCT angiography, which can provide high-contrast images of retinal vessels—previously visible only with fluorescein angiography—immediately and without the need for dye injection. Fluorescein angiography has been the standard for vascular analysis since the early 1960s; however, it is not without risk of unpleasant side effects for the patient, including vomiting and anaphylaxis. OCT angiography

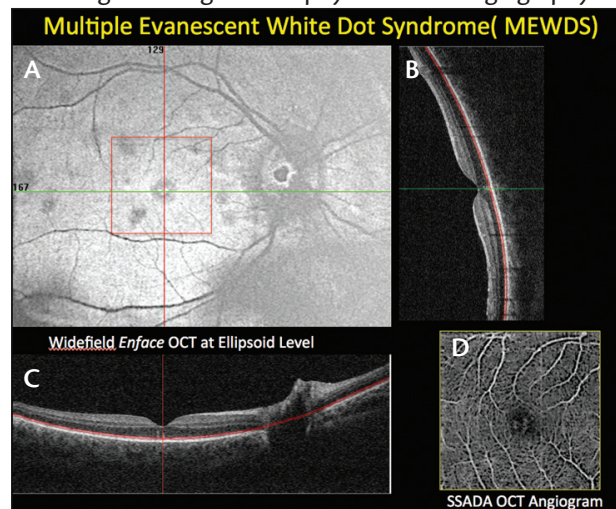


Figure 1. A widefield enface OCT study of a patient with multiple evanescent white dot syndrome. On the en face slice at the level of the ellipsoid zone line (A), the white dots appear dark gray. The OCT angiogram (D) highlights an intact vascular bed with a subfoveal disturbance also seen in cross-section on the B-scan OCT images (B and C).

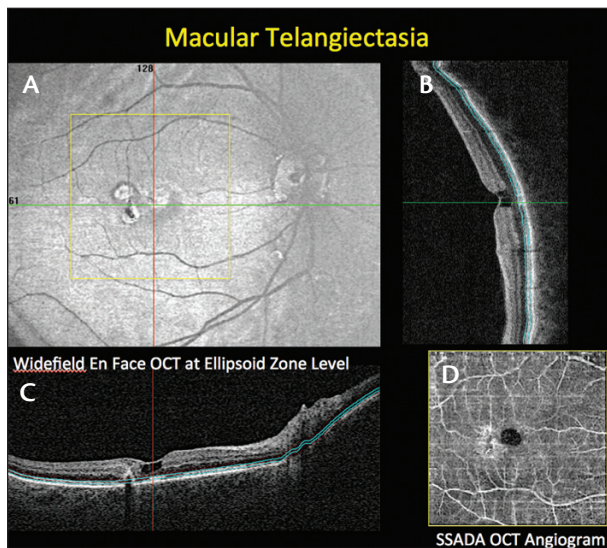


Figure 2. Images depicting some of the structural and vascular disturbances seen in macular telangiectasia. The widefield en face image (A) reveals some of the changes in macular anatomy with the condition. The OCT angiogram (D) reveals the vascular remodeling surrounding the fovea, while the B-scan OCT displays the characteristic cystoid degeneration of the outer retina (B and C).

holds the potential to provide a similar view of the vascular bed of the retina, highlighting areas of nonperfusion without the need for contrast injection. Areas of capillary remodeling, distortion of vessels secondary to traction or blockage, and abnormal vascular formations such as neovascular lesions can all be seen with this technique. Because OCT angiography is noninvasive and can be performed as part of a routine OCT examination, patients with vascular diseases can be followed for evidence of progressive capillary dropout without the need for frequent fluorescein studies. In fact, since there is no leakage of dye obscuring vascular outlines, the physician is provided with a detailed view of capillaries that are not always visible using fluorescein.

One unique advantage of OCT angiography is that it can be used to quantitatively analyze blood flow. Users can focus in on the flow of a particular lesion, monitor changes in flow to the optic nerve head, and follow changes over time or in response to therapy. Previously, measurements of blood flow were not practical in clinical settings because fluorescein studies are limited to time-to-fill, pattern of filling, and leakage recognition. Recent studies of OCT angiography at the Center for Ophthalmic Optics & Lasers Lab, under the direction of David Huang, MD, PhD, have demonstrated that a technique of OCT angiography called split-spectrum amplitude decorrelation angiography, or SSADA, can measure blood flow to

“One unique advantage of OCT angiography is that it can be used to quantitatively analyze blood flow. Users can focus in on the flow of a particular lesion, monitor changes in flow to the optic nerve head, and follow changes over time or in response to therapy.”

the optic nerve head and detect neovascular membranes in the subretinal avascular space in patients with age-related macular degeneration.^{1,2} This software is currently being optimized for the Avanti XR OCT. Using this technique, a retina specialist will be able to detect a neovascular membrane or determine when flow through a membrane undergoing treatment has reached a stage at which anti-VEGF treatments can be suspended or substantially reduced. OCT angiography can be segmented to display individual retinal capillary beds, allowing localization of pathologic changes to the specific capillary layers affected. OCT angiography using the SSADA software is in the final stages of development and should be released in the next few months. It promises to dramatically improve the management of patients with macular degeneration, diabetes, vein occlusions, and glaucoma.

THE FUTURE

As widefield OCT imaging continues to evolve, it will offer an expanding suite of diagnostic tools for more comprehensive and less invasive patient management. Fundus perspective en face OCT and OCT angiography will facilitate better correlation with multiple diagnostic modalities, such as color fundus images, micro- and macroperimetry, and multifocal electroretinography, to enhance our appreciation of the structure-function relationships that affect clinical ophthalmic diseases. ■

Richard Rosen, MD, is vice chair, director of research, and retina service chief at the New York Eye and Ear Infirmary of Mount Sinai. He is a clinical investigator for Optovue. Dr. Rosen may be reached at rrosen@nyee.edu.

Patricia Garcia, MD, is a research associate at the Advanced Retinal Imaging Center of the New York Eye and Ear Infirmary of Mount Sinai.

1. Jia Y, Bailey ST, Wilson DJ, et al. Quantitative optical coherence tomography angiography of choroidal neovascularization in age-related macular degeneration. *Ophthalmology*. 2014;121(7):1435-1444.

2. Jia Y, Wei E, Wang X, et al. Optical coherence tomography angiography of optic disc perfusion in glaucoma. *Ophthalmology*. 2014;121(7):1322-1332.