



Revealing Suspended Scattering Particles in Motion

OCTA Reveals Spurious Flow Signals

Figen SERMET(*), Sibel DEMIREL(**), Emin ÖZMERT(*)
Ankara University Faculty of Medicine, Department of Ophthalmology
Division of Medical and Surgical Retina
*Professor **Associate Professor

New techniques often generate novel findings - for example, the OCTA-mediated discovery of spurious flow signals generated by suspended scattering particles in motion (SSPiM). This previously unappreciated source of extravascular signals was first observed as a novel imaging feature in patients with exudative maculopathies; the same study showed that the signal could be reproduced by a suspension of intralipid particles in 1 percent gelatin (1).

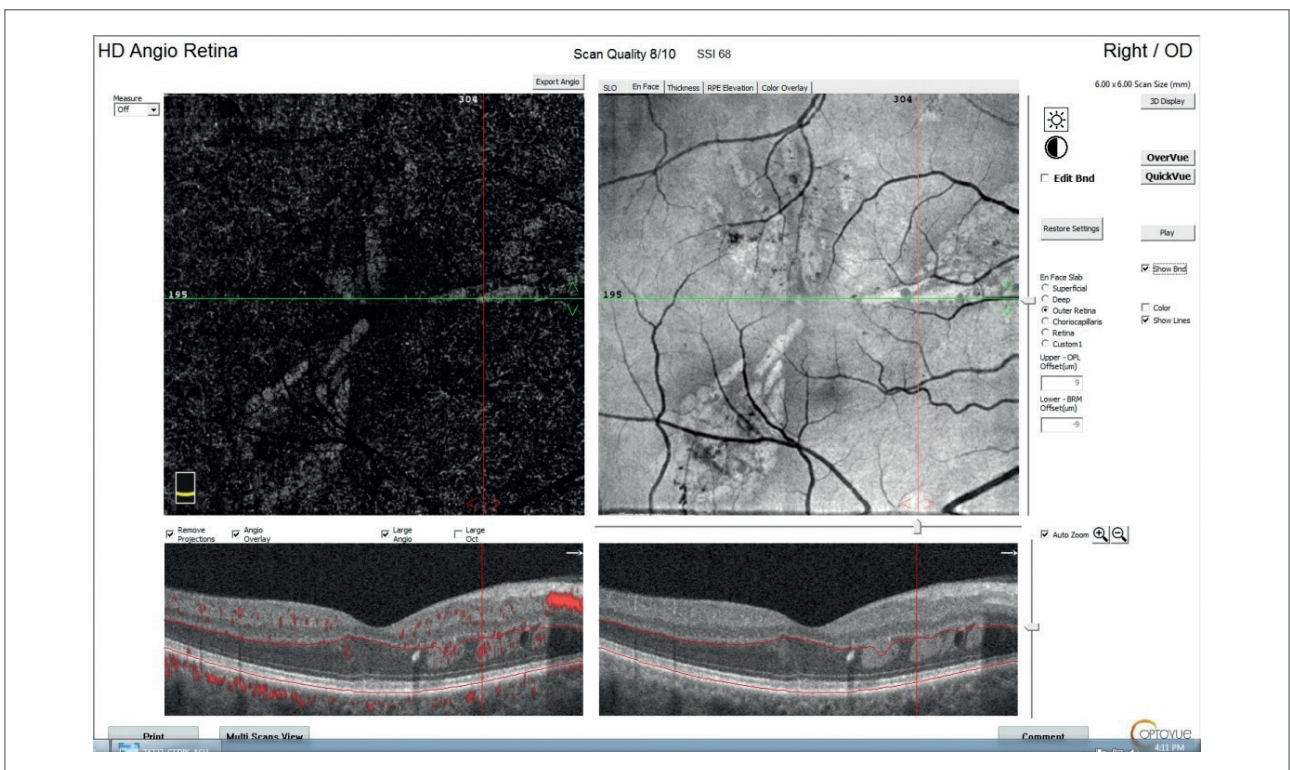


Figure 1: Multimodal imaging of right eye



In patients, fluid containing SSPiM shows up as oval or circular areas of increased OCTA decorrelation on flow signal overlaid cross-sectional and en face angiography images. These areas of hyperreflective fluid are generally found in the outer nuclear layer, adjacent to the outer plexiform layer, and are anatomically associated with hyperreflective material (HRM), particularly in the outer retinal layers. HRM may represent subclinical extravasation of lipoproteins and/or proteins secondary to breakdown of blood-retinal barrier, and is generally observed at the border between cystoid spaces and hyperreflective fluid.

Thus, SSPiM are associated with HRM foci; clinical examination may reveal coalesced HRM as a hard exudate comprising particles generally larger than 30 microns. This type of exudate can give rise to shadowing on structural OCT, but does not give rise to a decorrelation signal on OCTA. By contrast, projection artifacts caused by motion in the tissue above – produces an OCTA decorrelation signal that may mimic that of blood flow where there is no presence of in situ blood vessels. It is critical to distinguish between actual and spurious decorrelation signals when evaluating OCTA images. We are assisted in this aim by the Optovue 3D Projection Artifact Removal algorithm (3D PAR), which eliminates projection artifacts from the deeper layers. Nevertheless, we must take care to avoid confusing SSPiM with actual flow or with decorrelation signals associated with hyperreflective structures (the thresholding effect). Here, we report a case where differential diagnosis of flow signals

and SSPiM signals was facilitated by SD-OCT and OCTA imaging.

A 55-year-old man with diabetic macular edema presented with vision loss in his left eye. Medical records indicated a 20-year history of type 2 diabetes and hypertension, and cataract surgery one year previously. His medication regime included intravitreal anti-VEGF treatments for cystoid macular edema in each eye.

Ophthalmological examination indicated visual acuity of 1.0 in the right eye and 0.5 in the left eye. In the right eye, fundus examination revealed hard exudates and microaneurysms, mostly in the macular area; fluorescein angiography showed capillary leakage in the parafoveal area and also in areas beyond the arcades. The left eye also had some microaneurysms; in addition, cross sectional B-scan OCT revealed hyper-reflective dots with shadowing due to hard exudates, but less than in the right eye (Figure 1, Figure 2).

We also found hyperreflective, oval structures in the outer nuclear layer, adjacent to the outer plexiform layer, in both eyes (Figure 1, Figure 2). Cross-sectional flow signal overlaid OCT scans showed that these structures had highly prominent flow signals that were clearly different from projection artifact signals originating in the vasculature of inner retinal layers. En face OCTA revealed star-shaped flow signals in the avascular outer retinal slab; these pointed to the center of the image in both eyes. Signal patterns were identical to those associated with the accumulations seen in structural en face OCT.

In summary, SSPiM cause extravascular OCTA signals corresponding to hyperreflective fluid, and have an anatomic preference for the outer nuclear layer. The SSPiM signal is a novel, OCTA-revealed feature of retinal vascular diseases; we must take care to distinguish it from actual blood flow, from decorrelation signals originating in hyperreflective structures/materials, and from projection artifacts.

References

1. AH Kashani, et al., "Suspended Scattering Particles in Motion: A novel feature of OCT Angiography in Exudative Maculopathies", *Ophthalmology* 2, 694-702 (2018).

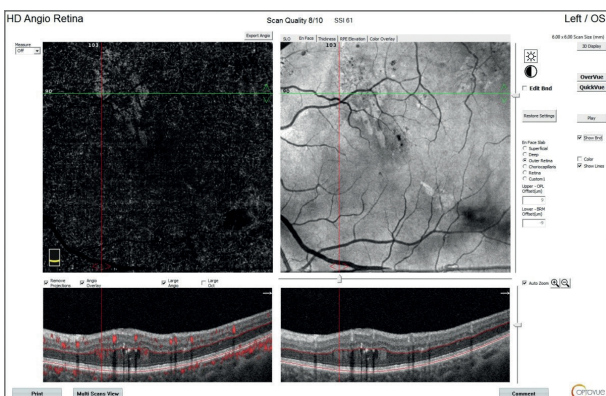


Figure 2: Multimodal imaging of left eye