



# AngioVue OCTA Case Series: Macular Telangiectasia Type 2

Imaging Early to Late Stages of MacTel 2 by OCTA



By Bruno Lumbroso (MD), Maria Cristina Savastano (MD), Marco Rispoli (MD), Centro Italiano Macula, Rome, Italy

Macular telangiectasia (MacTel) comprises a group of diseases typified by retinal capillary ectasia in the perifoveal area. Of the three main MacTel groups, Type 2 (MacTel 2) is the most common. Pathological findings associated with MacTel 2 include Müller cell lesions, retinal pigment epithelium (RPE) hyperplasia, pigment deposits, and hyporeflective angular cavities. Later stages may exhibit retinochoroidal anastomosis and networks of neovascularization.

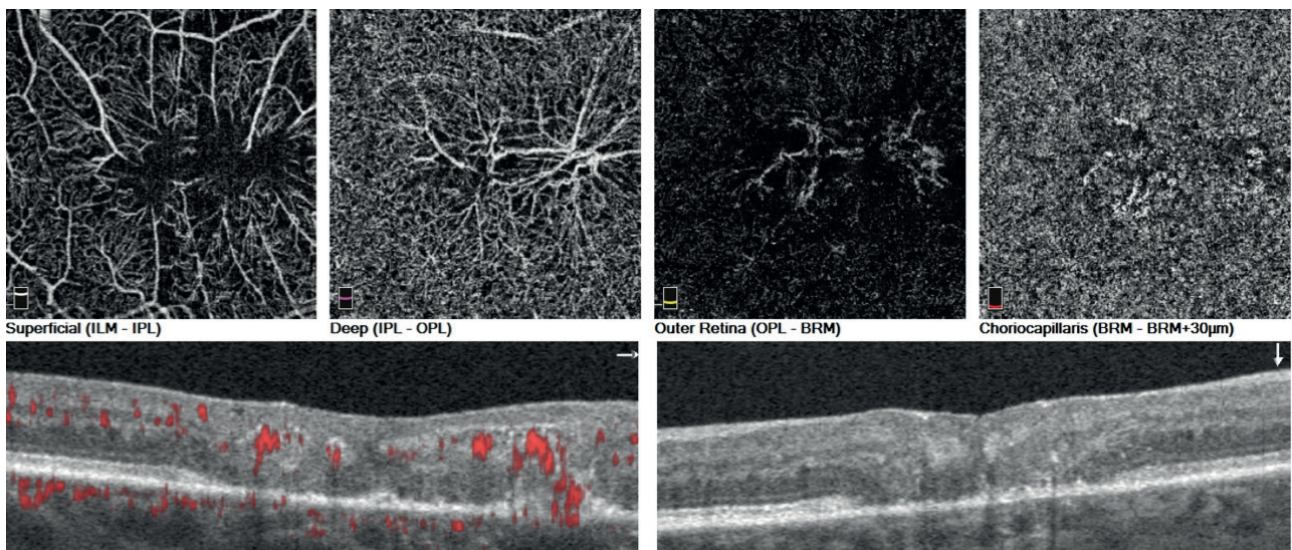


Figure 1: Early MacTel 2.



The pathogenetic mechanisms of MacTel 2 remain mysterious; despite years of study, we don't even know whether the syndrome is primarily vascular or neurosensory. It seems likely, however, that Müller cell dysfunction is significant in MacTel 2 etiology, since this cell type supports both neurons and retinal vasculature. Furthermore, the decreased macular pigment density at the posterior pole, typical of MacTel 2, is consistent with Müller cell dysfunction (1).

At present, no MacTel 2 lab test is available, and diagnosis therefore relies on fundoscopic exams and imaging. Relevant imaging techniques include fluorescein angiography, optical coherence tomography (OCT) and fundus autofluorescence. In this case study, we use spectral domain optical coherence tomography (SD-OCT) and OCT Angiography (OCTA) to image MacTel 2 in two patients exhibiting, respectively, early and late stages of the disease.

Patient 1 presented with blurred vision and some vision loss in each eye; fundus examination showed macular mottling and foveal scar tissue. Angiovue en face images of the right eye (Figure 1, top) showed typical vascular distortions in the superficial and deep capillary complexes; the outer retina slab revealed a star-shaped flow heading toward the RPE. Cross-sectional angiography scans (Figure 1, bottom) enhanced visualization of this pathological flow,

showing that it started at the outer plexiform layer (OPL) and continued to a small breach in the RPE located immediately beneath the origin of the flow. At this position, the imaging technology also revealed a clear "kissing" sign, indicative of a retinochoroidal anastomosis (a precursor to neovascularization). SD-OCT imaging gave similar results in the left eye.

In Patient 2, by contrast, OCTA clearly showed a fully developed neovascular membrane network (Figure 2, top), typical of advanced MacTel 2. We observed an irregular pigment epithelium detachment from which neovascular growths sprout towards the OPL; this feature was confirmed by cross-sectional angiography scans (Figure 2, bottom) which reveal pathological flow in the same area.

In conclusion, our imaging system allowed us to compare patients with early and late-stage disease. We confirmed that chorioretinal anastomosis appears to be a late complication of MacTel 2, and showed that OCT B-scans and OCTA highlight this pathology very effectively. The progression of MacTel 2 to neovascularization is likely to complicate the treatment of advanced cases, and suggests that anti-VEGF treatment may be useful in patient management.

#### References

1. PC Issa, et al., "Macular telangiectasia Type 2", *Prog Retin Eye Res.* 34: 49-77 (2013). PMID: 23219692.

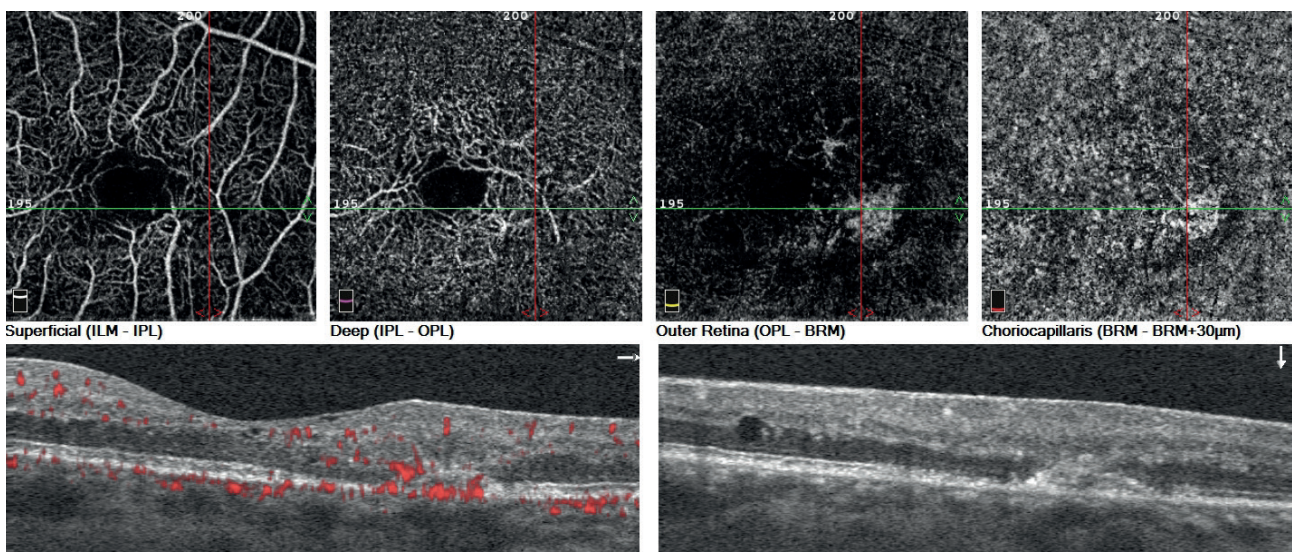


Figure 2: Advanced MacTel 2.