

Liquefaction in the Prevention of Posterior Capsule Opacification – Safety and Efficacy

Nada Jiraskova*, Marie Kalfertova, Marya Burova, Jana Nekolova, and Pavel Rozsival

Department of Ophthalmology, University Hospital, Hradec Králové, Czech Republic

Abstract

Purpose: To evaluate the extent of posterior capsule opacification (PCO) following cataract surgery-torsional phacoemulsification with liquefaction method removal of the epithelial cells (right eye), and straight forward torsional phacoemulsification (left eye), with subsequent implantation of the AcrySof SA60AT intraocular lens.

Methods: In this prospective clinical trial patients with bilateral cataract were observed. The Evaluation of Posterior Capsule Opacification (EPCO) 2000 software and the Open-Access Systematic Capsule Assessment (OSCA) system were used for PCO assessment at 3, 6, 12 and 24 months after surgery. Postoperative changes in endothelial cell count (ECC) and pachymetry were also evaluated.

Results: The mean value for total EPCO index at 3, 6, 12 and 24 months postoperatively was respectively for the right eye 0.289 ± 0.223 , 0.276 ± 0.176 , 0.309 ± 0.185 and 0.418 ± 0.253 , and for the left eye 0.302 ± 0.191 , 0.301 ± 0.168 , 0.355 ± 0.206 and 0.468 ± 0.309 . The mean value for OSCA score (New Analysis) was for the right eye 0.612 ± 0.279 , 0.603 ± 0.339 , 0.559 ± 0.265 and 0.642 ± 0.401 , and for the left eye 0.630 ± 0.398 , 0.629 ± 0.366 , 0.535 ± 0.331 and 0.574 ± 0.340 . One patient underwent Nd-YAG laser capsulotomy one year after surgery (both eyes), and one patient two years postoperatively (right eye). There was minimal reduction in endothelial cell count and minimal changes in corneal thickness in both eyes.

Conclusions: The AquaLase method is safe for ocular tissue. Two years after surgery, most cases of PCO were graded as minimal by both systems of analysis. Notwithstanding the slightly better results in eyes with AquaLase polishing of the posterior capsule, this technique was not able to completely prevent a natural progression of PCO.

Keywords: Cataract surgery; Posterior capsule opacification; OSCA; EPCO

Introduction

As a very frequent late postoperative complication of cataract extracapsular extraction, posterior capsule opacification (PCO) is one of the main concerns of ophthalmologists worldwide for its medical, social, and economic implications. Recent trials have found that the effect of intraocular lens (IOL) material and design, surgical techniques, and pharmaceutical interventions are all contributing to the incidence and degree of PCO [1,2]. Modern techniques of cataract surgery have led to a decrease in the neodymium-yttrium-aluminum-garnet (Nd:YAG) laser treatment rate for PCO. However, there is still no extended procedure for complete PCO eradication. Since the PCO usually develops over years and leads to a slow decrease in vision, progression over time is the important factor in PCO evaluation [3].

AquaLase was originally introduced as a crystalline lens removal technology using the method of liquefaction of the lens material by pulses of warmed (57°C) balanced salt solution (BSS) produced just inside the aspiration port of the tip [4]. This technique was introduced by Alcon in late 2000, and together with an advanced ultrasound, NeoSoniX and OZil, is an option provided by INFINITI Vision System (Alcon Laboratories, Fort Worth, Texas, USA). Because the AquaLase tip is made of smooth material rounded-bevel polymer rather than metal, the risk for posterior capsule rupture is reduced, making this method more capsule friendly [5]. Several studies have shown that the technology may have applications in polishing the capsule through mechanical washing of lens epithelial cells (LECs) from the capsule bag with the fluid pulses [6,7]. The reduction of LECs has been shown to be preventive for PCO occurrence and progression. The aim of our research was to assess whether use of liquefaction technology for

polishing of the posterior capsule may serve as a prevention of PCO formation.

Methods

All operations were performed at the Department of Ophthalmology, University Hospital Hradec Kralove in the Czech Republic. The study was conducted in conformance with international ethical requirements, and all patients gave informed consent.

Fifty-six patients (17 men and 39 women) eligible for this prospective study were selected randomly from the department queue. The inclusion criteria were bilateral cataract and no other severe ocular pathologic features potentially affecting visual acuity (patients with mild age-related macular degeneration [AMD] were not excluded). Before surgery, a complete eye examination was performed. Best corrected visual acuity (BCVA) was measured using Snellen optotypes, together with endothelial cell count and pachymetry using specular microscope CONAN NONCON ROBO Pachy SP-9000. All operations were completed by one of the two skilled surgeons (N.J., P.R.), and both eyes of each patient were operated on by the same surgeon within 1 week. The operations were carried out under topical anesthesia:

*Corresponding author: Nada Jirásková, MD, PhD, Professor, Department of Ophthalmology, University Hospital, 500 05 Hradec Králové, Czech Republic, Tel: 420 495 833 392; E-mail: jirasnad@fnhk.cz

Received November 26, 2012; Accepted January 07, 2013; Published January 14, 2013

Citation: Jiraskova N, Kalfertova M, Burova M, Nekolova J, Rozsival P (2013) Liquefaction in the Prevention of Posterior Capsule Opacification–Safety and Efficacy. J Clin Exp Ophthalmol 4:262. doi:10.4172/2155-9570.1000262

Copyright: © 2013 Jiraskova N, et al. This is an open-access article distributed under the terms of the Creative Commons Attribution License, which permits unrestricted use, distribution, and reproduction in any medium, provided the original author and source are credited.

torsional phaco (OZil) was used for removal of the lens nucleus, and bimanual irrigation/aspiration (I/A) for cortex removal. The capsular bag of the right eye was polished using the liquefaction method (the standard AquaLase soft polymer needle flared at the tip with a 1.1-mm inner diameter and a 1.32 mm outer diameter). The AquaLase settings were: linear magnitude 40%, 50 pulses per second (pps), burst mode 100%, vacuum 14 mm Hg, and dynamic rise 2. The surgeons were both of equal standing and the same IOL (Alcon AcrySof SA60AT) was implanted in the bag through a Monarch II injector system (Alcon Laboratories) in all eyes.

All participants were asked to undergo a follow-up examination at 3, 6, 12 and 24 months (M) after surgery. Two patients were lost to follow-up, 2 patients underwent only the first postoperative visit 3 M after surgery, and 2 patients were examined only 3 and 6 M after surgery. After attaining maximal pupil dilatation, digital retroillumination photographs of the anterior segment were obtained using the slit-lamp equipped with Digital Vision System (composed of a digital camera with a Sony CCD sensor and the Epsilon Lyrae software (Florence, Italy)). Exact focusing on the IOL and posterior capsule was carried out. Patients with preceding Nd:YAG laser capsulotomy were excluded from the computer PCO assessment, and the remaining images were computer analyzed. They were imported into the EPCO 2000 program and the PCO was evaluated for the entire optic. The opacification density was graded as minimal (grade 1) when the capsule showed mild wrinkling, mild homogeneous layers, or sheets of lens epithelial cells. Areas of honeycomb patterns of PCO, thicker homogeneous layers, and denser fibrosis were graded as mild (grade 2), and areas of classical Elschnig pearls and of very thick homogeneous layers were graded as moderate (grade 3). Areas of very thick Elschnig pearls with “darkening effect” or of any type of severe opacification were graded as severe (grade 4). The boundaries of the IOL and each opaque area of the posterior capsule were drawn on the images using the computer mouse. After all areas of interest were color coded, the PCO indexes were calculated and then analyzed statistically [8]. The images were then analyzed with the OSCA system. It is possible to use 3 different methods of analysis: 1) the Single Analysis, for analyzing the only image of the patient’s capsule with flash not covering the PCO; 2) the New Analysis, requiring 2 images containing spoiled flash areas in different regions; and 3) the Circ Analysis, which allows the specification of the central number of pixels to be measured [9,10]. In this study the Single Analysis was used when the flash did not cover PCO and the New Analysis when the flash had to be removed without losing potential PCO areas under the flash. In the New Analysis the second image was registered, that is, it was realigned for deviations caused by different angles of photography. Then, by clicking down the remaining buttons, the processes of equalization and segmentation, removing backgrounds, swapping bright areas, and fading bits were carried out. The PCO score was calculated automatically. The possible OSCA scores range from zero (no PCO) to approximately 15 (practical expected maximum). The typical OSCA value for images with very little or no PCO is approximately 0.5. Values for patients who are deemed to warrant laser capsulotomy typically are approximately four to five.

The incidence of Nd-YAG laser capsulotomy was evaluated. Nd-YAG capsulotomy was performed based on subjective patient disappointment regarding the quality of his or her vision and measurable decrease in BCVA compared to best postoperative VA (loss of more than 1 line in Snellen BCVA), coupled with the presence of PCO in the central part of the posterior capsule. Measurement of the degree of capsule opacification was not determinant decisive.

Statistical analysis was performed using MS Excel and the statistical program SYSTAT, version 0.8. Where the collected data were not normally distributed, nonparametric methods were used. For testing BCVA, ECC and pachymetry values, Wilcoxon signed-rank test was used. Kruskal-Wallis test and/or Mann-Whitney test were used for testing of independent sets of data with the same distribution. Simple linear correlation analysis (Pearson) was performed for the assessment of the relation of EPCO 2000 indexes and OSCA scores and OSCA Single Analysis and OSCA New Analysis. All decisions were made at significance level (α) of .05.

Results

In this limited series no intraoperative complications were observed, such as rupture of the posterior capsule during AquaLase cleaning. The mean value of AquaLase time was 0.314 ± 0.190 second (s). The number of pulses varied from 80 to 1860, with median of 1105.

Fifty-six patients eligible for the study were originally included. Of these, fifty-four completed the 3-month (3 M) follow-up examination, 53 of them attended the 6-month (6 M) follow-up, 50 of them the 12-month (12 M) follow-up, and 49 of them completed the full 2-years (24 M) of follow-ups. The Nd:YAG laser capsulotomy rate for the right (AquaLase) eye vs. the left eye was 1:1 after 1 year postoperatively, and 2:1 after 2 years. Thus the PCO of 49 patients was computer analyzed 1 year after surgery, and the PCO of 48 patients was computer analyzed after 2-year follow-up.

The preoperative mean value of BCVA of the right eye (RE) was 0.52 and of the left eye (LE) 0.483. Postoperatively the mean BCVA was 0.956 (RE) and 0.967 (LE) 3M after surgery; 0.940 (RE), and 0.960 (LE) 6 M after surgery; 0.912 (RE), and 0.922 (LE) 12M after surgery; and 0.892 (RE) and 0.890 (LE) 24M after surgery. There was a statistically significant improvement in BCVA of both eyes after surgery (P values were 0 for both eyes). No statistically significant difference between the RE and the LE was found using Mann-Whitney test (P values at 3 M, 6 M, 12 M and 24 M after surgery were 0.450, 0.979, 0.606 and 0.738 respectively).

The preoperative mean value of ECC was 2579.48 cells/mm² (RE) and 2555.82 cell/mm² (LE). Postoperative mean values of ECC (cells/mm²) of the RE at 3 M, 6 M, 12 M and 24 M were 2361.87, 2421.81, 2346.94, and 2256.15, respectively. Mean values of ECC (cells/mm²) of the LE at 3 M, 6 M, 12 M and 24 M after surgery were 2419.89, 2436.47, 2256.55, and 2289.63, respectively (Figure 1). There was a statistically significant difference between preoperative and postoperative values of ECC for both eyes (P value for the RE was 0; P value for the LE was 0.001). No statistically significant difference between the RE and the LE was found using Mann-Whitney test.

The preoperative mean value of pachymetry was 567.143 μ m (RE) and 562.268 μ m (LE). Postoperative mean values of pachymetry of the RE at 3 M, 6 M, 12 M and 24 M were 557.296 μ m, 552.566 μ m, 560.143 μ m, and 554.750 μ m, respectively. Mean values of pachymetry of the LE at 3 M, 6 M, 12 M and 24 M after surgery were 559.093 μ m, 567.547 μ m, 560.265 μ m, 556.542 μ m, respectively. No statistically significant difference between pre- and postoperative mean values was found using Wilcoxon test, and also no statistically significant difference between the RE and the LE was proved using Mann-Whitney test.

Two years after the surgery the capsule of most eyes showed mild wrinkling and mild homogeneous layers or sheets of LECs. Minimal opacification of the capsule with areas of honeycomb patterns of

PCO (EPCO grade 1) were found in almost all eyes, whereas areas of very thick Elschnig pearls with darkening effect or any type of severe opacification (EPCO grade 4) were not found in the group with liquefaction cleaning (right eyes) and in only one left eye. The mean EPCO indexes for the entire optic with standard deviation, median, and minimal and maximal values for the AquaLase group (right eyes), and for the eyes without AquaLase (left eyes) are shown in table 1. Comparison of total EPCO indexes between both eyes is shown in figure 2.

All eyes were also analyzed using OSCA Single Analysis and OSCA New Analysis. The mean OSCA scores with standard deviation, median, and minimal and maximal values for both eyes are shown in tables 2 and 3. The values are tabulated for each of the 3 M, 6 M, 12 M, and 24 M follow-up assessments. Comparison of OSCA Single Analysis scores between eyes is shown in figure 3, and comparison of OSCA New Analysis scores in figure 4. The results were statistically analyzed using non-parametric Mann-Whitney test and no statistically significant difference between the right and left eyes was found at each visit using both Single Analysis and New Analysis (P values for OSCA Single analysis were 0.766, 0.779, 0.4 and 0.486 at 3 M, 6 M, 12 M, and

		3M		6M		12M		24M	
		RE	LE	RE	LE	RE	LE	RE	LE
Total EPCO index	Min	0.010	0.017	0.014	0.019	0.026	0.063	0.014	0.019
	Max	1.003	0.907	0.801	0.679	0.780	0.829	1.190	1.740
	Med	0.258	0.260	0.214	0.261	0.273	0.340	0.406	0.401
	Mean	0.289	0.302	0.276	0.301	0.309	0.355	0.418	0.468
	MD	0.223	0.191	0.176	0.168	0.185	0.206	0.253	0.309

M: Months; Min: Minimum; Max: Maximum; Med: Median; MD: Mean Deviation; LE: Left Eye; RE: Right Eye

Table 1: The mean EPCO indexes for the entire optic with standard deviation, median, and minimal and maximal values for the right and left eyes.

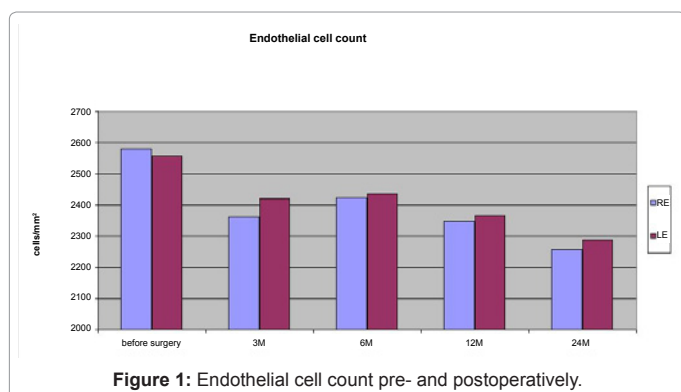


Figure 1: Endothelial cell count pre- and postoperatively.

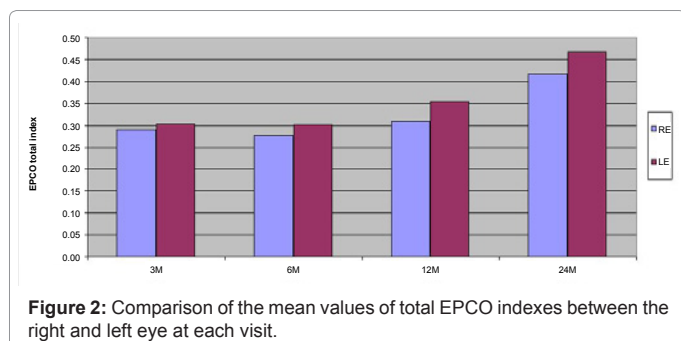


Figure 2: Comparison of the mean values of total EPCO indexes between the right and left eye at each visit.

		3M		6M		12M		24M	
		RE	LE	RE	LE	RE	LE	RE	LE
OSCA Single analysis scores	Min	0.352	0.333	0.218	0.307	0.271	0.322	0.217	0.203
	Max	2.447	3.503	2.581	3.100	2.227	2.374	3.375	2.545
	Med	0.964	0.889	0.908	0.873	0.896	0.813	0.893	0.883
	Mean	1.014	1.049	0.976	1.025	0.922	0.901	1.066	0.976
	MD	0.412	0.604	0.487	0.551	0.389	0.441	0.615	0.534

M: Months; Min: Minimum; Max: Maximum; Med: Median; MD: Mean Deviation; LE: Left Eye; RE: Right Eye

Table 2: The mean OSCA scores (Single Analysis) with standard deviation, median, and minimal and maximal values for the right and left eyes.

		3M		6M		12M		24M	
		RE	LE	RE	LE	RE	LE	RE	LE
OSCA New analysis scores	Min	0.142	0.152	0.092	0.140	0.154	0.126	0.103	0.116
	Max	1.597	1.930	1.759	2.020	1.434	1.747	2.170	1.735
	Med	0.600	0.504	0.558	0.588	0.565	0.450	0.510	0.538
	Mean	0.612	0.630	0.603	0.629	0.559	0.535	0.642	0.574
	MD	0.279	0.398	0.339	0.336	0.265	0.331	0.401	0.340

M: Months; Min: Minimum; Max: Maximum; Med: Median; MD: Mean Deviation; LE: Left Eye; RE: Right Eye

Table 3: The mean OSCA scores (New Analysis) with standard deviation, median, and minimal and maximal values for the right and left eyes.

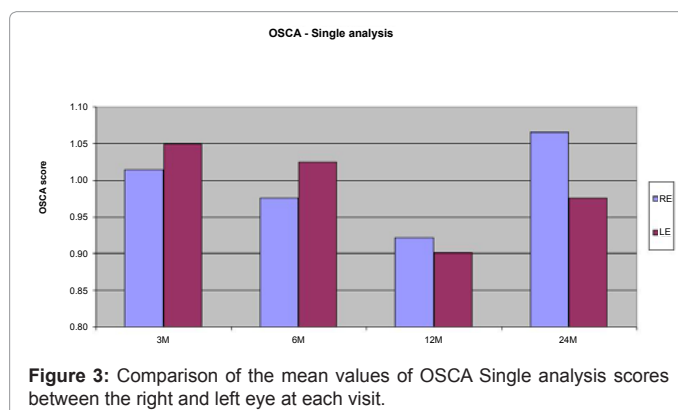


Figure 3: Comparison of the mean values of OSCA Single analysis scores between the right and left eye at each visit.

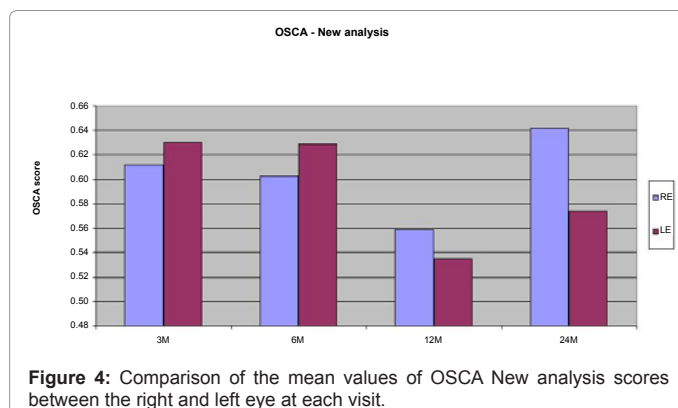


Figure 4: Comparison of the mean values of OSCA New analysis scores between the right and left eye at each visit.

24 M after surgery, respectively. P values for OSCA New Analysis were 0.632, 0.783, 0.269 and 0.420 at 3 M, 6 M, 12 M, and 24 M after surgery, respectively).

There was statistically significant correlation between OSCA Single Analysis and OSCA New Analysis at each follow-up after cataract surgery (P values were 0 for results from each postoperative visit and

	3M	6M	12M	24M
OSCA New : EPCO 2000	0.259	0.313	0.299	0.482
OSCA Single : EPCO 2000	0.350	0.418	0.392	0.589

M: Months

Table 4: Correlation between EPCO 2000 and OSCA (Pearson correlation coefficients at each follow-up visit).

correlation coefficients were 0.965, 0.960, 0.959 and 0.955 at 3 M, 6 M, 12 M, and 24 M after surgery, respectively).

Correlation between EPCO 2000 indexes and OSCA Single Analysis and OSCA New Analysis scores was assessed using Pearson linear correlation coefficient test. Statistically significant correlation was proved at each follow-up visit. P values were 0 for each testing and Pearson correlation coefficients are summarized in table 4.

Discussion

Although phacoemulsification technology, surgical techniques and the IOL quality all have an important effect on the incidence and degree of PCO [11,12], there is still no proved procedure for its complete eradication. It was repeatedly proved that the AcrySof acrylic IOL with square posterior optic has a PCO-inhibiting effect [1,13]. To minimize the influence of the IOL on PCO development, all patients in this study received the same IOL, namely the Alcon AcrySof SA60AT.

Surgical technique is another factor influencing PCO formation. Crucial factors include precise continuous curvilinear capsulorrhexis, cortical cleaning, posterior capsule polishing, and lens placement in the bag. In our study, all surgeries were performed by one of two surgeons. We are aware that this may represent a source of variability in subsequent PCO formation; however, no significant difference in PCO extent was proven between the two surgeons. Hence, the statistical analyses were carried out without consideration of possible variation in surgical skill.

AquaLase is a handpiece option provided by INFINITI Vision System (Alcon Laboratories). This liquefaction device uses fundamentally different technology for emulsification and removal of lenticular material. Several studies have shown that the technology is more capsule friendly and may have applications in polishing the capsule through mechanical washing of epithelial cells from the bag with the fluid pulses [6,7,14,15]. In our study the AquaLase was not primarily used for liquefaction of the cataract, but only for polishing of the capsule bag. The AquaLase settings were chosen to be completely safe for the posterior capsule, and no perioperative complications such as capsule rupture or zonular loss were observed.

No standardized, widespread, fully objective system of analysis of PCO has yet been proven as a gold standard. The ideal system should be objective and it should give quantifiable values for PCO. It should be sensitive and specific enough and have high reproducibility and validity. It should eliminate subjective errors in assessment and it should be able to avoid registering artifacts such as lens edge, capsulorrhexis edge, flash reflections, poorly illuminated areas of capsule, and corneal, vitreous, or fundus opacities [9,16]. The EPCO 2000 is one of the most frequently used methods of PCO assessment. It has good intra-individual and inter-individual reliability, and it is easy to use. It is not patient dependent and provides valid and reproducible results. The OSCA is a system of objective PCO assessment, which is based on location-sensitive entropy-based texture analysis of digital images. This system is of good validity and excellent reliability and there is also very good correlation of PCO scores with vision. Both systems of PCO

analysis measure morphologic severity of PCO (extent and density). As regards the OSCA software, it provides in addition positive weighting toward the central visual axis.

PCO-induced decrease of vision can be treated by opening the posterior capsule by Nd-YAG capsulotomy [17]. The incidence of Nd:YAG laser capsulotomy is an indirect and less than ideal measure of PCO, and it has questionable validity. It may be influenced by subjective patient symptoms, surgeons' preferences and opinions, and even by economic considerations. Although the dependence on Nd:YAG capsulotomy as a measure of PCO may be an inaccurate estimate of the degree of opacification [18], it is important to show the capsulotomy rate with the results of PCO measured with PCO-quantifying software. Eyes that have required capsulotomy can no longer be computer assessed, and these dropouts can considerably bias study results. A study of the difficult statistical problems caused by missing data attributable to Nd:YAG capsulotomies in long term PCO trials has been published [19]. When a study includes many capsulotomies (often predominantly in one of the groups), the results of complete case analyses may be considerably biased. In our study, only 2 patients required Nd:YAG capsulotomy over the whole follow-up period. The difference in the laser treatment of PCO was not significant between the right and left eyes, so no direct comparison of software outcomes was made. The capsulotomy dropouts were taken into account when making study conclusions.

There was no proven significant difference between the groups in EPCO indexes and OSCA scores during 24 month follow-up. The mean total EPCO indexes and OSCA scores were slightly better in the right eye (AquaLase cleaning).

In summary, notwithstanding the slightly better results in eyes with AquaLase polishing of the posterior capsule, this technique was not able to completely prevent a natural progression of PCO.

Acknowledgement

Presented in part at the ESCRS Annual Meeting, September 2011, Vienna, Austria; ASCRS Annual Meeting, March 2011, San Diego, California, USA, and Congress-European Association for Vision and Eye Research (EVER), October 2011, Hersonissos, Crete, Greece. This study was supported in part by grant No. 103809 from Charles University Grant Agency. The authors would like to thank Josef Kvasnicka, MSc., for providing statistical analysis.

None of the authors has a financial or proprietary interest in any product mentioned.

References

1. Sacu S, Findl O, Menapace R, Buehl W (2005) Influence of optic edge design, optic material, and haptic design on capsular bend configuration. *J Cataract Refract Surg* 31: 1888-1894.
2. Hancox J, Spalton D, Heatley C, Jayaram H, Yip J, et al. (2007) Fellow-eye comparison of posterior capsule opacification rates after implantation of 1CU accommodating and AcrySof MA30 monofocal intraocular lenses. *J Cataract Refract Surg* 33: 413-417.
3. Pozlerová J, Nekolová J, Jirásková N, Kadlecová J, Rozsival P (2007) Comparison of posterior capsule opacification in 2 types of implanted artificial intraocular lens. *Cesk Slov Oftalmol* 63: 42-46.
4. Mackool RJ, Brint SF (2004) AquaLase: a new technology for cataract extraction. *Curr Opin Ophthalmol* 15: 40-43.
5. Tsai JH, Khng CG, Osher RH, Sussman GR (2007) Development of an in vitro model to assess posterior capsule safety during phacoemulsification with ultrasound or AquaLase handpieces. *J Cataract Refract Surg* 33: 1076-1081.
6. Nekolová J, Pozlerová J, Jirásková N, Rozsival P, Kadlecová J (2008) Comparison of posterior capsule opacification after two different surgical methods of cataract extraction. *Am J Ophthalmol* 145: 493-498.

7. Nekolová J, Jirásková N, Pozlerová J, Rozsival P (2009) Three-year follow-up of posterior capsule opacification after AquaLase and NeoSoniX phacoemulsification. *Am J Ophthalmol* 148: 390-395.
8. Tetz MR, Auffarth GU, Sperker M, Blum M, Völcker HE (1997) Photographic image analysis system of posterior capsule opacification. *J Cataract Refract Surg* 23: 1515-1520.
9. Aslam TM, Dhillon B, Werghi N, Taguri A, Wadood A (2002) Systems of analysis of posterior capsule opacification. *Br J Ophthalmol* 86: 1181-1186.
10. Aslam TM, Patton N, Rose CJ (2006) OSCA: a comprehensive open-access system of analysis of posterior capsular opacification. *BMC Ophthalmol* 6: 30.
11. Pandey SK, Apple DJ, Werner L, Maloof AJ, Milverton EJ (2004) Posterior capsule opacification: a review of the aetiopathogenesis, experimental and clinical studies and factors for prevention. *Indian J Ophthalmol* 52: 99-112.
12. Jirásková N, Rozsival P (2004) Methods of evaluating posterior capsular opacification after cataract surgery. *Cesk Slov Oftalmol* 60: 155-157.
13. Linnola RJ (1997) Sandwich theory: bioactivity-based explanation for posterior capsule opacification. *J Cataract Refract Surg* 23: 1539-1542.
14. Hoffman RS, Fine IH, Packer M (2005) New phacoemulsification technology. *Curr Opin Ophthalmol* 16: 38-43.
15. Jirásková N, Kadlecová J, Rozsival P, Nekolová J, Pozlerova J, et al. (2008) Comparison of the effect of AquaLase and NeoSoniX phacoemulsification on the corneal endothelium. *J Cataract Refract Surg* 34: 377-382.
16. Findl O, Buehl W, Menapace R, Georgopoulos M, Rainer G, et al. (2003) Comparison of 4 methods for quantifying posterior capsule opacification. *J Cataract Refract Surg* 29: 106-111.
17. Buehl W, Sacu S, Findl O (2005) Association between intensity of posterior capsule opacification and contrast sensitivity. *Am J Ophthalmol* 140: 927-930.
18. Mian SI, Fahim K, Marcovitch A, Gada H, Musch DC, et al. (2005) Nd:YAG capsulotomy rates after use of the AcrySof acrylic three piece and one piece intraocular lenses. *Br J Ophthalmol* 89: 1453-1457.
19. Buehl W, Heinzl H, Mittlboeck M, Findl O (2008) Statistical problems caused by missing data resulting from neodymium:YAG laser capsulotomies in long-term posterior capsule opacification studies: problem identification and possible solutions. *J Cataract Refract Surg* 34: 268-273.

Citation: Jiraskova N, Kalfertova M, Burova M, Nekolova J, Rozsival P (2013) Liquefaction in the Prevention of Posterior Capsule Opacification–Safety and Efficacy. *J Clin Exp Ophthalmol* 4:262. doi:[10.4172/2155-9570.1000262](https://doi.org/10.4172/2155-9570.1000262)

Submit your next manuscript and get advantages of OMICS Group submissions

Unique features:

- User friendly/feasible website-translation of your paper to 50 world's leading languages
- Audio Version of published paper
- Digital articles to share and explore

Special features:

- 250 Open Access Journals
- 20,000 editorial team
- 21 days rapid review process
- Quality and quick editorial, review and publication processing
- Indexing at PubMed (partial), Scopus, DOAJ, EBSCO, Index Copernicus and Google Scholar etc
- Sharing Option: Social Networking Enabled
- Authors, Reviewers and Editors rewarded with online Scientific Credits
- Better discount for your subsequent articles

Submit your manuscript at: www.editorialmanager.com/clinicalgroup

