

REVISED CLASSIFICATION OF THE OPTICAL COHERENCE TOMOGRAPHY OUTER RETINAL BANDS BASED ON CENTRAL SEROUS CHORIORETINOPATHY ANALYSIS

STEVEN M. BLOOM, MD, INDER P. SINGAL, MD

Purpose: To evaluate the optical coherence tomography (OCT) imaging findings in recent onset neurosensory retinal detachments induced by central serous chorioretinopathy and to attempt to corroborate these findings with proposed anatomical correlates.

Methods: Retinal detachments due to central serous chorioretinopathy of less than 3 months' duration and the surrounding area were scanned with OCT. The imaging of the outer retinal bands was evaluated according to proposals by Cuenca et al and the IN • OCT Consensus classification.

Results: Optical coherence tomography findings in 11 eyes (11 patients) with CSC showed that all hyperreflective bands above Band 4 were variably continuous within the outer portion of the serous detachment. We then attempted to reconcile inconsistencies in current explanations for the outer retinal bands to propose changes to the outer retinal OCT nomenclature.

Conclusion: Our patients' OCT findings support the current standard that Band 3 is an outer retinal structure and that Band 4 represents the retinal pigment epithelium/Bruch complex. Confusion exists regarding whether the interdigitation zone extends halfway up or for the full length of the outer segments, and the hyporeflexive band between Bands 3 and 4 has yet to receive an appropriate term. We therefore propose a modification to the IN • OCT Consensus classification by renaming the trilaminar hyporeflexive, hyperreflective, and hyporeflexive bands between Bands 2 and 4 as the outer segment–interdigitation zone complex consisting of the inner, middle, and outer segment–interdigitation zone, respectively.

RETINA 41:181–188, 2021

There is fairly firm agreement regarding what cellular structures correlate with the optical coherence tomography (OCT) findings from the vitreoretinal interface down to the external limiting membrane (ELM). Spectral domain OCT visualizes four hyperreflective outer retinal bands. The innermost band is universally accepted as the ELM and the hyporeflexive myoid zone lies just external to this. The second hyperreflective band, which is much brighter than the ELM, was initially and erroneously believed to represent the inner segment–outer segment junction.¹ In 2011, Spaide and Curcio,² by lining up detailed histologic scale model drawings with outer retinal OCTs, offered compelling evidence that the second band represents mitochondria in the ellipsoid zone (EZ). Subsequent

researchers have also identified mitochondria as the likely EZ substructure responsible for Band 2.³ Spaide and Curcio identified the third bright band as the contact cylinder (interdigitation zone) between the photoreceptor outer segment tips and the microvilli of the retinal pigment epithelium (RPE). They finally identified the fourth bright band as the RPE. This led to the 2014 IN • OCT Consensus classification that provided an initial common terminology for these layers (Figure 1A).⁴ The origin of Band 2 was questioned by Jonnal et al,⁵ but their findings were promptly rebutted by Spaide.⁶ However, confusion in the literature still remains, with many communications still using the inner segment–outer segment junction terminology.

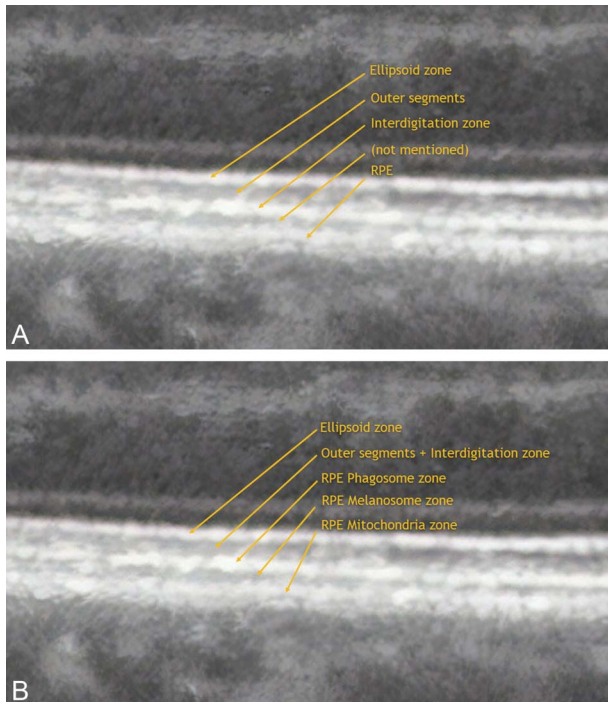


Fig. 1. A. Outer retinal bands as described by IN • OCT Consensus.⁴ B. Outer retinal bands as described by Cuenca et al⁷'s study.

In 2018, Cuenca et al⁷ also challenged these findings using morphologic immunohistochemistry to identify the various retinal cellular substructures. Although their findings were consistent with the first and second outer hyperreflective bands representing the ELM and EZ, respectively, they offered an alternative explanation for Bands 3 and 4 (Figure 1B). Unlike Spaide and Curcio's description that the contact cylinder corresponded to "the RPE apical processes and the external portion of the cone" outer segments, Cuenca et al felt that the RPE microvilli envelop the entire cone outer segments up to the EZ. They, therefore combined the outer segments and interdigitation zone, felt to be responsible for Spaide and Curcio's hyperreflective Band 3, into the single hyporefective band between Bands 2 and 3. They then suggested that the RPE appears as not one, but three

From the Bennett & Bloom Eye Centers, Louisville, Kentucky.

None of the authors has any financial/conflicting interests to disclose.

Supplemental digital content is available for this article. Direct URL citations appear in the printed text and are provided in the HTML and PDF versions of this article on the journal's Web site (www.retinajournal.com).

This is an open-access article distributed under the terms of the Creative Commons Attribution-Non Commercial-No Derivatives License 4.0 (CCBY-NC-ND), where it is permissible to download and share the work provided it is properly cited. The work cannot be changed in any way or used commercially without permission from the journal.

Reprint requests: Steven M. Bloom, MD, Bennett & Bloom Eye Centers, Whitehouse Office Complex, 1935 Bluegrass Avenue, Suite 200, Louisville, KY 40207; e-mail: smbloo01@gmail.com

bands: Band 3 (phagosome zone), a hyporefective band (melanosome zone), and Band 4 (mitochondria zone). Curcio et al⁸ later rejected Cuenca et al's conclusions for numerous reasons, including an incorrect interpretation of RPE melanosome reflectivity.

Nature has given us a fascinating and complex disorder, central serous chorioretinopathy (CSC) where we can trace the various retinal layers from attached into detached retina. In this report, we analyzed the OCT findings according to both Cuenca et al's and the IN • OCT Consensus classifications in 11 eyes with CSC. We found that neither classification fully explained our findings. We therefore propose modifying the IN • OCT Consensus classification to reconcile these discrepancies.

Methods

We retrospectively gathered OCT scans from 11 representative eyes (11 patients) with serous retinal detachment from central serous chorioretinopathy of less than 3 months' duration. For cases 1, 2, 3, 4, 7, and 10, we retrospectively, noninclusively reviewed our practice's retinal image teaching collection for cases filed as CSC. Cases 5, 6, 8, 9, and 11 were donated by Dr. Richard Spaide with similar selection criteria.

Scans were performed using either the Cirrus spectral domain (Carl Zeiss Meditech, Dublin, CA), the Heidelberg Spectralis (Heidelberg Engineering, Heidelberg, Germany), or the Triton Plus swept-source (Topcon Medical Systems, Incorporated, Oakland, NJ) OCT units. Axial resolutions were 5 μm , 2.6 μm , and 3.5 μm for the Cirrus, Triton Plus, and Heidelberg units, respectively. Images were selected for relevant anatomic detail using either enhanced-depth imaging B scans (Cases 1, 3, 4, 7, 10, and 11) or by scrolling through volume scans (Cases 2, 5, 6, 8, and 9).

Imaging of the outer retinal bands in both attached and detached retina was evaluated according to proposals by Cuenca et al and the IN • OCT Consensus classification. For our evaluation, we assumed Band 1 to be the ELM, the hyporefective band below the ELM to be the myoid, and Band 2 to be the EZ. The hyporefective band between Bands 2 and 3 was termed 2-3 HYPO, and the hyporefective band between Bands 3 and 4 was termed 3-4 HYPO. The color-labeling convention used for our hyperreflective outer retinal band analysis is given in Figure 2.

Case Reports

Table 1 summarizes the major OCT findings for each case.



Fig. 2. Magnified view (of Supplemental Digital Content 2) of the transition zone from attached to detached retina. Band 1 (blue line, ELM), myoid, Band 2 (red line), 2-3 HYPO, Band 3 (yellow line), and 3-4 HYPO in attached retina initially merge into a single thickened line within the detachment. Only Band 4 (green line) continues into the detachment unchanged.

Case 1

Figure 3 shows that Band 1 (ELM) and the underlying hyporeflective myoid zone are seen in both attached and detached retina, whereas Band 2 (EZ) is seen only in attached retina. A hyporeflective band separates Bands 2 and 3 (2-3 HYPO). In attached retina, Band 3 appears as a thin hyperreflective line. Where the retina begins to separate nasally, Bands 2, 2-3 HYPO, and 3 initially merge into a single band within the area of detachment. They then separate into distinct Bands 2, 2-3 HYPO, and 3 and finally merge on the descending temporal side of the detachment. A faint thin hyporeflective band, between Bands 3 and 4, is seen within attached retina (3-4 HYPO) (INSET). This band also disappears within the area of detachment. Band 4, appearing as an unusual multilayered structure, is continuous in both attached and detached retina. Just temporal to the macular center, there is a shallow elevation of Band 4 that reveals an additional thin hyperreflective band. We have previously suggested that Bruch membrane becomes visible when the RPE is elevated or degenerated.⁹ This is seen in this eye as outer retinal hyperreflective Band 5.

Case 2

Supplemental Digital Content 1 (see **Supplemental Figure 1**, <http://links.lww.com/IAE/B205>). Band 1 (blue arrow) is seen in both attached and detached retina. Bands 2 (red arrow) and 2-3 HYPO are seen within attached retina and on the nasal steeper upslope of the detachment, then merge into a single hyperreflective Band on the shallower temporal side (red square arrow). Band 3 (yellow arrow) and a faint thin Band 3-4 HYPO are seen nasally within attached retina but merge within the detachment. Band 4 (green arrow) remains continuous in both attached and detached retina. Just temporal to the macular center, there is a large elevation of Band 4 that reveals an additional underlying thin hyperreflective Band 5 (pink arrow).

Case 3

Figure 4 shows Bands 1, 2, 2-3 HYPO, and 3 in both attached and detached retina. Band 3-4 HYPO is barely visible within the attached retina but disappears within the detachment. Band 4 remains continuous in both attached and detached retina.

Case 4

Supplemental Digital Content 2 (see **Supplemental Figure 2**, <http://links.lww.com/IAE/B206>). Bands 1 (blue arrow), 2 (red arrow), 2-3 HYPO and 3 (yellow arrow) are seen in both attached and detached retina. Band 3-4 HYPO is barely visible within the attached retina but disappears within the detachment. Band 4 (green arrow) remains continuous in both attached and detached retina.

Case 5

Supplemental Digital Content 3 (see **Supplemental Figure 3**, <http://links.lww.com/IAE/B207>). Bands 1 (blue arrow), 2 (red arrow), 2-3 HYPO and 3 (yellow arrow) are seen throughout attached and detached retina. Band 3-4 HYPO is visible within the attached retina but disappears within the detachment. Band 4 (green arrow) remains continuous in both attached and detached retina. A thin hyperreflective Band 5 (pink arrow) is present beneath shallow and irregular elevation of Band 4.

Case 6

Figure 5 shows Bands 1, 2, 2-3 HYPO, 3, 3-4 HYPO, and 4 throughout attached and detached retina. Band 4 remains continuous in both attached and detached retina. A unique additional hyperreflective band appears along the outer portion of the serous detachment.

Case 7

Supplemental Digital Content 4 (see **Supplemental Figure 4**, <http://links.lww.com/IAE/B208>). Band 1 (blue arrow) is seen throughout attached and detached retina. Within the detachment, Bands 2 (red arrow), 2-3 HYPO and 3 (yellow arrow) merge into a thickened shaggy hyperreflective line, which represents elongated photoreceptor outer segments. Band 3-4 HYPO is visible within the attached retina but disappears within the detachment. Band 4 (green arrow) remains continuous in both attached and detached retina. There is a shaggy appearance to the inner surface of Band 4 nasally (orange arrow).

Case 8

Supplemental Digital Content 5 (see **Supplemental Figure 5**, <http://links.lww.com/IAE/B209>). Band 1 (blue arrow) is seen throughout attached and detached retina. Within the detachment, Bands 2 (red arrow), 2-3 HYPO, 3 (yellow arrow) and 3-4 HYPO merge into a thickened shaggy hyperreflective line (red square arrow). Band 4 (green arrow) remains continuous in both attached and detached retina. There are some focal areas of hyperreflectivity along the inner surface of Band 4 (orange arrows).

Case 9

Figure 6 shows Band 1 throughout attached and detached retina. Within the detachment, Bands 2, 2-3 HYPO, 3, and 3-4 HYPO merge into a thickened shaggy hyperreflective line. Band 4 remains continuous in both attached and detached retina. A thin hyperreflective Band 5 is present beneath the shallow irregularly elevated Band 4. There is a focal area of hyperreflectivity along the inner surface of Band 4.

Case 10

Supplemental Digital Content 6 (see **Supplemental Figure 6**, <http://links.lww.com/IAE/B210>). Bands 1 (blue arrow) and 2 (red arrow) are seen throughout the serous detachment. Within the detachment Bands 2-3 HYPO, 3 (yellow arrow) and the barely visible 3-4 HYPO merge into a thickened shaggy hyperreflective line (red square arrow). Band 4 (green arrow) remains continuous in both attached and detached retina.

Case 11

Supplemental Digital Content 7 (see **Supplemental Figure 7**, <http://links.lww.com/IAE/B211>). Band 1 (blue arrow) is seen throughout attached and detached retina. Within the detachment, Bands 2 (red arrow), 2-3 HYPO and 3 (yellow arrow) variably merge into a thickened

Table 1. Summary of OCT Analysis

Case	Figure	Machine	Scan Type	Band 3 Visible Within RD	Band 3 Merges into Outer Detached Retina	Visible Band 3-4 HYPO	Visible BM	Deposits on RPE
1	3	Cirrus	5-Line raster	Yes	No	Yes	Yes	No
2	Supplemental Digital Content 1 (see Supplemental Figure 1, http://links.lww.com/IAE/B205)	Triton	Volume	No	Yes	Yes	Yes	No
3	4	Cirrus	5-Line raster	Yes	No	Yes	No	No
4	Supplemental Digital Content 1 (see Supplemental Figure 2, http://links.lww.com/IAE/B206)	Cirrus	5-Line raster	Yes	No	Yes	No	Yes
5	Supplemental Digital Content 1 (see Supplemental Figure 3, http://links.lww.com/IAE/B207)	Spectralis	Volume	Yes	No	Yes	Yes	No
6	5	Spectralis	Volume	Yes	No	Yes	No	No
7	Supplemental Digital Content 1 (see Supplemental Figure 4, http://links.lww.com/IAE/B208)	Cirrus	5-Line raster	No	Yes	Yes	No	Yes
8	Supplemental Digital Content 1 (see Supplemental Figure 5, http://links.lww.com/IAE/B209)	Spectralis	Volume	No	Yes	Yes	No	Yes
9	6	Cirrus	Volume	No	Yes	Yes	Yes	Yes
10	Supplemental Digital Content 1 (see Supplemental Figure 6, http://links.lww.com/IAE/B210)	Cirrus	5-Line raster	No	Yes	Yes	No	No
11	Supplemental Digital Content 1 (see Supplemental Figure 7, http://links.lww.com/IAE/B211)	Spectralis	EDI	No	Yes	No	Yes	Yes

BM, bruch membrane; EDI, enhanced depth imaging; RD, retinal detachment.

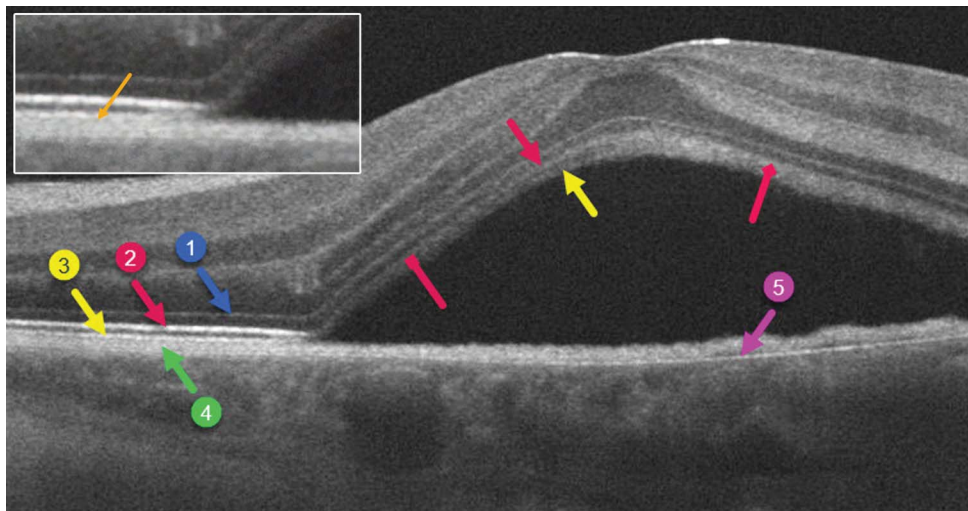


Fig. 3. Band 1 (blue arrow, ELM) and the underlying hyporeflective myoid zone are seen in both attached and detached retina, whereas Band 2 (red arrow, EZ) is seen only in attached retina. A hyporeflective band separates Bands 2 and 3 (2-3 HYPO). In attached retina, Band 3 (yellow arrow) appears as a thin hyperreflective line. Where the retina begins to separate nasally, Bands 2, 2-3 HYPO, and 3 initially merge into a single band within the area of detachment (red square arrow). They then separate into distinct Bands 2 (red arrow), 2-3 HYPO, and 3 (yellow arrow) and finally merge on the descending temporal side of the detachment (red diamond arrow). A thin hyporeflective

band, between Bands 3 and 4, is faintly seen within attached retina (3-4 HYPO) (inset). This band also disappears within the area of detachment. Band 4 (green arrow) is continuous in both attached and detached retina. Just temporal to the macular center, there is a shallow elevation of Band 4 that reveals an additional thin hyperreflective Band 5 (pink arrow, Bruch membrane).

shaggy hyperreflective line (red square arrow). Band 3-4 Hypo is not seen. Band 4 (green arrow) remains continuous in both attached and detached retina. A thin hyperreflective Band 5 (pink arrow) is present beneath a small elevation of Band 4. Band 4 has a shaggy inner border within the serous detachment (orange arrow).

Discussion

Despite it being nearly three decades since the introduction of the OCT,¹⁰ the proposed cellular microstructures that create the outer retinal hyperreflective and hyporeflective bands continue to be debated. What these bands truly represent has great significance in the healthy and diseased fundus since eye doctors worldwide use them when making diagnoses and clinical decisions for their patients.

In this report, we gained new insights into this discussion by looking at 11 representative eyes with CSC. The main question we wanted to answer was whether Cuenca et al’s publication would place Bands 3 through 4 within the RPE cell body, thereby forcing a reallocation of what retinal structures lie inner to Band 3.

Figure 2 summarizes our findings at the transition from attached to detached retina. The only structure in all our eyes that continued unchanged from attached through detached retina was Band 4. Cuenca et al’s Band 3, what they felt represented the RPE’s phagosome zone, consistently elevated into the detachment as either a distinct band (Cases 1, 3, 4, 5, and 6) or merged into the detached outer retina (Cases 2 and 7 through 11). A highly unlikely possibility would be that Cuenca et al’s phagosome zone could be torn off

and detach with the overlying retina. This would invariably cause permanent RPE damage and prevent the relatively normal vision and macular appearance that usually occurs after CSC resolution. The OCT in rhegmatogenous retinal detachment looks quite similar to the serous detachment in CSC, showing that Band 3 separates with the detachment.¹¹ Histologic evidence of rhegmatogenous detachments also shows that the neurosensory retina does not avulse the underlying RPE when it detaches.¹² It is therefore most likely that Band 3 within the CSC detachment is purely a neurosensory retinal structure. In addition, Band 4 must represent the RPE/Bruch complex as described by the IN • OCT Panel because it was always immediately external to the detachment.

Once concluding that Band 2 represented the EZ and Band 4 represented the RPE/Bruch complex, the

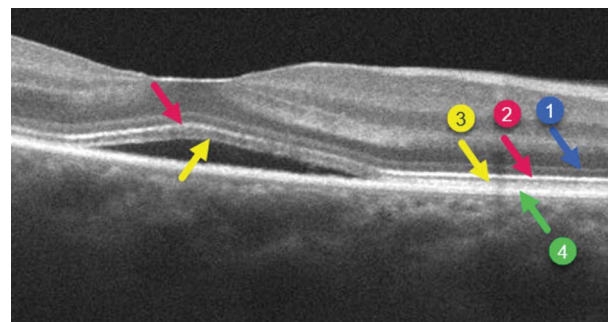


Fig. 4. Bands 1 (blue arrow), 2 (red arrow), 2-3 HYPO, and 3 (yellow arrow) are seen throughout attached and detached retina. Band 3-4 HYPO is visible within the attached retina but disappears within the detachment. Band 4 (green arrow) remains continuous in both attached and detached retina.

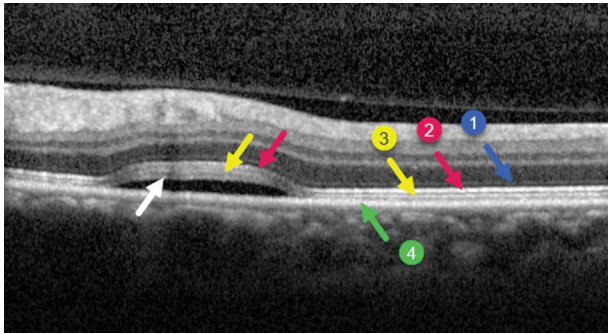


Fig. 5. Bands 1 (blue arrow), 2 (red arrows), 2-3 HYPO, 3 (yellow arrows), 3-4 HYPO, and 4 (green arrow) are seen throughout attached and detached retina. A unique additional hyperreflective band (white arrow) appears along the outer portion of the serous detachment.

IN • OCT Panel needed to account for the intervening bands. They identified their hyporefective layer 12 as the photoreceptor outer segments and hyperreflective layer 13 as a zone or region of disparate elements including outer segments, outer segment tips, and surrounding RPE microvilli. This allocation of layers 12 and 13 was based on previous electron microscopic evidence that the RPE microvilli extend about halfway up the apical portions of the photoreceptors,¹³ thereby potentially creating two identifiable OCT bands. However, using anticellular retinaldehyde-binding protein (CRALBP) antibody staining (specific in the eye for Muller and RPE cells), Cuenca et al's Figures 4 and 5 suggest that CRALBP antibody-stained RPE microvilli surround the entire photoreceptor outer segments and extend up to the EZ. In the 14- μ m-thick sections used in their study, any imperfection in photoreceptor alignment or sectioning angle could have resulted in underestimating this gap depending on the microscopy conditions, which were not provided. This may or may not explain why CRALBP staining contradicts previous electron microscopy findings.

Although the IN • OCT Panel identified virtually all bright and dark bands, for some reason, they did not comment on or define our Band 3-4 HYPO despite it being clearly visible in their Figure 2. We found this band to be variably present in attached retina in all but one of our eyes where it could not be identified (Case 11). It was also visible along the outer margin of detached retina in one eye (Case 6), indicating that this structure is intraretinal. Spaide and Curcio,² summarizing previous histologic data, showed that the outer portions of central foveal cone outer segments, similar to rods throughout the fundus, have virtually no space (1 μ m) separating them from the apical cell body of the RPE. Perifoveal cone outer segments become shorter, creating the supracone space where RPE apical processes extend upwards to envelop them. Although not explicitly stated but suggested by Spaide and Curcio's Figures 6 and 7, this supracone space or

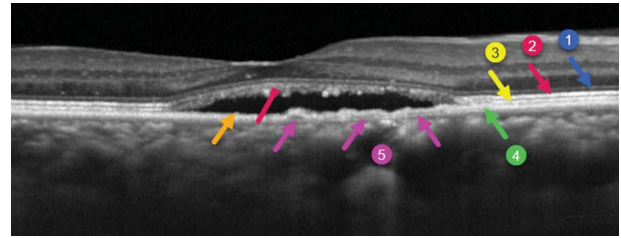


Fig. 6. Band 1 (blue arrow) is seen throughout attached and detached retina. Within the detachment, Bands 2 (red arrow), 2-3 HYPO, 3 (yellow arrow), and 3-4 HYPO merge into a thickened shaggy hyperreflective line (red square arrow). Band 4 (green arrow) remains continuous in both attached and detached retina. A thin hyperreflective Band 5 (pink arrows) is present beneath the shallow irregularly elevated Band 4. There is a focal area of hyperreflectivity along the inner surface of Band 4 (orange arrow).

zone, which would also include rod outer segments and RPE microvilli, is a reasonable candidate for our Band 3-4 Hypo. Consistent with this concept is that their figures showed that this dark band was virtually nonexistent in the central macula but became visible more eccentrically.²

We could not identify the microvilli as a distinct layer in any of our cases nor have these ever been definitively visualized with OCT. Case 6 showed a unique outer retinal hyperreflective band that may represent in part sheared microvilli. Similarly, the shaggy deposits along the inner surface of the RPE/Bruch complex in Cases 4, 7, 8, 9, and 11 could also represent microvilli or shed outer segments. Using electron microscopy to examine the RPE underlying exudative detachments from choroidal melanoma, Kroll¹² found that the microvilli thicken, withdraw, clump along apical portion of the cell, and become devoid of melanin granules. Thus, we are not sure why the microvilli were not definitively visible in any of our OCT scans since, according to Kroll's images, they are about twice the height as the RPE cell body within attached retina and about half this height underlying retinal detachment. Perhaps in CSC, they fully retract, degenerate, or are ripped off and detach with the overlying retina. Or maybe our current technology is unable to resolve the microvilli that are present.

The IN • OCT Consensus panel noted that Band 4 can "occasionally be seen as 2 distinctive hyperreflective bands separated by a hyporefective zone, particularly when pathology is present. The group agreed that these 2 hyperreflective bands correspond with the RPE and Bruch membrane and that they are often not separable under normal conditions. Therefore, this zone should be defined as "RPE/Bruch complex."⁴ Wilk et al¹⁴ noticed a fifth outer retinal hyperreflective spectral domain OCT band in patients with albinism, possibly arising from

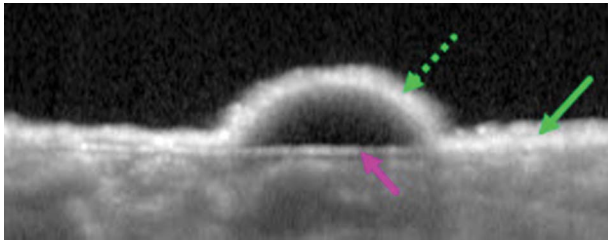


Fig. 7. Magnified view (of Supplemental Digital Content 7) of an RPE detachment. The thicknesses of Band 4 in attachment (green arrow) and detachment (dashed green arrow) are fairly equal. The presumed underlying Bruch membrane appears as a thin hyperreflective band beneath the small RPE detachment (pink arrow). This band merges with Band 4 towards the right of the image and does not significantly contribute to its thickness.

mitochondria in the basolateral third of the RPE cell body. Cuenca et al may therefore be partially correct, with mitochondria contributing at least in part to the outer portion of Band 4, instead of constituting the entire Band 4 as they postulated.

We have previously suggested that Bruch membrane becomes visible when the overlying RPE is attenuated, elevated, or absent.⁹ We named this the “outer Bruch membrane layer” to suggest that the cleavage plane for RPE detachment occurs between the basement membrane of the RPE (previously included in the older concept of Bruch membrane) and the inner collagenous layer. Because clinicopathologic correlation has confirmed this concept,¹⁵ we now prefer to call this line the Bruch membrane layer. We disagree with the IN • OCT that the outer of two RPE bands, when present, represents Bruch membrane. This band, present in several of our eyes with CSC (Cases 1, 2, 5, 9, and 11), appeared as a very thin hyperreflective line that did not significantly contribute to the thickness of Band 4 as it should have according to the IN • OCT (Figure 7). However, because our presumed hyperreflective Bruch membrane arises from and merges with the overlying Band 4, we believe that the current IN • OCT “RPE/Bruch complex” is still appropriate.

Current OCT technology does not allow for us to accurately measure the height of the outer bands into μm resolution. Generally, all the perifoveal hyperreflective Bands from 2 to 4, along with their intervening

hyporefective bands, are fairly equal in height (Figure 1A). Spaide and Curcio² found the heights of the myoid to be 12–14 μm (foveal cone 14 μm , perifoveal cone 13 μm , and rod 12 μm), ellipsoid (Band 2) 16–20 μm (foveal cone 20 μm , perifoveal cone 16 μm , and rod 17 μm), and supracone space (possibly 3-4 HYPO) 16 μm . The RPE height (Band 4) measures 10–14 μm . So, each outer retinal hyporefective and hyperreflective band should be about 15 μm (range 12-20 μm) high. The trilaminar outer segment–interdigitation zone (OSIZ) complex (see below) should therefore be about 45 μm in length. Spaide and Curcio found the rod outer segment length to be 32 μm ; this should equal the height of our OSIZ complex because the rod outer segments extend from the EZ to the RPE. This 13- μm difference may still be within the margin of error for these very rough estimates. The cellular substructures that make up our proposed outer retinal bands are therefore grossly in line with their anatomical lengths. Improvements in the resolution and topographic precision of microscopy studies would help to resolve this debate.

We are therefore left with conflicting evidence making it impossible for us to fully support either the IN • OCT Panel’s or Cuenca et al’s classification schemes (Table 2). Previous electron microscopy evidence shows that the foveal interdigitation zone extends midway up the cone outer segments, but Cuenca et al suggested that it was present throughout their entire length. If it extends up to the EZ, then the IN • OCT Panel’s logic to create the hyporefective outer segment band and the hyperreflective Band 3 (interdigitation zone) falls apart. Because our CSC OCTs consistently located Band 3 in the outer neurosensory retina, it would be highly unlikely for it to represent an RPE cell body structure (phagosome zone) as described by Cuenca et al. Although the IN • OCT Panel did not explicitly name our 3-4 HYPO, Cuenca et al did and felt this represented the RPE melanosome zone despite previous evidence showing that melanosomes are hyperreflective structures.^{8,16}

Table 2. Outer Retinal OCT Nomenclatures

	IN-OCT ⁴	Cuenca et al ²	Bloom & Singal
Layer 9	ELM	ELM	ELM
Layer 10	Myoid zone	Myoid zone	Myoid zone
Layer 11	EZ	EZ	EZ
Layer 12	Cone OS above contact cylinder	OS + IZ	OSIZ inner zone
Layer 13	Cone IZ	RPE phagosome zone	OSIZ middle zone
Hyporefective band	Not mentioned	RPE melanosome zone	OSIZ outer zone
Layer 14	RPE/Bruch complex	RPE mitochondria zone	RPE/Bruch complex

IZ, interdigitation zone; OS, outer segment.




Fig. 8. Proposal for outer retinal bands as described in this communication.

In summary, our analysis supports the current standard that Band 3 is an intraretinal structure. Available evidence does not allow us to conclusively determine what histologic substructures create 2-3 HYPO, Band 3, and 3-4 HYPO. Until these issues are resolved, we suggest grouping these 3 bands into the OSIZ complex (Figure 8). We also propose to rename the IN • OCT Panel's layers 12 (photoreceptor outer segments) and 13 (interdigitation zone) as the inner OSIZ and middle OSIZ, respectively. We call the hyporeflective layer between Bands 3 and 4 the outer OSIZ.

We hope that continued improvement in OCT technology will help to better define the retinal layers in normal and abnormal retinas. In addition, observing how OCT bands are altered in the diseased retina may continue to shed light on what substructures they truly represent.

Key words: OCT, outer retinal bands, interdigitation zone.

Acknowledgments

The authors are indebted to Dr. Richard Spaide for donating cases and to Dr. Spaide and the anonymous reviewer for their invaluable critical review and suggestions.

References

1. Spaide RF. Questioning optical coherence tomography. *Ophthalmology* 2012;119:2203–e1.
2. Spaide RF, Curcio CA. Anatomical correlates to the bands seen in the outer retina by optical coherence tomography: literature review and model. *Retina* 2011;31:1609–1619.
3. Litts KM, Zhang Y, Freund KB, Curcio CA. Optical coherence tomography and histology of age-related macular degeneration support mitochondria as reflectivity sources. *Retina* 2018;38:445–461.
4. Staurengi G, Sadda S, Chakravarthy U, et al. Proposed lexicon for anatomic landmarks in normal posterior segment spectral-domain optical coherence tomography: the IN•OCT consensus. *Ophthalmology* 2014;121:1572–1578.
5. Jonnal RS, Kocaoglu OP, Zawadzki RJ, et al. The cellular origins of the outer retinal bands in optical coherence tomography images. *Invest Ophthalmol Vis Sci* 2014;55:7904–7918.
6. Spaide RF. Outer retinal bands. *Invest Ophthalmol Vis Sci* 2015;56:2505–2506.
7. Cuenca N, Ortuño-Lizarán I, Pinilla I. Cellular characterization of OCT and outer retinal bands using specific immunohistochemistry markers and clinical implications. *Ophthalmology* 2018;125:407–422.
8. Curcio CA, Sparrow JR, Bonilha VL, et al. Re: Cuenca et al.: cellular characterization of OCT and outer retinal bands using specific immunohistochemistry markers and clinical implications (*Ophthalmology*. 2018;125:407-422). *Ophthalmology* 2018;125:e47–e48.
9. Bloom SM, Singal IP. The outer Bruch membrane layer: a previously undescribed spectral-domain optical coherence tomography finding. *Retina* 2011;31:316–323.
10. Huang D, Swanson EA, Lin CP, et al. Optical coherence tomography. *Science* 1991;254:1178–1181.
11. Nakanishi H, Hangai M, Unoki N, et al. Spectral-domain optical coherence tomography imaging of the detached macula in rhegmatogenous retinal detachment. *Retina* 2009;29:232–242.
12. Kroll AJ. Secondary retinal detachment. Electron microscopy of retina and pigment epithelium. *Am J Ophthalmol* 1969;68:223–237.
13. Steinberg RH, Wood I, Hogan MJ. Pigment epithelial ensheathment and phagocytosis of extrafoveal cones in human retina. *Philos Trans R Soc Lond B Biol Sci* 1977;277:459–474.
14. Wilk MA, McAllister JT, Cooper RF, et al. Relationship between foveal cone specialization and pit morphology in albinism. *Invest Ophthalmol Vis Sci* 2014;55:4186–4198.
15. Li M, Dolz-Marco R, Huisingh C, et al. Clinicopathologic correlation of geographic atrophy secondary to age-related macular degeneration. *Retina* 2019;39:802–816.
16. Zhang QX, Lu RW, Messinger JD, et al. In vivo optical coherence tomography of light-driven melanosome translocation in retinal pigment epithelium. *Sci Rep* 2013;3:2644.