

Ocular Manifestations during Rheumatoid Arthritis in Conakry

Alpha Ibrahima Balde^{1*}, Aly Badra Kamissoko², Fremba Camara³, Sonassa Diane³, Emmanuel Yombouno², Adel Lelano², Mohamed Awada²

¹Ophthalmology Department of the Inter-Army Medical and Surgical Centre (CMCIA/BQG) of Camp Samory Touré in Conakry, Conakry, Guinea

²Rheumatology Department of the National Ignace Deen Hospital, CHU of Conakry, Conakry, Guinea

³Regional Hospital of Kankan, Kankan, Guinea

Email: *alphaib2002@gmail.com

How to cite this paper: Balde, A.I., Kamissoko, A.B., Camara, F., Diane, S., Yombouno, E., Lelano, A. and Awada, M. (2022) Ocular Manifestations during Rheumatoid Arthritis in Conakry. *Open Journal of Ophthalmology*, 12, 373-381.

<https://doi.org/10.4236/ojoph.2022.124034>

Received: September 5, 2022

Accepted: November 4, 2022

Published: November 7, 2022

Copyright © 2022 by author(s) and Scientific Research Publishing Inc.

This work is licensed under the Creative Commons Attribution International License (CC BY 4.0).

<http://creativecommons.org/licenses/by/4.0/>



Open Access

Abstract

Rheumatoid arthritis (RA) is a systemic inflammatory disease that primarily affects the joints and may also manifest with extra-articular symptoms. Ocular involvement is common in patients with rheumatoid arthritis and may represent the main clinical manifestation of the disease. **Aim:** To study the epidemiological and therapeutic particularities of ocular manifestations during rheumatoid arthritis in Conakry. **Material and Methods:** This was a descriptive cross-sectional study of 6 months duration from 1 January to 30 June 2018 on patients with RA. All patients with chronic inflammatory rheumatism in whom the diagnosis of rheumatoid arthritis had been made according to the diagnostic criteria of the American College of Rheumatology (ACR) 2010 and these patients benefited from a complete ophthalmologic examination. **Results:** We enrolled 22 patients. The mean age was 43.45 ± 16.07 years (range 21 and 79 years). The mean age at onset of symptoms was 39.4 years with a mean time to diagnosis of RA of 3.9 years. Females dominated with 77.27% of cases with a sex ratio of 0.22 M/F. Photophobia (39.29%), xerophthalmia (31.82%), lacrimation and decreased vision 5 cases or 22.73 each, pruritus (9.09%), foreign body sensation and red eye with 2 cases each or 9.09% were the most frequent symptoms. The different ophthalmological diagnoses found were dry eye 19 cases or 86.36%, allergic conjunctivitis 4 cases or 18.18%, ametropia 3 cases or 13.64%, cataract 2 cases or 9.09%, superficial punctate keratitis 2 cases or 9.09% and chronic glaucoma 1 case or 4.55%. The management of dry eye was based on tear substitutes. Cataract cases (9.09%) required surgical intervention while patients with ametropia (13.04%) received optical correction. Cases of allergic conjunctivitis (18.18%) were reported. **Conclusion:** Good coordination between the ophthalmologist and the rheumatologist is necessary to optimize the management of patients with rheumatoid arthritis.

Keywords

Rheumatoid Arthritis, Ocular Involvement, Conakry

1. Introduction

Rheumatoid arthritis (RA) is a systemic inflammatory disease that primarily affects the joints and may also manifest with extra-articular symptoms [1].

It often involves significant ophthalmological involvement, resulting in varying degrees of ocular morbidity. Ocular manifestations of RA include dry eye, episcleritis, scleritis and peripheral ulcerative keratitis [2].

Although rheumatoid factor (RF) is commonly used for diagnosis, anti-cyclic citrullinated peptide antibodies (anti-CCP antibodies) are a more sensitive and specific marker of systemic involvement in RA [3].

The most common ophthalmic condition affecting RA patients is Sjögren's syndrome, which is associated with approximately one in four patients with rheumatoid arthritis [4].

Ocular manifestations may be directly related to the disease, but may also be a consequence of the therapies used.

Hydroxychloroquine and methotrexate, which are widely used in the background treatment of RA, have been implicated in the occurrence of ocular symptoms and require ophthalmological monitoring [5].

Ocular involvement is common in patients with rheumatoid arthritis and may represent the main clinical manifestation of the disease.

In Serbia, Zlatanović G *et al.* in their study reported 27.2% ocular involvement during rheumatoid arthritis [6].

A German study conducted in 2010 established the diversity of ocular involvement in rheumatoid arthritis: keratoconjunctivitis sicca, episcleritis, scleritis, ulcerative keratitis [7].

In Algeria, during a study conducted on rheumatoid arthritis patients in 2014, visual disturbances had occurred in 15.4% of patients on Hydroxychloroquine (HQC) [8].

In a study conducted in Côte d'Ivoire by Diomandé M *et al.* in 2014, ocular manifestations had been described in 37.5% (9/24) of rheumatoid arthritis patients [9].

In Guinea, we do not have any study on this subject.

The objective of our study was to contribute to the study of the characteristics of ocular manifestations during rheumatoid arthritis in Conakry.

2. Patients and Methods

2.1. Patients

This was a cross-sectional study of descriptive type with a duration of 6 months from 1 January to 30 June 2018 on patients suffering from RA. We included in

our study, all patients examined by a rheumatologist and diagnosed with rheumatoid arthritis, fulfilling the diagnostic criteria of the ACR 2010 and having given their verbal agreement after information on the objectives of the ophthalmologic consultation. Not included in this study were all patients who did not give their consent to the study and did not have rheumatoid arthritis.

2.2. Methods

Data sources: Each patient underwent a full clinical assessment including: An interview specifying the socio-demographic characteristics of the patients; personal history; history of rheumatoid arthritis (age and mode of onset), pain characteristics, number of inflammatory flare-ups, degree of functional discomfort, previous drug treatments prescribed (general or local) and associated extra-articular manifestations. Pain intensity was assessed using a visual analogue scale (VAS).

All patients underwent a detailed ophthalmological examination, which included a careful questioning of their ophthalmological and general history:

Variables: Our variables were epidemiological, clinical and therapeutic.

1) Age: We grouped the patients into age groups with a range of 09 years, the average age of our patients was calculated and the extremes determined. 2) Sex: We calculated the sex ratio to look for the predominance.

Visual acuity: measured with the MONOYER letter scale for patients who could read and the SNELLEN "E" scale for patients who could not read and near visual acuity measured with the Parinaud scale for adults.

The average being 10/10. The visual acuity is lowered or presents an abnormality only when it is lower than 10/10th.

Slit lamp examination: Allowed examination of the appendages (conjunctiva, eyelashes, eyelids and eyebrows) and the anterior segment (cornea, anterior chamber, posterior chamber, iris, pupil, and lens) and the posterior segment (vitreous, retina, optic nerve).

Break-up time (BUT): is the measurement of the tear film break-up time. This means that the time during which the tear film manages to cover the ocular surface in a homogeneous and coherent manner is observed with a slit lamp. A normal GOAL is considered to be greater than or equal to 15 seconds. This is the test most frequently performed by the practitioner because of its speed and simplicity.

The fluorescein test: This involves instilling a small quantity of fluorescein into the eye's cul de sac. The latter will fix itself on the damaged cells of the epithelium. This test allows keratitis to be identified.

Schirmer's test: Schirmer's test allows the objectification of the dry syndrome. The test is performed without local anaesthesia and measures basal and reflex lacrimal secretions. The blotter, placed at the junction between the outer third and half of the lower eyelid, is wetted to the third division (*i.e.* 15 mm) after 5 minutes in a normal patient. Insufficient wetting is defined as less than 5 mm in 5 minutes, in this case dry eye is inferred.

The fundus (FO): Was performed after complete pupillary dilation obtained after instillation of mydriaticum and neosynephrine. It is performed with an ophthalmoscope (Heine Beta 200).

The measurement of the ocular pressure (OT) with the pulsed air tonometer: It diffuses air at the level of the cornea creating its deformation. The value of the intraocular pressure is obtained in relation to the deformation of the cornea. The device measures the time taken by the cornea to flatten. Tonometry is performed in case of suspicion of glaucoma, which is a disease secondary to an increase in intraocular pressure.

2.3. Statistical Methodology

The data were entered and analysed using EPIINFO 7.2.2.1 software. We calculated simple frequencies and relative frequencies (percentages) for the qualitative variables. We calculated the means and standard deviations and determined the range (extreme values: minimum and maximum) for the quantitative variables.

2.4. Ethical Considerations

The information was collected and treated confidentially with strict respect for medical ethics.

3. Results

We included in this study 22 patients with rheumatoid arthritis.

1) Sociodemographic characteristics

The mean age was 43.45 ± 16.07 years (extremes 21 and 79 years). The mean age at onset of symptoms was 39, 4 years with a mean delay in diagnosis of RA of 3.9 years. The age range between 40 and 49 years is the one that includes the maximum number of patients (45.45%) (**Figure 1**).

We noted a clear female predominance with 77.27% of cases with a sex ratio of 0.22 M/F.

2) Personal history

7 patients or 31.82% had a family history of rheumatoid arthritis.

3) Rheumatological data

4) Ophthalmological data

Photophobia (39.29%), xerophthalmia (31.82%), lacrimation and reduced vision (5 cases or 22.73% each), pruritus (9.09%), foreign body sensation and red eye (2 cases or 9.09% each) were the most frequent symptoms.

The different ophthalmological diagnoses found were dry eye 19 cases or 86.36%, conjunctivitis 4 cases or 18.18%, ametropia 3 cases or 13.64%, cataract 2 cases or 9.09%, superficial punctate keratitis 2 cases or 9.09 and chronic glaucoma 1 case or 4.55%.

The management of dry eye was based on tear substitutes. Cataract cases (9.09%) required surgical intervention while patients with ametropia (13.04%) received optical correction. Conjunctivitis (18.18%) was reported.

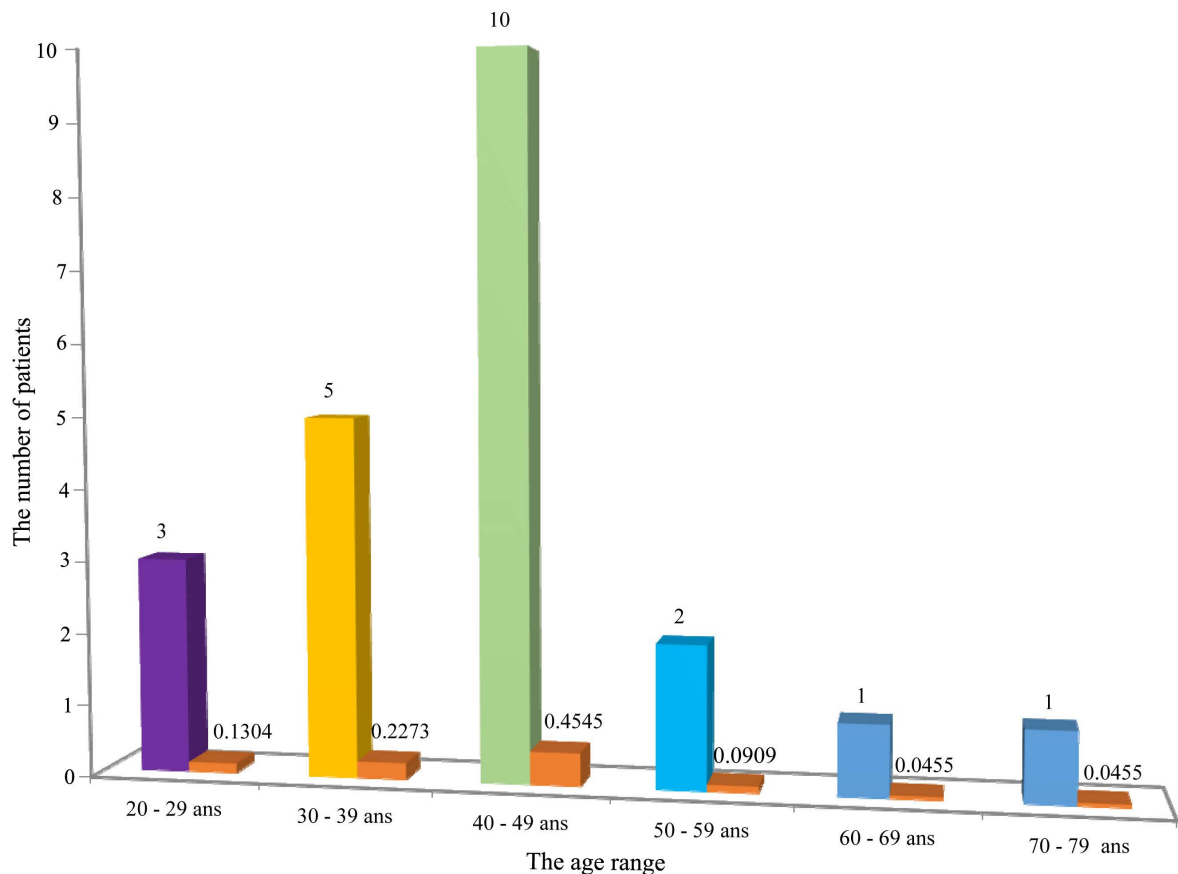


Figure 1. Age distribution of rheumatoid arthritis patients.

4. Discussion

From January 1 to June 30, 2018, we conducted a descriptive cross-sectional study to determine the main ocular manifestations of rheumatoid arthritis in the rheumatology department of the Ignace Deen National Hospital and the ophthalmology department of the Conakry Armed Forces Medical Surgical Centre. The results we obtained allow us to determine the profile of ocular manifestations due to this pathology. This study shows the importance of ocular manifestations caused by rheumatoid arthritis in ophthalmological consultations.

However, our data cannot be extrapolated to the general population due to the hospital recruitment.

In our study we collected 22 patients who had an ophthalmological consultation.

In our series, the ocular manifestations appeared at a mean age of 43.45 ± 16.07 years (extremes of 21 and 79 years) (**Figure 1**) where as they are classically reported at a mean age of 60 years [10]. This result is close to that of Diomandé *et al.* [9] in Côté d'Ivoire in 2014 (40.3 years). The mean age at onset of symptoms was 39.4 years with a mean time to diagnosis of RA of 3.9 years. This could be explained by the relative youth of our population since the patients in our study were on average young adults.

Females dominated with 77.27% of cases with a sex ratio of 0.22 M/F. This female predominance has been reported in other African studies [9] [11]. The high rate of females in our study could be explained on the one hand by the preferential production of INF α in females and on the other hand by a reduction in the proliferation of B and T lymphocytes; a reduction in the activity of macrophages and a protective effect of testosterone [12].

Almost 1/3 of the patients had a family history of rheumatoid arthritis (31.82%) (Figure 2). Different mechanisms are implicated in the systemic involvement in RA. Immune complexes often containing rheumatoid factor in genetically predisposed subjects contribute to these manifestations. Similarly, several studies have demonstrated the role of certain inflammatory cells (macrophages, CD8 lymphocytes) and their secretory products in the genesis of all cardiac, renal, ocular, pulmonary and cutaneous disorders observed in RA [13].

The manifestations observed in our study were different from the typical manifestations usually observed: episcleritis, Gougerot-Sjögren syndrome and scleritis [14]. Gougerot Sjogren's syndrome is observed in 11% - 13% of cases [15] and scleritis in 1.6% - 6% of cases [16].

According to Pétris *et al.*, conjunctivitis and keratitis are frequently encountered in patients with dry eye syndrome (xerophthalmia) [17]. Sometimes indolent, they always manifest as a red eye [18]. This was consistent with our findings.

The responsibility of corticosteroids in the genesis of cataract is known. However, in patients using methotrexate alone, cataract may be related to senescence, and RA is unlikely to be responsible for cataract [19].

Optimal management of patients with rheumatoid arthritis is based on a combined pharmacological and non-pharmacological therapy approach [20]. The combination of methotrexate, prednisone and hydroxychloroquine was the most prescribed background treatment (Table 1). In Africa, these classic disease-modifying treatments are used.

Conventional disease-modifying therapies continue to be used in the management of RA, despite the advent of biotherapies. As their effect is delayed, it is usually necessary to combine them with symptomatic therapies [21]. The management of dry eye was based on tear substitutes. Cataract cases (9.09%) required surgical intervention while patients with ametropia (13.04%) received optical correction. Conjunctivitis (18.18%) was reported (Table 2).

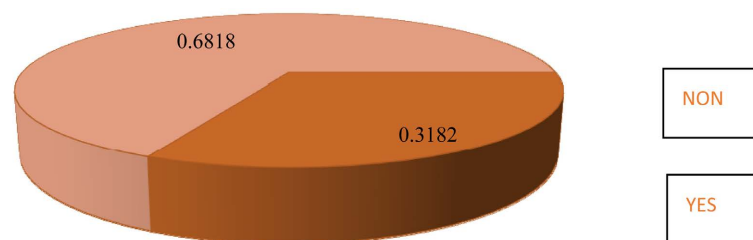


Figure 2. Distribution of the 22 patients with rheumatoid arthritis according to family status.

Table 1. Distribution of rheumatoid arthritis patients according to rheumatological treatment.

Traitement	Nombre de cas	(%)
Prednisolone	19	86.36
Méthotrexate	16	72.72
Hydroxychloroquine	14	63.64
Analgesics Non steroidal anti-inflammatory drugs	14	63.64
	02	9.09
Salazopyrin	01	4.55
Azathioprine	01	4.55

Table 2. Ophthalmological diagnosis.

Diagnostics	Number of cases	%
Ametropia	3	13.64
Cataract	2	9.09
Conjunctivitis	4	18.18
Glaucoma chronic	1	4.55
Keratitis punctatus	2	9.09
Dry eye	19	86.36

Of the patients receiving symptomatic treatment, 63.64% were on analgesics and 9.09% of patients on NSAIDs. Treatment of dry eye syndrome is aimed at stabilising the systemic disease, increasing or maintaining tear secretion and decreasing surface inflammation [22].

5. Conclusions

Our study shows a high frequency of ophthalmologic involvement in RA that warrants systematic ophthalmologic examination and follow-up.

Methotrexate and other conventional disease-modifying therapies are still relevant. Ocular manifestations in rheumatoid arthritis appear at a relatively young age in our context. These were mainly dry eyes, cataracts and keratitis. Good coordination between the ophthalmologist and the rheumatologist is necessary to optimize the management of patients with rheumatoid disease.

Conflicts of Interest

The authors declare that they have no conflicts of interest in relation to this article.

References

- [1] Onur, G., Nilüfer, Y., Ahmet, A., *et al.* (2017) Épaisseur cornéenne, sclérale,

- choroïdienne et fovéale chez les patients atteints de polyarthrite rhumatoïde. *Revue du Rhumatisme*, **47**, 315-319.
- [2] Itty, S., Pulido, J.S., Bakri, S.J., Baratz, K.H., Matteson, E.L. and Hodge, D.O. (2008) Anti-Cyclic Citrullinated Peptide, Rheumatoid Factor, and Ocular Symptoms Typical of Rheumatoid Arthritis. *Transactions of the American Ophthalmological Society*, **106**, 75-81.
- [3] El-Banna, H. and Jiman-Fatani, A. (2014) Anti-Cyclic Citrullinated Peptide Antibodies and Paraoxonase-1 Polymorphism in Rheumatoid Arthritis. *BMC Musculoskeletal Disorders*, **15**, Article No. 379. <https://doi.org/10.1186/1471-2474-15-379>
- [4] Antero, D.C., Parra, A.G.M., Miyazaki, F.H., Gehlen, M. and Skare, T.L. (2011) Secondary Sjögren's Syndrome and Disease Activity of Rheumatoid Arthritis. *Revista da Associação Médica Brasileira*, **57**, 319-322. <https://doi.org/10.1590/S0104-42302011000300015>
- [5] Bele-Philippe, P. (2013) Service de Rhumatologie. CHRU de Lille. Rhumatismes Inflammatoires Chroniques.
- [6] Zlatanović, G., Veselinović, D., Cekić, S., *et al.* (2010) Ocular Manifestation of Rheumatoid Arthritis different Forms and Frequency. *Bosnian Journal of Basic Medical Sciences*, **10**, 323-327. <https://doi.org/10.17305/bjbm.2010.2680>
- [7] Zink, A. and Albrecht, K. (2016) Wie häufig sind muskuloskeletale Erkrankungen in Deutschland? *Zeitschrift für Rheumatologie*, **75**, 346-353. <https://doi.org/10.1007/s00393-016-0094-2>
- [8] Hamahmi, N. and Toumi, F.Z. (2014) La prise en charge thérapeutique de la polyarthrite rhumatoïde et la place de la biothérapie en Algérie. <http://dspace.univtlemcen.dz/handle/112/7823>
- [9] Kouakou, E.S.C.L., Diomandé, M., Yao, J.C., Kodio, B., Djaha, K.J.M., *et al.* (2014) Manifestations oculaires au cours de la polyarthrite rhumatoïde: A propos de 24 cas vus à Abidjan. *Mali Médical*, **29**, 33-35.
- [10] Bhadoria, D.P., Bhadoria, P., Sundaram, K.R., Panda, A. and Malviya, A.N. (1989) Ocular Manifestation of Rheumatoid Arthritis. *Journal of Indian Medical Association*, **87**, 134-135.
- [11] Korba, W., Zrour, S., Dimassi, R., Younes, M., Ben Yahia, S., Attiab, S., *et al.* (2007) Manifestations oculaires au cours de la polyarthrite rhumatoïde. *Revue du Rhumatisme*, **74**, 1048. <https://doi.org/10.1016/j.rhum.2007.10.026>
- [12] Morel, J., Miossec, P. and Combe, B. (2004) Immunopathologie de la polyarthrite rhumatoïde. *EMC-Rhumatologie-Orthopédie*, **1**, 218-230. <https://doi.org/10.1016/j.emcrho.2004.03.003>
- [13] Nass, F.R., Skare, T.L., Goeldner, I., *et al.* (2016) Analysis of Four Serum Biomarkers in Rheumatoid Arthritis: Association with Extra Articular Manifestations in Patients and Arthralgia in Relatives. *Revista Brasileira de Reumatologia (English Edition)*, **57**, 286-293. <https://doi.org/10.1016/j.rbre.2016.03.001>
- [14] Pawlowsky, Y. (2000) *Rhumatologie. Ellipses*, Paris, 431 p.
- [15] Bron, J.A. (1998) The Red Eye in Rheumatoid Arthritis. In: Klippel, J.H. and Dieppe, P.A., Eds., *Rheumatology*, Mosby International Limited, London, 1612-1614.
- [16] Ryckewaert, A. and Bardin, T. (1995) Polyarthrite Rhumatoïde. In: Kplan, M.F., Peltier, A.P., Meyer, O., Piette, J.C., Eds., *Les Maladies Systémiques*, Flammarion Médecine-Sciences, Paris, 143-194.
- [17] Petris, C.K. and Almony, A. (2012) Ophthalmic Manifestations of Rheumatologic

- Disease: Diagnosis and Management. *Missouri Medicine*, **109**, 53-58.
- [18] Ladas, J.G. and Mondino, B.J. (2000) Systemic Disorders Associated with Peripheral Corneal Ulceration. *Current Opinion in Ophthalmology*, **11**, 468-471.
<https://doi.org/10.1097/00055735-200012000-00014>
- [19] Bettero, R.G., Cebrian, R.F. and Skare, T.L. (2008) Prevalence of Ocular Manifestation in 198 Patients with Rheumatoid Arthritis: A Retrospective Study. *Arquivos Brasileiros de Oftalmologia*, **71**, 365-369.
<https://doi.org/10.1590/S0004-27492008000300011>
- [20] Ksir, S., Akasbi, N., Efemba, K., El Aissaoui, A., El Kinany, K., et al. (2019) Factors Associated with Extra-Articular Manifestations in Rheumatoid Arthritis. *International Journal of Surgery and Medicine*, **6**, Article ID: 277.
<https://doi.org/10.15342/ijms.v6ir.277>
- [21] Mounach, A., Ghozlani, I., Rezqi, A. and El Maghraoui, A. (2012) Classic Symptomatic and Disease Modifying Treatments for Rheumatoid Arthritis. *La Revue Marocaine de l'Ophtalmologie*, **20**, 4-7.
- [22] Robert, P.Y. (2012) Treatment of Xerophthalmia in Gougerot-Sjögren Syndrome. *Revue du Praticien*, **62**, 236-237.