

# Strategies for improving the early diagnosis of keratoconus

Yue Shi

Doheny Eye Institute, Department of Ophthalmology, David Geffen School of Medicine, University of California at Los Angeles, Los Angeles, CA, USA

**Abstract:** To diagnose keratoconus at its earliest stage is meaningful in order to avoid refractive surgery in the eye, which may lead to further damage in the abnormal cornea structure and consequently cause iatrogenic ectasia. In this article, the following aspects of detecting earliest stage of keratoconus were reviewed: 1) nomenclature of the earliest forms of keratoconus; 2) diagnosis of keratoconus using curvature-based topography (also known as Placido-based topography, ie, videokeratography) as a traditional method and elevation-based topography as a new method which has gained popularity in recent years; and 3) other methods analyzing keratoconus cornea like corneal biomechanics and wavefront sensing. Elevation-based topography using either Scheimpflug imaging techniques or slit-scanning imaging techniques has shown to be advantageous over the curvature-based topography in detecting keratoconus at its earliest stage. Posterior elevation of the cornea is notified to enhance the sensitivity and specificity of detection if used along with the measurements of anterior surface of the cornea. Cornea biomechanics analysis and wavefront sensing also revealed differences between normal eyes and keratoconic eyes in their earliest stage. Combining the latest technology and the traditional techniques will be the future trend to improve early diagnosis of keratoconus.

**Keywords:** keratoconus, early diagnosis, Scheimpflug imaging, slit-scanning imaging, wavefront error, corneal biomechanics

## Introduction

One of the most important aspects of avoiding iatrogenic ectasia in cornea during refractive surgery was to detect keratoconus in its earliest stage. However, there were several challenges in earliest detection of this disease. First, in the literature there were several names referring to the earliest stage of keratoconus, which were frequently misused and cause confusion. Second, speaking of keratoconus, eye doctors get used too much to describing the cornea simply with a single K value or as a skewed axis bowtie in videokeratoscopy. This single K value, in fact, was far from sensitive in detecting earliest keratoconus than using a comprehensive system, which also accounts for other cornea property parameters. Videokeratoscopy itself has had numerous limitations, especially compared with the newly developed elevation-based topography. Third, even if there were many other technologies that show different aspects in earliest keratoconus, like biomechanics features and wavefront aberrations, the lack of awareness among eye doctors to combine multiple cornea features comprehensively limited their role in early detection of this disease. In this article, the above listed three challenges will be reviewed and discussed.

Correspondence: Yue Shi  
Doheny Eye Institute, Department of Ophthalmology, David Geffen School of Medicine, University of California at Los Angeles, Suite 100, Doheny Vision Research Center, 1355 San Pablo Street, Los Angeles, CA 90033, USA  
Tel +1 323 442 6393  
Email joy.yues@gmail.com



Hopefully by doing so, it will lead to the recognition of the latest trend in early detection of keratoconus.

## Nomenclature of earliest keratoconus

### Forme fruste keratoconus

Referring to the earliest stage keratoconus, three names were widely encountered in the literature: forme fruste keratoconus (FFKC), keratoconus suspect, and preclinical or subclinical keratoconus. FFKC was firstly proposed by Amsler<sup>1</sup> in 1961 and then adapted by Klyce<sup>2</sup> as “The fellow eye (of a clinical manifest keratoconus eye) that has no clinical findings of any sort except for certain topographical changes (vide infra)”.

In the literature, there is a clear consensus for FFKC that it should be the healthier eye in a keratoconus patient, and this healthier eye should not have any clinical signs of clinical manifest keratoconus, like Vogt’s striae and Fleischer’s ring, nor should this eye have any significant topographic changes like skewed axis bowtie which indicates it is a clinical manifest keratoconus.<sup>3,4</sup>

### Keratoconus suspect

There were several opinions on when to use the term “keratoconus suspect”. In Klyce’s option, keratoconus suspect should be a term reserved for corneas with very specific topographic changes and for patients who do not have keratoconus in the fellow eye: “In general terms, a topographic keratoconus suspect will have a localized area of abnormal steepening which is often inferior, but can be central, or, rarely, superior, and may present as an asymmetrical, truncated or skewed-axis bowtie”. He then summarized “the term keratoconus suspect should properly be reserved for corneas with subtle signs of keratoconus but without evidence of clinical keratoconus in either eye”.<sup>2</sup> In fact, his definition here also fits subclinical keratoconic eyes, as we would describe in the next few sections.

But another opinion overlapped keratoconus suspect with FFKC as we defined above. Waring<sup>5</sup> identified keratoconus suspect as “the fellow eyes of unilateral keratoconus that had no slit-lamp findings”. He further noted the term keratoconus suspect should extend to “patients with manifest clinical keratoconus in one eye and only videokeratographic inferior steepening in the other, and in family members of patients with clinically manifest keratoconus, who show only videokeratographic steepening inferiorly”, because such a way is “in the same sense that a patient who has glaucoma suspect.”

A third opinion of Rabinowitz et al defined keratoconus suspect in a progressive prospective and their definition

was independent of the status of the fellow eye as “no slit lamp findings, no scissoring on retinoscopy, and AB/SRAX (Asymmetric Bowtie pattern with a Skewed Radial Axis) on videokeratography only”.<sup>6</sup> They developed a detection system to differentiate normal cornea and keratoconus suspect. They recommend using the inferior–superior (I-S) value, which computed the vertical gradient cornea power of 6 mm region. An I-S value between 1.4 and 1.9 diopters suggests a keratoconus suspect, while a larger value suggests clinical keratoconus. A lower value suggests a normal variant cornea. But they also admitted that the differences in videokeratography indexes between keratoconus suspect and normal eyes are subtle. Their criteria for keratoconus suspect actually also fit to subclinical keratoconus, as we would describe in the next few sections.

Some authors provided their own definitions of keratoconus suspect. Rao et al<sup>7</sup> defined their keratoconus suspect, after excluding the contact lens warping, as “to achieve the computer designation keratoconus pattern suspected, either the central K or the I-S value calculated for a given videokeratography must be two standard deviations greater than the mean”.

At this point though, one needs to be cautious about the localized steepening of the cornea, which could be caused by various other factors than earliest keratoconus. Common factors that can cause inferior steepening of videokeratography but no clinical manifest of keratoconus include but not limited to “hard contact lenses wearing, nosecone compression, technician’s finger compression, and a dry cornea inferiorly”.<sup>5</sup> The rigid contact lens caused cornea warpage can persist for quite a long time. So the term keratoconus suspect should be applied to these patients until contact lenses have been removed for an adequate period of time.<sup>8,9</sup>

Due to tremendous discrepancies among authors, we highly suggest using this terminology only with a clear description of objective, topographic index-based criteria. Also, figuring out what exactly the criteria are helps tremendously in understanding various authors throughout the literature.

### Subclinical keratoconus

Some of the authors in the literature agreed on the subclinical keratoconus as a fellow eye of a clinical manifest keratoconus eye with the following features: 1) no clinical findings (keratometric, retinoscopic, or biomicroscopic) of keratoconus; 2) I-S asymmetry and/or bowtie pattern with SRAX, detected on tangential Placido disk-based videokeratography (CSO EyeTop or Keratron); and 3) no history of contact lens wear, ocular surgery, or trauma.<sup>10–12</sup>

Some others have had their own definitions. Jafarinasab et al<sup>13</sup> used major and minor criteria to select subclinical keratoconus, independent of the condition of the fellow eye. Major criteria include: 1) the presence of Vogt's striae and Fleischer ring measuring at least 2 mm; 2) SRAX index  $>20^\circ$ ; 3) KPI  $>30\%$ ; 4) KSI  $>30\%$ ; and 5) an abnormal KCI. Minor criteria include: 1) asymmetric bow-tie pattern without SRAX; 2) inferior steepening; 3) KSI between 15% and 30%; and 4) KPI between 23% and 30%. Subclinical keratoconus was diagnosed in the presence of one major or two minor criteria.

SRAX is an index that reflects the irregular astigmatism in keratoconus. KPI is a linear discriminate analysis of eight quantitative topographic indices. KCI is derived by using a binary decision-making tree that was input from the KPI and four other indices. KSI is an index derived from neural network algorithm.

Ruiseñor Vázquez et al<sup>17</sup> used a keratoconus severity score system, which involved evaluating slit-lamp findings, topography pattern, cornea power, and higher order aberrations. While one eye scored high enough to be considered as clinical keratoconus, the fellow eye scored lower would be considered a subclinical keratoconus.

Sometimes, people used this term to refer to a much larger variety of earliest stage keratoconus, like including FFKC and keratoconus suspect.<sup>18</sup> But it was soon criticized and their definition was requested to be refined with a combination of clear objective topographic indices.<sup>19</sup>

Therefore, similar to the term keratoconus suspect, make sure of the exact definition of the author when the term "subclinical keratoconus" is mentioned. Also, for authors to mention this term, they need to provide their clear definitions and employ objective topographic indices to do so.

## The fellow eye and family history

In 1991, Maguire and Lowry observed a fellow eye in a unilateral keratoconus patient for 2 years. At the very beginning of the observation, this patient had one eye identified as clinical manifest keratoconus and the other eye had a normal topography, but showed a localized cornea steepening of "44.5 diopters located 2.1 mm inferior to the vertex normal".<sup>20</sup> Two year later, "cone apex power increased to 51 diopters, and the patient developed a Fleischer's ring, Vogt's striae, and mild visual aberration";<sup>20</sup> in other words, a clinical manifest keratoconus.

After the first observation of a single fellow eye within 2 years by Maguire and Lowry, Li et al<sup>21</sup> observed over a 100 patients diagnosed as unilateral keratoconus at the baseline. They concluded that within 16 years,

approximately 50% of the clinical normal fellow eyes would develop into clinical manifest keratoconus. The greatest risk of onset is during the first 6 years of diagnosis.

Li et al<sup>22</sup> also followed over 300 people who had a family history of keratoconus but did not have keratoconus themselves (unaffected keratoconus relatives) for 1 to 8 years, and compared them with over 100 normal controls. They concluded that between the two groups, there was no statistically significant difference in progression to keratoconus. The family history did not play a significant role in keratoconus progression.

Therefore, the fellow eye of a unilateral keratoconus patient should be refrained from refractive surgery, especially within the first 6 years after first diagnosis. People with a keratoconus family history but who did not have keratoconus themselves are more likely to be treated as people from a normal population.

## Summary of nomenclature of earliest keratoconus

FFKC as clearly agreed in the literature should refer to the fellow eye of a clinical manifest keratoconus. The eye itself should have neither clinical signs of keratoconus nor significant topographic signs that lead to diagnosis of keratoconus.

Subclinical keratoconus and keratoconus suspect can be used interchangeably for an eye showing some feature of keratoconus topography, but not severe enough to be named as clinical manifest keratoconus. Its fellow eye can be either a clinical manifest keratoconus or a normal eye. But one needs to provide his/her definition with objective, topographic-based criteria if these names are to be used. For the purpose of clarity, we will use only "subclinical keratoconus" for the later part of this article to indicate the situation suitable for both names, except when citing another author's work.

## Detect earliest keratoconus with curvature-based topography, like videokeratography

In the past, early detection of keratoconus was based on keratoscope, a Placido-based curvature distortion measurement of the anterior surface of the cornea.<sup>23</sup>

In the recent 30 years, the emergence of computer-assisted keratoscope, well known as videokeratography, enabled quantitative and more precise measurement on anterior cornea surface of keratoconic eyes. Rabinowitz and McDonnell found that a central K value larger than 47.2 diopters and an I-S value larger than 1.4 diopters to indicate that it is a subclinical keratoconus instead of a normal eye. A central

K larger than 47.8 diopters and an I-S value larger than 1.9 diopters indicate it is a clinical manifest keratoconus.<sup>24</sup>

Rabinowitz and Rasheed<sup>14</sup> later developed an even better index known as KISA% to enhance the specificity of diagnoses keratoconus in its earliest stage. KISA% involves two more parameters: Astigmatism (AST), the degree of regular corneal astigmatism, and SRAX index, an expression of the irregular astigmatism occurring in keratoconus. Rabinowitz indicates that the eyes with KISA% larger than 100% will be identified as clinical manifest keratoconus, and 60% to 100% to be keratoconus suspect with minimal overlapping with normal corneas. KISA% is computed as follows.

$$\text{KISA}\% = \frac{(\text{K}) \times (\text{I-S}) \times (\text{AST}) \times (\text{SRAX}) \times 100}{300}$$

where:

K is central K value;

I-S is inferior to superior value, which is the difference of cornea power between average of 5 inferior points and 5 superior points 3 mm from the center at 30 degree intervals;

AST is the regular astigmatism;

SRAX is the skewed radial axis index, an expression of irregular astigmatism occurring in keratoconus. (see Rabinowitz and Rasheed<sup>14</sup> for more detailed calculations of above mentioned indices).

In the meantime, Maeda–Klyce developed a KPI system which uses eight indices generated from videokeratography to detect keratoconus. A KPI score larger than 0.23 is indicative of keratoconus. However, it is not readily useful for keratoconus suspect due to a significant overlapping between keratoconus suspect and keratoconus in its scoring system.

Maeda et al<sup>25</sup> developed a neural network model to detect and classify cornea topography abnormalities. Beside

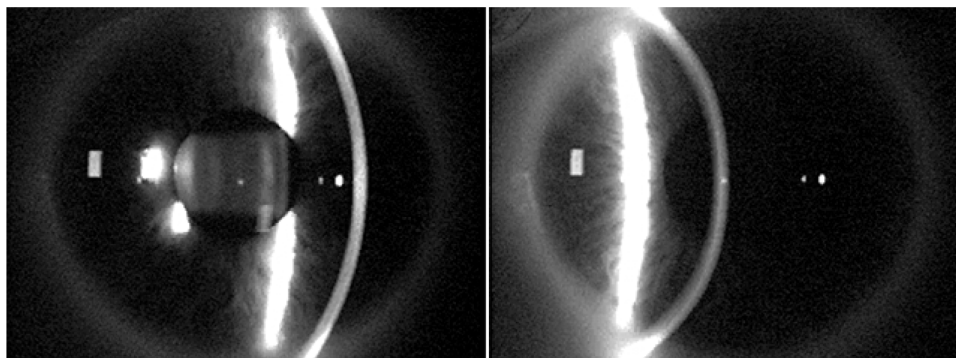
keratoconus, this model was capable of examining a variety of cornea abnormalities including postphotorefractive keratectomy and postkeratoplasty. Later, Smolek and Klyce<sup>16</sup> further modified this model, which approached 100% of accuracy, sensitivity, and specificity in the diagnosis of keratoconus.

The Rabinowitz system, the Maeda–Klyce system, and the later developed neural network system were the three most widely used diagnostic systems based on videokeratography to define normal cornea, subclinical keratoconus (or keratoconus suspect), and clinical manifest keratoconus. These definitions were then widely used to classify normal and ectatic cornea in more recent research that evaluated the sensitivity and specificity of parameters measured by elevation-based topography and other modalities.

## Elevation-based topography

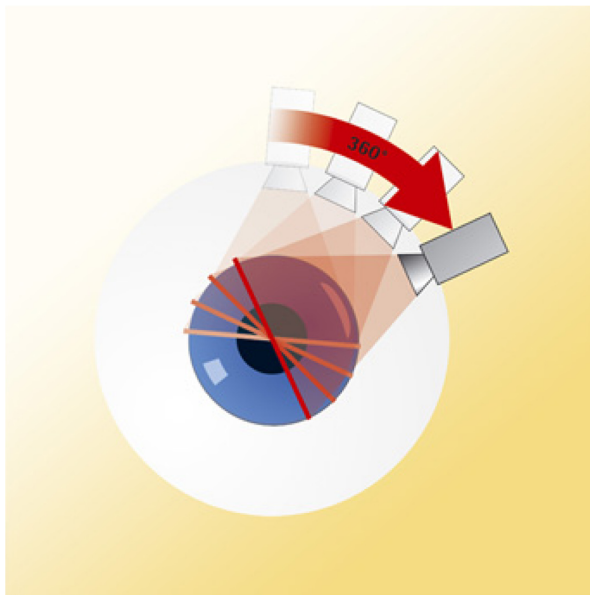
In recent years, the elevation-based topography gained more and more attention in keratoconus early detection. Two principles were employed in the most popular elevation-based topography devices, slit-scanning and Scheimpflug imaging techniques. Slit-scanning technique is used in the Orbscan II (Bausch and Lomb Surgical, Inc., Rochester, NY, USA) and it is the only commercial available slit-scanning implementation. Whereas, Scheimpflug is widely used in a variety of instruments: the Pentacam (Oculus, Arlington, WA, USA), the Galilei (Ziemer Ophthalmic Systems AG, Port, Switzerland), the Precisio (Ligi Tecnologie Medicali, Taranto, Italy), and the Sirius (CSO Ophthalmic, Instrument Company, Auckland, New Zealand).

The slit-scanning technique was performed by two vertical scans of 40 light-slits projections, 20 from the left and 20 from the right, onto the camera to the instrument axis (Figure 1). The Scheimpflug camera obtained images by rotating around the optic axis with projected light-slits (Figure 2). The anterior and posterior edges of the slits would



**Figure 1** Slit-scanning technique performed by Orbscan.

**Notes:** Orbscan projects slits from the right while scanning the cornea. Image courtesy of Oliveira CM, Ribeiro C, Franco S, Corneal imaging with slit-scanning and Scheimpflug imaging techniques, *Clinical and Experimental Optometry*, 2011;94(1):33–42,<sup>26</sup> John Wiley & Sons Ltd.



**Figure 2** Scheimpflug technique performed by Pentacam.

**Notes:** The camera rotates 360 degrees to capture images from light slits projected by the instrument. Image courtesy to Oculus, Inc., Arlington, WA. Available from: <http://www.pentacam.com/sites/messprinzip.php>.<sup>49</sup>

be captured by the camera and analyzed to reconstruct the anterior segment surfaces.

Elevation-based topography obtains obvious advantages than the traditional curvature-based topography. First, elevation-based topography covers much more cornea area than videokeratography (9 versus 6 mm) in diameter. Larger measurement area allows detection of changes in more peripheral cornea, which is affected in later stage of keratoconus and in pellucid marginal degeneration.

Second, elevation-based topography does not make the assumption that the eye is a Gullstrand's reduced eye, which has to be made in videokeratography and other Placido-based topography. In this assumption, the line of sight is assumed to be the same as the line that goes through the anatomic center of the eye. In fact, in most of the eyes, the angle between these two lines (known as angle Kappa) is less than 5 degrees. Most of the time, such an assumption would not result in too much bias. However, if a normal eye happened to have an angle kappa greater than 5 degrees, it will be easily misdiagnosed as having an asymmetric bowtie in curvature-based topography. Elevation-based topography does not make such a mistake because it avoids the Gullstrand's reduced eye assumption.

Another advantage of using elevation-based topography is that it is capable of measuring the posterior surface of the cornea in addition to the anterior surface. This is the most exciting feature offered by elevation-based topography because in recent years more and more studies have shown

that compared to normal eyes, there is a significant posterior surface difference in earliest keratoconus eyes.

There were significant posterior elevation differences between normal eye and the eye fulfilled either of the Rabinowitz or Klyce–Maeda keratoconus criteria.<sup>7</sup> Posterior elevation of the cornea had a higher sensitivity and specificity to discriminate keratoconic eyes from normal eyes in earlier staged keratoconus than later staged keratoconus, based on the Amsler–Krumeich classification staging of keratoconus.<sup>27,28</sup> In subclinical keratoconus, there was a significant difference in posterior elevation than normal eyes (Table 1, column 3).<sup>12</sup> Adding posterior corneal elevation data to an artificial intelligence algorithm would improve the sensitivity and specificity to separate normal eyes and subclinical keratoconic eyes (Table 1, row “Arbelaez 2012”, columns 9–11).<sup>18</sup> However, none of them recommended using posterior elevation as a single factor to diagnose subclinical keratoconus due to the sensitivity and specificity always being incapable of steadily reaching more than 90% and the disparity of cut-off points among different measuring methods (Table 1, columns 7 and 8). The posterior elevation should be combined with other parameters such as cornea curvature, cornea power, anterior elevation, and thickness to achieve a better effect.

In FFKC, elevation-based topography was able to tell apart FFKC from normal eyes, whereas Placido-based topography, even using a neural network recognition system, could not do so.<sup>3</sup> Fukuda et al<sup>29</sup> proved that either a three-dimensional anterior segment optical coherence tomography or an elevation-based topography adopting Scheimpflug principle combined with a curvature-based topography would recognize the differences between FFKC and normal eyes (Table 2, row “Fukuda 2013”). Muftuoglu et al<sup>4</sup> further noted in Pentacam that a parameter called “back difference elevation” was superior than posterior elevation to recognized FFKC. However, using either of the above two parameters alone would not be recommended to diagnose FFKC due to insufficient sensitivity and specificity (Table 2, columns 7 and 8).

There was also a study that compared the keratoconus cross-linking treatment guided either by curvature-based topography or an elevation-based topography adopting the Scheimpflug principle. Crosslinking guided by Scheimpflug resulted in better cornea surface regularity, more flat and more central cones, compared to the ones guided by curvature-based topography.<sup>30</sup>

Nederan et al<sup>31</sup> compared the most popular two types of elevation-based topography, Pentacam and Orbscan IIz. They found the two devices have no differences in measuring cornea central thickness (CCT) and thinnest central thickness, but there was a significant difference in anterior chamber depth and pupil diameter. The measurements of different

**Table 1** Studies use posterior elevation and derived parameters to discriminate subclinical keratoconus and normal eyes

Authors	Modality	Significant difference between subclinical KC and N	AUROC		Cut-off point		Multiple factor models	
			Parameter that achieves high AUROC	AUROC (%)	Value	Sensitivity (%)	Content of model	Sensitivity (%)
De Sanctis et al <sup>10</sup> (2008)	Pentacam	Yes	Max PE5	93	29 µm	68	90.8	
Jafarinasab et al <sup>17</sup> (2011)	Galilei	Yes	Max PE7	92	50.5 µm	79.9	94	
Ucakhan et al <sup>18</sup> (2011)	Pentacam	Yes	Max PE5	78.9	20.5 µm	81.8	66.7	All posterior elevation parameters combined in model
Arbelaez et al <sup>18</sup> (2012)	Sirius							All posterior elevation parameter + cornea power + thickness
								Anterior cornea surface data (curvature, thickness, and height)
								Anterior + posterior cornea surface and pachymetry data (curvature, thickness, and height)
Ruiseñor Vázquez et al <sup>17</sup> (2014)	Pentacam	Yes	Db	80	0.78	62.2	88.2	
		Yes	Da	94	1.26	89.2	90.3	

**Notes:** Modalities used to achieve posterior elevation and derived parameters include Pentacam, Galilei, and Sirius. All the best posterior parameters have a significant difference between subclinical keratoconic eyes (KC) and normal eyes (N). AUROC, area under receiver operating characteristic curve, is a tool to select optimal models for diagnostic decision making. In this table, a parameter or model with a higher AUROC has higher sensitivity and specificity to discriminate subclinical keratoconus from normal eyes. Cut-off point is the parameter value at which the highest sensitivity and specificity are achieved. Notice not a single posterior parameter was able to achieve greater than 90% in both sensitivity and specificity. Multiple factor models are the logistic regression model of artificial intelligence models that involves more than one parameter. Notice adding cornea power and thickness into the model improves both sensitivity and specificity from only using posterior elevation parameters alone. Adding posterior cornea parameters to the model improves sensitivity and specificity from only using anterior cornea parameters. And this anterior + posterior cornea surface and pachymetry data (curvature, thickness, and height) model achieves larger than 90% in both sensitivity and specificity. Max PE5 is a parameter that measures the maximum posterior elevation from the reference best-fit sphere within the central 5 mm of cornea. Max PE7 is similar to Max PE5 but measures within the central 7 mm of cornea. Db and Da both were obtained from the Pentacam software Belin-Ambrosio Enhanced Ectasia Display. Db is the deviation of the normality of the back cornea elevation, whereas Da is the deviation of the normality of relational thickness. Relational thickness indices express the ratio of the thinnest pachymetry and the respective pachymetry progression. Pachymetry progression refers to the percentage in cornea thickness increase along each meridian starting from the thinnest corneal point.

**Table 2** Studies use posterior elevation and derived parameters to discriminate forme fruste keratoconus (FFKC) and normal eyes (N)

Authors (year)	Modality	Significant difference between FFKC and N	AUROC		Cut-off point		
			Parameter that achieves high AUROC	AUROC (%)	Value	Sensitivity (%)	Specificity (%)
Fukuda et al <sup>29</sup> (2013)	3D AS-OCT	Yes	Max PE5	91.2			
	Scheimpflug topography	Yes	Max PE5	92			
Muftuoglu et al <sup>4</sup> (2013)	Pentacam	No, P=0.033	Posterior elevation	68.3	14.7 $\mu$ m	67	59
		Yes	BDE	75.5	13.2 $\mu$ m	74	65

**Notes:** Modalities used to achieve posterior elevation and derived parameters include three-dimensional anterior segment optical coherence tomography (3D AS-OCT), Scheimpflug topography, and Pentacam topography. AUROC, area under receiver operating characteristic curve, is a tool to select optimal models for diagnostic decision making. In this table, a parameter or model with a higher AUROC has higher sensitivity and specificity to discriminate FFKC from normal eyes. Max PE5 is a parameter that measures the maximum posterior elevation from the reference best-fit sphere within the central 5 mm of cornea. BDE stands for the Back difference elevation on Belin-Ambrosio Enhanced Ectasia Display of Scheimpflug device. It is claimed to have a better performance than posterior elevation in discriminant FFKC and normal eyes. Cut-off point is the parameter value at which the highest sensitivity and specificity are achieved. Notice neither posterior elevation nor posterior elevation difference alone was able to achieve more than 90% of sensitivity and specificity.

devices were not interchangeable. The disparity between the two methods was not elucidated. However, it was observed that by removal of the acoustic factor and CCT would be overestimated by Orbscan IIz.<sup>32</sup> Orbscan IIz's usage of ultrasound to assist its pachymetry measurement may underline its possibility to overestimate corneal thickness.

Beside the cornea curvature and elevation, earliest keratoconus showed significant differences than the normal eyes in a variety of other cornea characteristics. The two most widely studied characteristics include corneal biomechanics and wavefront aberrations.

## Corneal biomechanics

It is well known keratoconus eyes have a significant lower CCT, corneal hysteresis, and corneal resistant factor (CRF) than normal eyes.<sup>33,34</sup> Table 3 shows corneal hysteresis, CRF, and CCT values for normal eyes, FFKC, mild keratoconic, and keratoconic eyes from different studies. In mild keratoconus, it is controversial to say there is a significant difference between mild keratoconus and normal eyes in cornea hysteresis.<sup>33,35</sup> Area under receiver operating characteristic curve shows only 87% of sensitivity and 65% of specificity

**Table 3** Corneal central thickness (CCT), corneal hysteresis (CH), and corneal resistant factor (CRF) in normal (N), forme fruste keratoconus (FFKC), mild keratoconus (mild KC), and keratoconus (KC) eyes

Authors (year)	Eyes	CH (mm)	CRF (Hg)	CCT ( $\mu$ m)
Shah et al <sup>33</sup> (2007)	KC	9.6 $\pm$ 2.2		491.8 $\pm$ 54.7
	N	10.7 $\pm$ 2.0		545.0 $\pm$ 36.4
Fontes et al <sup>35</sup> (2010)	mild KC	8.3 $\pm$ 1.36	7.85 $\pm$ 1.49	503.0 $\pm$ 34.15
	N	10.17 $\pm$ 1.79	10.13 $\pm$ 2.00	544.7 $\pm$ 35.89
Schweitzer et al <sup>36</sup> (2010)	FFKC	9.1 $\pm$ 1.8	9.2 $\pm$ 1.8	
	N	10.3 $\pm$ 1.9	11.1 $\pm$ 2.0	

**Note:** Data are presented as mean  $\pm$  standard deviation.

for corneal hysteresis, and 90.5% of sensitivity and 66% of specificity for CRF to discriminate mild keratoconus and normal eyes.<sup>35</sup> However, some studies group FFKC and normal eyes with central cornea thickness.<sup>36</sup> In the low corneal central thickness groups (<500 and <540  $\mu$ m), corneal hysteresis achieves 91% of sensitivity for both cornea thickness groups to distinguish FFKC and normal eyes.<sup>36</sup> But for CRF it is only 81% and 87% sensitivity. Specificity was not studied.

## Wavefront aberrations

In the earliest studies, wavefront aberrations were derived from videokeratography surface height measurement. Using this method, Schwiegerling and Greivenkamp<sup>37</sup> found that an index made up of two lower order aberrations (eg, defocus and astigmatism) detects keratoconus as effective as curvature characteristics like I-S value, steepest radial axes, and surface asymmetry index. Later, Gobbe and Guillon<sup>38</sup> found that keratoconus suspect distinguishes itself from normal eyes by a larger amount of vertical coma.

Later on, Shack–Hartmann wavefront sensor was widely used to measure the wavefront characteristics in keratoconus, subclinical keratoconus, and FFKC. Vertical coma is the most important higher order aberration in keratoconus eyes.<sup>39</sup> Vertical coma was also the most widely mentioned aberration that had a significant difference between subclinical keratoconus and normal eyes.<sup>40–42</sup> However, using vertical coma alone cannot achieve high enough sensitivity and specificity to discriminate subclinical keratoconus and normal eyes.<sup>43</sup>

In FFKC, vertical coma also was the most widely mentioned aberration that was significantly larger than normal eyes.<sup>44–46</sup> Although front surface vertical coma played a much more important role than other aberrations and parameters,<sup>44</sup> using this single aberration term only was not good enough to discriminate FFKC and normal eyes.<sup>44,45</sup> If other parameters

like I-S value, other higher order aberrations, and pachymetry were involved, the discrimination function would achieve better performance.<sup>44,45</sup> Sensitivity and specificity achieved one if front surface aberrations, back surface aberrations, and pachymetry are used altogether in the discrimination of FFKC and normal eyes.<sup>44</sup>

## Summary and conclusion of early detection of keratoconus

Subtle changes in earliest keratoconus eyes like posterior corneal elevation, corneal hysteresis, cornea resistant factor, and vertical coma could be detected by elevation-based topography, biomechanics, and wavefront sensor. However, none of these subtle changes had enough sensitivity or specificity to be used alone to make a diagnosis. To develop a multiple factor system that combines curvature measurements, elevation measurements, pachymetry, biomechanics, and wavefront error of the cornea will be the future trend to diagnose the earliest form of keratoconus including forme fruste keratoconus and subclinical keratoconus.

## Disclosure

The author reports no conflicts of interest in this work.

## References

- Amsler M. [The 'forme fruste' of keratoconus]. *Wien Klin Wochenschr*. 1961;73:842–843.
- Klyce SD. Chasing the suspect: keratoconus. *Br J Ophthalmol*. 2009;93:845–847.
- Saad A, Gatinel D. Topographic and tomographic properties of forme fruste keratoconus corneas. *Invest Ophthalmol Vis Sci*. 2010;51:5546–5555.
- Muftuoglu O, Ayar O, Ozulken K, Ozyol E, Akinci A. Posterior corneal elevation and back difference corneal elevation in diagnosing forme fruste keratoconus in the fellow eyes of unilateral keratoconus patients. *J Cataract Refract Surg*. 2013;39:1348–1357.
- Waring GO. Nomenclature for keratoconus suspects. *Refract Corneal Surg*. 1993;9:219–222.
- Li X, Yang H, Rabinowitz YS. Keratoconus: Classification scheme based on videokeratography and clinical signs. *J Cataract Refract Surg*. 2009;35(9):1597–1603.
- Rao SN, Raviv T, Majmudar PA, Epstein RJ. Role of Orbscan II in screening keratoconus suspects before refractive corneal surgery. *Ophthalmology*. 2002;109:1642–1646.
- Ruiz-Montenegro J, Mafra CH, Wilson SE, Jumper JM, Klyce SD, Mendelson EN. Corneal topographic alterations in normal contact lens wearers. *Ophthalmology*. 1993;100:128–134.
- Wilson SE, Lin DTC, Klyce SD, Reidy JJ, Insler MS. Topographic changes in contact lens-induced corneal warpage. *Ophthalmology*. 1990;97:734–744.
- De Sanctis U, Loiacono C, Richiardi L, Turco D, Mutani B, Grignolo FM. Sensitivity and specificity of posterior corneal elevation measured by Pentacam in discriminating keratoconus/subclinical keratoconus. *Ophthalmology*. 2008;115:1534–1539.
- De Sanctis U, Aragno V, Dalmaso P, Brusasco L, Grignolo F. Diagnosis of subclinical keratoconus using posterior elevation measured with 2 different methods. *Cornea*. 2013;32:911–915.
- Uçakhan ÖÖ, Çetinkor V, Özkan M, Kanpolat A. Evaluation of Scheimpflug imaging parameters in subclinical keratoconus, keratoconus, and normal eyes. *J Cataract Refract Surg*. 2011;37:1116–1124.
- Jafarinasab MR, Shirzadeh E, Feizi S, Karimian F, Akaberi A, Hasanpour H. Sensitivity and specificity of posterior and anterior corneal elevation measured by Orbscan in diagnosis of clinical and subclinical keratoconus. *J Ophthalmic Vis Res*. 2015;10:10–15.
- Rabinowitz YS, Rasheed K. KISA% index: a quantitative videokeratography algorithm embodying minimal topographic criteria for diagnosing keratoconus. *J Cataract Refract Surg*. 1999;25:1327–1335.
- Maeda N, Klyce SD, Smolek MK, Thompson HW. Automated keratoconus screening with corneal topography analysis. *Invest Ophthalmol Vis Sci*. 1994;35:2749–2757.
- Smolek MK, Klyce SD. Current keratoconus detection methods compared with a neural network approach. *Invest Ophthalmol Vis Sci*. 1997;38:2290–2299.
- Ruiseñor Vázquez PR, Galletti JD, Minguez N, et al. Pentacam Scheimpflug tomography findings in topographically normal patients and subclinical keratoconus cases. *Am J Ophthalmol*. 2014;158:32–40.
- Arbelaez MC, Versaci F, Vestri G, Barboni P, Savini G. Use of a support vector machine for keratoconus and subclinical keratoconus detection by topographic and tomographic data. *Ophthalmology*. 2012;119:2231–2238.
- Saad A, Gatinel D. Subclinical keratoconus: the need for an objective classification system. *Ophthalmology*. 2013;120:e56–e57.
- Maguire LJ, Lowry JC. Identifying progression of subclinical keratoconus by serial topography analysis. *Am J Ophthalmol*. 1991;112(1):41–45.
- Li X, Rabinowitz YS, Rasheed K, Yang H. Longitudinal study of the normal eyes in unilateral keratoconus patients. *Ophthalmology*. 2004;111:440–446.
- Li X, Yang H, Rabinowitz YS. Longitudinal study of keratoconus progression. *Exp Eye Res*. 2007;85:502–507.
- Krachmer JH, Feder RS, Belin MW. Keratoconus and related noninflammatory corneal thinning disorders. *Surv Ophthalmol*. 1984;28:293–322.
- Rabinowitz YS, McDonnell PJ. Computer-assisted corneal topography in keratoconus. *Refract Corneal Surg*. 1989;5:400–408.
- Maeda N, Klyce SD, Smolek MK. Neural network classification of corneal topography. Preliminary demonstration. *Invest Ophthalmol Vis Sci*. 1995;36:1327–1335.
- Oliveira CM, Ribeiro C, Franco S. Corneal imaging with slit-scanning and Scheimpflug imaging techniques. *Clin Exp Optom*. 2011;94:33–42.
- Ishii R, Kamiya K, Igarashi A, Shimizu K, Utsumi Y, Kumanomido T. Correlation of corneal elevation with severity of keratoconus by means of anterior and posterior topographic analysis. *Cornea*. 2012;31:253–258.
- Kamiya K, Ishii R, Shimizu K, Igarashi A. Evaluation of corneal elevation, pachymetry and keratometry in keratoconic eyes with respect to the stage of Amsler-Krumeich classification. *Br J Ophthalmol*. 2014;98:459–463.
- Fukuda S, Beheregaray S, Hoshi S, et al. Comparison of three-dimensional optical coherence tomography and combining a rotating Scheimpflug camera with a Placido topography system for forme fruste keratoconus diagnosis. *Br J Ophthalmol*. 2013;97:1554–1559.
- Kanellopoulos AJ, Asimellis G. Comparison of Placido disc and Scheimpflug image-derived topography-guided excimer laser surface normalization combined with higher fluence CXL: the Athens Protocol, in progressive keratoconus. *Clin Ophthalmol*. 2013;7:1385–1396.
- Naderan M, Shoar S, Naderan M, Kamaledin MA, Rajabi MT. Comparison of corneal measurements in keratoconic eyes using rotating Scheimpflug camera and scanning-slit topography. *Int J Ophthalmol*. 2015;8(2):275–280.
- González-Pérez J, González-Méijome JM, Rodríguez Ares MT, Parafita MÁ. Central corneal thickness measured with three optical devices and ultrasound pachometry. *Eye Contact Lens*. 2011;37:66–70.



33. Shah S, Laiquzzaman M, Bhojwani R, Mantry S, Cunliffe I. Assessment of the biomechanical properties of the cornea with the ocular response analyzer in normal and keratoconic eyes. *Invest Ophthalmol Vis Sci.* 2007;48:3026–3031.
34. Shah S, Laiquzzaman M. Comparison of corneal biomechanics in pre and post-refractive surgery and keratoconic eyes by Ocular Response Analyser. *Cont Lens Anterior Eye.* 2009;32:129–132.
35. Fontes BM, Ambrósio R, Jardim D, Velarde GC, Nosé W. Corneal biomechanical metrics and anterior segment parameters in mild keratoconus. *Ophthalmology.* 2010;117:673–679.
36. Schweitzer C, Roberts CJ, Mahmoud AM, et al. Screening of forme fruste keratoconus with the ocular response analyzer. *Invest Ophthalmol Vis Sci.* 2010;51:2403–2410.
37. Schwiegerling J, Greivenkamp JE. Keratoconus detection based on videokeratographic height data. *Optom Vis Sci.* 1996;73:721–728.
38. Gobbe M, Guillon M. Corneal wavefront aberration measurements to detect keratoconus patients. *Cont Lens Anterior Eye.* 2005;28:57–66.
39. Pantanelli S, MacRae S, Jeong TM, Yoon G. Characterizing the wave aberration in eyes with keratoconus or penetrating keratoplasty using a high-dynamic range wavefront sensor. *Ophthalmology.* 2007;114:2013–2021.
40. Bühren J, Kühne C, Kohnen T. Defining subclinical keratoconus using corneal first-surface higher-order aberrations. *Am J Ophthalmol.* 2007;143:381–389.
41. Gordon-Shaag A, Millodot M, Ifrah R, Shneur E. Aberrations and topography in normal, keratoconus-suspect, and keratoconic eyes. *Optom Vis Sci.* 2012;89:411–418.
42. Jafri B, Li X, Yang H, Rabinowitz YS. Higher order wavefront aberrations and topography in early and suspected keratoconus. *J Refract Surg.* 2007;23:774–781.
43. Reddy JC, Rapuano CJ, Cater JR, Suri K, Nagra PK, Hammersmith KM. Comparative evaluation of dual Scheimpflug imaging parameters in keratoconus, early keratoconus, and normal eyes. *J Cataract Refract Surg.* 2014;40:582–592.
44. Bühren J, Kook D, Yoon G, Kohnen T. Detection of subclinical keratoconus by using corneal anterior and posterior surface aberrations and thickness spatial profiles. *Invest Ophthalmol Vis Sci.* 2010;51:3424–3432.
45. Bühren J, Kühne C, Kohnen T. [Wavefront analysis for the diagnosis of subclinical keratoconus]. *Ophthalmologe.* 2006;103:783–790.
46. Saad A, Gatinel D. Evaluation of total and corneal wavefront high order aberrations for the detection of forme fruste keratoconus. *Invest Ophthalmol Vis Sci.* 2012;53:2978–2992.
47. Jafarinasab MR, Feizi S, Karimian F, Hasanpour H. Evaluation of corneal elevation in eyes with subclinical keratoconus and keratoconus using Galilei double Scheimpflug analyzer. *Eur J Ophthalmol.* 2013;23(3):377–384.
48. Uçakhan ÖÖ, Çetinkor V, Özkan M, Kanpolat A. Evaluation of Scheimpflug imaging parameters in subclinical keratoconus, keratoconus, and normal eyes. *J Cataract Refract Surg.* 2011;37(6):1116–1124.
49. The Pentacam. The Gold Standard in Anterior Segment Tomography. [webpage on the Internet]. OCULUS Optikgeräte GmbH; 2015 [cited December 12, 2015]. Available from: <http://www.pentacam.com/sites/messprinzip.php>. Accessed December 25, 2015.

## Clinical Optometry

### Publish your work in this journal

Clinical Optometry is an international, peer-reviewed, open access journal publishing original research, basic science, clinical and epidemiological studies, reviews and evaluations on clinical optometry. All aspects of patient care are addressed within the journal as well as the practice of optometry including economic and business analyses. Basic and clinical

Submit your manuscript here: <http://www.dovepress.com/clinical-optometry-journal>

Dovepress

research papers are published that cover all aspects of optics, refraction and its application to the theory and practice of optometry. The manuscript management system is completely online and includes a very quick and fair peer-review system, which is all easy to use. Visit <http://www.dovepress.com/testimonials.php> to read real quotes from published authors.