

Fakhri Allahyari, Hamideh Molaee* and Javad Hosseini Nejad

Covid-19 vaccines and neurological complications: a systematic review

<https://doi.org/10.1515/znc-2022-0092>

Received April 19, 2022; accepted August 9, 2022;

published online September 12, 2022

Abstract: The COVID-19 mainly causes respiratory disorders with high infection and severe morbidity and mortality. Neurologists have concerns about potential neurological side effects, profits, and timing of COVID-19 vaccines. This study aimed to review systematically research for the COVID-19 vaccine and neurological complications. Data was searched in Scopus, ISI web of knowledge, Medline, PubMed, Wiley, Embase, International Clinical Trials Registry Platform and Clinical Trials, Cochrane Library, and Google Scholar. Two reviewer authors individually searched and assessed the titles and abstracts of all articles. The third reviewer resolved disagreement between them. Data were documented regarding study location, study design, type of complications, number of patients, various types of COVID-19 vaccine, and type of neurological complications. Six studies in COVID-19 vaccine and neurological complications include two studies about neurological manifestations after the mRNA vaccines, four records about side effects of vector-based vaccine were included in the study. The main neurological complication associated mRNA vaccines were body aches, paresthesia, and difficulty walking, erythema migrans lesion, fatigue, myalgia, and pain in the left lateral deltoid region. The major neurological complication related to vector-based vaccines were urinary retention difficulty, feeding and ambulating, arm soreness, mild fatigue, chills, left-sided facial droop, headaches, a generalized epileptic seizure, hemianopia, and mild aphasia, acute somnolence and right-hand hemiparesis, acute transverse myelitis, deep vein thrombosis in her left leg, a vigilance disorder and a twitching, a severe immobilizing opsoclonus myoclonus syndrome, and encephalitis. A large

spectrum of severe neurological unfavorable has been reported. These complications could occur as a result of molecular stimulation and later neuronal damage. Generally, the advantages of COVID-19 vaccination are dominant on the risks of a neurological complication at both individual and population levels. Future investigations will be required to find any relationship between neurological complications and COVID-19 vaccines principally as new strains of the virus and new vaccines are technologically advanced against them.

Keywords: complication; Covid-19 vaccine; neurological; neuron; side effect.

1 Introduction

COVID-19 infection is a global pandemic disease that was reported in Wuhan, China, in December 2019 for the first time. The COVID-19 mainly causes respiratory disorders with high infection and severe morbidity and mortality. The symptoms of COVID-19 include sore throat, myalgia, fever, cough, anosmia, and diarrhea [1]. The symptoms are incidence moderate to severe acute respiratory distress syndrome, multiple organ failure, and eventually death [2].

There are numerous vaccine platforms (i.e., mRNA, DNA, nonreplicating viral vectors, etc.) for administrating this global pandemic disease around the world [3]. The FDA approved two vaccines to prevent COVID-19 infection in December 2020. There are four major vaccine mechanisms for the COVID-19 vaccines production, including protein-based vaccines, mRNA-based vaccines, DNA-based vaccines, and inactivated virus that motivates the immune response [2–4].

At first, two patients incidence transverse myelitis after Oxford/AstraZeneca vaccination. Therefore, concerns about neurological complications from COVID-19 vaccines increased [5]. One patient had pre-existing multiple sclerosis; thus, it may not be related to the vaccination, whereas the other patient was determined to be probably associated with the vaccination [6]. The Clinical trials from the mRNA vaccine demonstrated that seven cases (of 37,000 vaccine recipients) had Bell's palsy, and any case had not incident Guillain–Barre syndrome (GBS) [7]. One

*Corresponding author: Hamideh Molaee, Trauma Research Center, Baqiyatallah University of Medical Sciences, Tehran, Iran, E-mail: hmolaeei2021@gmail.com

Fakhri Allahyari and Javad Hosseini Nejad, Neuroscience Research Center, Baqiyatallah University of Medical Sciences, Tehran, Iran, E-mail: dr.f.allahyari@gmail.com (F. Allahyari), javadhoseini1360@gmail.com (J. Hosseini Nejad). <https://orcid.org/0000-0001-7088-2588> (F. Allahyari). <https://orcid.org/0000-0003-1770-2968> (J. Hosseini Nejad)

patient had the GBS in the Johnson & Johnson vaccine trial [8]. Likewise, no relationship between GBS and COVID-19 infection has been found [9].

The most prevalent neurological signs included headache, dizziness, pain, myalgia, muscle spasms, and paresthesia, which are anticipated to transpire as acute, transient special effects after vaccination. Infrequent cases of dysphonia, diplopia, tremor, seizures, tinnitus, and repetition of herpes zoster have been reported [10]. However, some neurological patients also received the vaccination, thus neurological signs occur inside the post-vaccination window accidentally. To reports, there has not been an alert indicating more increased rates of neurological disorder related to the COVID-19 vaccines.

The patients who receive immunosuppressive drugs should have special attentions around COVID-19 vaccines, despite there is no absolute neurological disorder about COVID-19 vaccination [11]. These patients potency be at developed risk for severe COVID-19, doing vaccination principally vital. However, immunosuppressive drugs may decrease immune responses to vaccination [11]. Consequently, timing of the vaccine performance plays an essential role in matching immune response [12, 13].

Numerous neurological complications are associated with COVID-19 infection [2, 3]. Neurologists have concerns about potential neurological side effects, profits, and timing of COVID-19 vaccines. Therefore, this study aimed to review systematically research for the COVID-19 vaccine and neurological complications to achieve a comprehensive view and management of neurological diseases in COVID-19 periods.

2 Methods

Online databases such as Scopus, ISI Web of Knowledge, Medline, PubMed, Wiley, Embase, International Clinical Trials Registry Platform and Clinical Trials, Cochrane Library, and Google Scholar were searched. Keywords and terms were included Covid-19 vaccine, neuron, complication, neurological, side effect, virus, central neurological system, aches, paresthesia, erythema migrans lesion, fatigue, myalgia, pain, vector-based vaccines, urinary retention difficulty, ambulating, arm soreness, mild fatigue, chills, facial droop, headaches, epileptic seizure, hemianopia, aphasia, acute somnolence, hemiparesis, acute transverse myelitis, deep vein thrombosis, twitching, opsoclonus myoclonus syndrome, and encephalitis.

Exclusion criteria were included non-neurological disease, lack of the type of Covid-19 vaccine data, only brief studies, clinical studies without preliminary results.

Two review authors individually searched and assessed the abstracts and titles of all articles; the third reviewer determined difference between them.

Data were documented regarding study location, study design, type of complications, number of patients, various types of COVID-19 vaccine, and type of neurological complications (Figure 1).

3 Results

Six studies in COVID-19 vaccine and neurological complications include two studies about neurological manifestations after the mRNA vaccines; four records about side effects of vector-based vaccine were included in the study. The main neurological complication associated mRNA vaccines were body aches, paresthesia, and difficulty walking, erythema migrans lesion, fatigue, myalgia, and pain in the left lateral deltoid region. The major neurological complication related to vector-based vaccines were urinary retention difficulty, feeding and ambulating, arm soreness, mild fatigue, chills, left-sided facial droop, headaches, a generalized epileptic seizure, hemianopia, and mild aphasia, acute somnolence and right-hand hemiparesis, acute transverse myelitis, deep vein thrombosis in her left leg, a vigilance disorder and a twitching, a severe immobilizing opsoclonus myoclonus syndrome, and encephalitis.

Three RNA vaccines (Pfizer and BioNTech, Moderna, AstraZeneca) have been proven since December 2020 [14]. The Pfizer and BioNTech are mRNA vaccines, whereas the AstraZeneca vaccine is a non-replicating viral vector-based vaccine by a live adenovirus carrier. There are a few cases that showed neurological manifestations with COVID-19 vaccinations. The neurological manifestations including transverse myelitis and cerebral venous sinus thrombosis after the AstraZeneca vaccine [15], seven cases of Bell's palsy, and a single Guillain–Barre syndrome case after mRNA vaccinations [16]. Other complications include temporary and unspecific sign effects, headache, dizziness, muscle pain, and paresthesia [17]. The complications include venous thrombosis and cerebral are reported after Johnson & Johnson COVID-19 vaccination [18].

Gustavo C. Román et al. reported acute transverse myelitis (ATM) as a severe complication after a booster dose of the COVID-19 vaccine (ChAdOx1 nCoV-19 (AZD1222)) in the three cases [19].

Zuhorn et al. demonstrated neurological side effects after the first dose of ChAdOx1 nCov-19 vaccine in the three cases report. They reported post-vaccine encephalitis with deep vein thrombosis in the left leg, a vigilance disorder and a twitching, and a severe immobilizing opsoclonus myoclonus syndrome after vaccination. Zuhorn et al. showed a temporal association between ChAdOx1

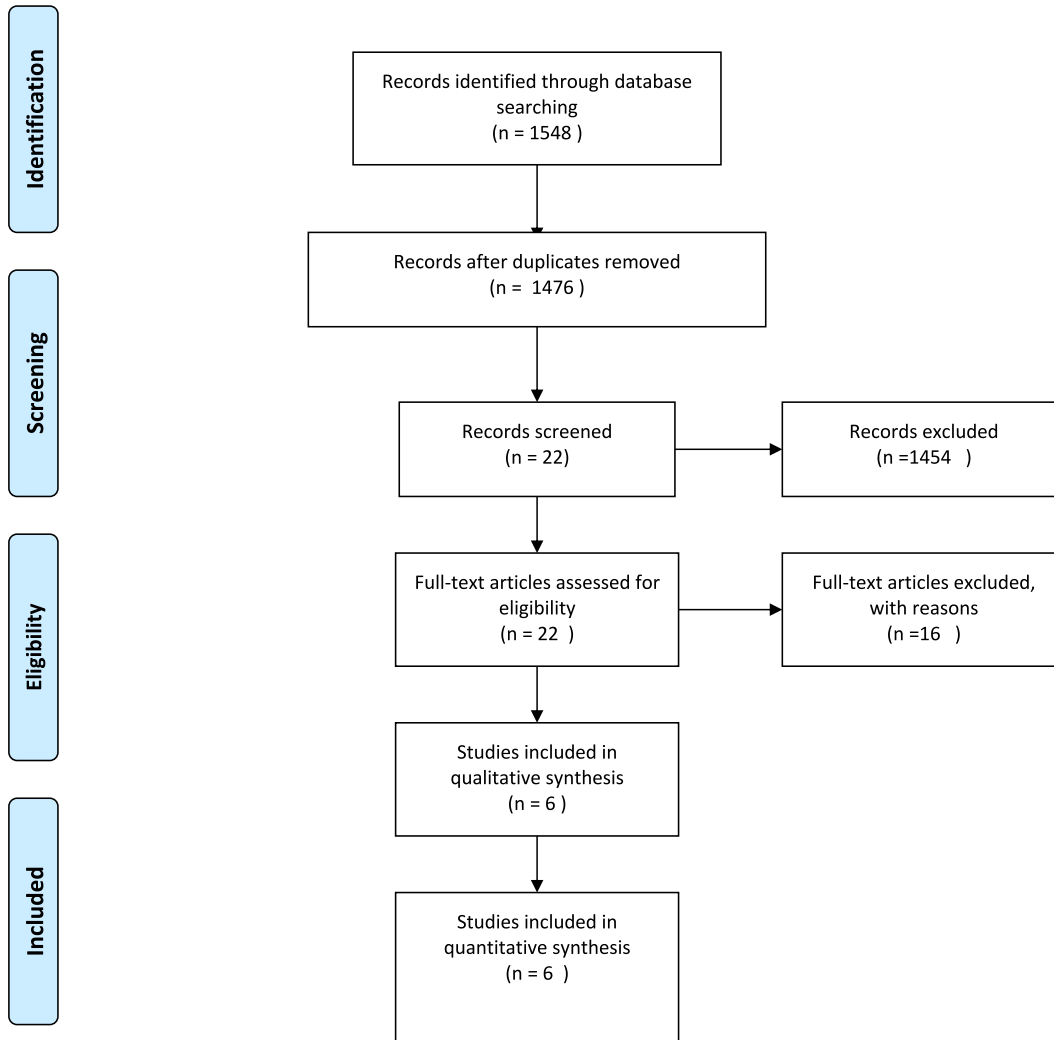


Figure 1: PRISMA flow chart of the study.

nCov-19 vaccination and the presentation of encephalitis [20].

Waheed et al. reported an 82-year-old female with neurological side effects such as Guillain–Barre syndrome after Pfizer COVID-19 vaccine. She had body aches, paresthesia, and difficulty walking. The malaise and body aches revealed in the first week after vaccination. In the second week, she had worse side effects such as increased difficulty in walking. Also, the other complications have been seen such as weak pinprick in bilateral lower extremities up to the knees, and areflexia in both upper and lower extremities with the diagnosis of GBS [16].

Wolf et al. evaluated neurological complications after AstraZeneca vaccines in three individuals. They reported the neurological complications such as thrombocytopenia and intracranial venous sinus thrombosis, headaches, generalized epileptic seizure, hemianopia, mild aphasia,

acute somnolence, and right-hand hemiparesis. They reported elevated levels of D-dimers, platelet factor 4 anti-platelet antibodies, corona spike protein antibodies, combined with thrombocytopenia in the individuals [21].

Prasad et al. reported a rare bifacial diplegia variant of Guillain–Barre syndrome case after Janssen COVID-19 Vaccination. Guillain-Barre syndrome (GBS) is an immune-mediated demyelinating disturbance that attacks the peripheral nervous system. They reported a 41-year-old man with an acute start of urinary retention 12 days following his COVID-19 vaccination. The patient reported arm soreness, mild fatigue, and chills following three days. On the 15th day, the left-sided facial falls down was revealed, and Bell's palsy was diagnosed. On 21st day, he was involved with weakness, paresthesias in all extremities, difficulty feeding, ambulating because of his weakness, and a new start of right facial weakness [22].

Sophie C, et al. (2022) introduced two cases with Parsonage–Turner syndrome after COVID-19 vaccination with Pfizer-BioNTech and Moderna (mRNA-1273) vaccines. Neurological side effects after Pfizer-BioNTech vaccine were severe, electric, shooting pain in his left the erythema migrans lesion, fatigue, myalgias, sudden-start, intense, and cramping pain in the left lateral deltoid region were revealed after Moderna (mRNA-1273) vaccine. After a 3-month follow-up, the patient presented no residual pain but increased weakness. The motion and strength were good but did not return to the first levels [24] (Table 1).

4 Discussion

The neurological manifestations after Covid-19 vaccines were systematically reviewed in the study. There is also no description of vaccine-related reactivation in different times and durations. In the study by Brosh-Nissimov et al. [23], “1 week” was used to assess the vaccine-relevant virus reactivation or contained patients with skin reactions within 21 days after any dose of vaccine [23]. In examinations for BNT162b2 and mRNA-1273, Bell was palsy created in four and three vaccinated persons in compared with zero and one person, respectively, in the placebo groups [25, 26]. A middle increase (29%) in peripheral neuropathies was also seen in the Ad26.COVS vaccine cohort evaluated with placebo. In all instances, the document was inadequate to link the vaccines to these incidences. Therefore, agencies in the United States and Europe have corrected the tags of Johnson & Johnson’s Ad26. COVS and AstraZeneca’s Vaxzevria vaccines, which are both viral-vectored vaccines, mirror a growth risk of Guillain-Barré syndrome after vaccination. Therefore, supervision is needed for scarce bad events that may have not been seen or observed only sparsely during clinical examinations [27]. Generally, the neurological complications after COVID-19 vaccinations are moderate and temporary, such as fever/chills, headache, fatigue, myalgia, arthralgia, or skin manifestations such as swelling, redness, and pain. These moderate neurological signs are usual after all types of COVID-19 vaccines. Anguish-related incidences, such as impressions of syncope and/or dizziness, are typical. Other side effects included: vasculitis, anaphylaxis, seizures, Guillain-Barre syndrome, cerebral venous thrombosis, and thrombocytopenia [27, 28]. Therefore, vaccinated patients with headaches should be doubtful of cerebral venous thrombosis. Cerebral venous thrombosis is one of the severe unfavorable COVID-19 vaccine-related neurological complications [29–36] especially, after viral vector-based vaccines such as the Johnson and Johnson, and

AstraZeneca vaccines [37]. Acute disseminated encephalomyelitis (ADEM) is a sharp inflammatory demyelinating disturbance of the central neurotic system. It extends in many cases after vaccination with magnetic resonance imaging creating multiple, separate T2/FLAIR hyperintense damages in the brain. Although, the ADEM revealed after infectious in most cases [37]. Bell’s palsy frequently occurred with mRNA vaccines [38]. The acute transverse myelitis (ATM) is a local inflammatory neurotic spinal cord disturbance. The signs of ATM include rapid onset motor weakness, sensory alterations, and autonomic dysfunction. Etiology may be infectious, para-infectious, systemic autoimmune, or ischemic diseases. It can be caused by many diseases and factors such as infectious agents, systemic autoimmune, or ischemic [39, 40]. ATM may be occurred following booster dose ChAdOx1 nCoV-19 vaccination and was determined as idiopathic, short segment, spinal cord demyelination may be due to vaccination or following first dose vaccination with ChAdOx1 nCoV-19 [6, 41]. Recent research on the immune-pathogenesis of ATM has shown the effects of interleukins IL-6 and IL-17. The IL-6 is assessed in the CSF and forecast inability in the myelitis. Both IL-6 and IL-17 are increased by peripheral blood mononuclear cells in ATM [42]. IL-17 formulates cytokines (TNF α , IL-1b, and IL-6) to motivate IL-6 generated by astrocytes. Adjuvants (as helping factors to the immune and inflammatory responses to vaccines) have also been mentioned as one of the agents due to neurological complications [43]. ON the other hand, COVID-19 vaccines such as Oxford–AstraZeneca COVID-19 vaccine (AZD1222, ChAdOx1, and Vaxzevria) are viral carrier vaccines to prevent COVID-19 [44]. Román et al. confirmed the neurological manifestations after ChAdOx1 nCoV-19 vaccination [19]. Herpes Zoster (HZ) is a neurological manifestation following COVID 19 vaccines such as BNT162b2, mRNA-1273 (Pfizer BioNTech BNT162b and Moderna mRNA-1273 are mRNA vaccines with code S-protein antigens), and AZD1222 [45]. The HZ can be one of the causes of facial nerve palsy following vaccination [46]. The trigeminal ganglion is the location of VZV (varicella-zoster virus). In Ramsay–Hunt syndrome, facial nerve palsy is created by infection of the reactivated VZV of the geniculate ganglion of the facial nerve [47]. Any dermatome of cranial nerve V and spinal nerves can be affected by HZ following COVID-19 vaccination [48]. Other nervous signs after ChAdOx1 nCoV-19 vaccinations are three encephalitis. This encephalitis is associated with a memory disorder, disorder mental status, exclusion of alternative, and CSF pleocytosis (a case of seizures without prior epilepsy) [49]. Usually, vaccinations can create a strong statement of inflammatory cytokines and a T-cell reaction.

Table 1: The reviewed studies in this study.

No	Authors	Title	Year	No. patient	Type study	Result	Complication	Type vaccine	Dose
1	Gustavo C. Román et al. [19]	Acute transverse myelitis (ATM): clinical review of 43 patients with COVID-19-associated ATM and 3 post-vaccination ATM serious adverse events with the ChAdOx1 nCoV-19 vaccine (AZD1222)	2021	3	Clinical review	These three cases manifestations terminated for a short time stopping the vaccine trial till the infected participants started to show signs of recovery.	Acute transverse myelitis	The ChAdOx1 nCoV-19 vaccine (AZD1222)	Booster
2	Frédéric Zuhorn et al. [20]	Postvaccinal encephalitis after ChAdOx1 nCoV-19	2021	3	Case report	Temporal association between ChAdOx1 nCoV-19 vaccination and the presentation of encephalitis	Deep vein thrombosis in her left leg, a vigilance disorder and a twitching, a severe immobilizing opsoclonus myoclonus syndrome, encephalitis	ChAdOx1 nCoV-19	1
3	Waheed et al. [16]	Neurological complications of COVID-19: Guillain-Barre syndrome following Pfizer COVID-19 vaccine	2021	1	Case report	A weak pinprick in bilateral lower extremities up to the knees, and areflexia in both upper and lower extremities	Body aches, paresthesia, and difficulty walking.	Pfizer	1
4	Marc E. Wolf et al. [21]	Thrombocytopenia and intracranial venous sinus thrombosis after “COVID-19 Vaccine AstraZeneca” Exposure	2021	3	Case report	Elevated levels of D-dimers, platelet factor 4 antiplatelet antibodies, corona spike protein antibodies, combined with thrombocytopenia	Headaches, a generalized epileptic seizure, hemianopia, and mild aphasia, acute somnolence and right-hand hemiparesis	AstraZeneca	1
5	Apoorv Prasad et al. [22]	A novel case of bifacial diplegia variant of Guillain-Barré syndrome following Janssen COVID-19 vaccination	2021	1	Case report	MRI L spine with contrast showed thickening of cauda equina nerve roots	Urinary retention difficulty feeding and ambulating, arm soreness, mild fatigue, and chills, left-sided facial droop	Janssen	1
6	Sophie C. Queler, BA, et al. [24]	Parsonage-turner syndrome following COVID-19 vaccination	2022	2	Case report	At 3-month follow-up after onset, the patient reported no residual pain but increased weakness. His range of motion and strength subjectively improved but did not return to baseline levels.	Pfizer-BioNTech : severe, electric, shooting pain in his left, moderna : an erythema migrans lesion, fatigue, and myalgias, sudden-onset, intense, cramping pain in the left lateral deltoid region	Pfizer-BioNTech Moderna (mRNA-1273)	1

This issue was shown in the ChAdOx1 nCoV-19 vaccine [50]. After vaccination, antigens are detected as potential pathogens, like pattern-recognition receptors on local or peripheral circulating immune cells (monocytes and macrophages) and stromal cells [51]. Mediators and products of inflammation in the circulation can affect other body organs and create systemic adverse, and create neurotic manifestation in some cases after microglia activation, depending on the immunogenic background and the innate immune memory [52, 53]. These immune agents may conduct to the so-called “cytokine storm” syndrome that causes coagulopathy and thrombosis. Also, of critical value during COVID-19 are the before- and after-infectious inflammatory or immune-mediated neurological disturbances [54, 55], also observed after vaccination, that affect both the CNS and the PNS causing GBS, ADEM, NMOSD, and ATM, among others [56, 57]. In many genes occur induction and copy, causing in combination and scape of pyrogenic cytokines (interleukin [IL]-1, IL-6, tumor necrosis factor-alpha [TNF- α], and prostaglandin-E2) into the circulation that mimics the response to natural infection. After stimulation of the immune system, a complex series of innate immune events occur including, phagocytosis, release of inflammatory mediators including chemokines and cytokines, activation of complement, and cellular recruitment. The vaccine’s efficacy of the Johnson & Johnson COVID-19 vaccine is about 66.1% against symptomatic moderate and severe SARS-CoV-2 infection and about 85.4% against hospitalization or death [58]. Common complications after vaccination include injection site reactions, fever, chills, and malaise, but there are rare reports of venous thrombosis [59]. GBS, Bell’s palsy, cerebral venous sinus thrombosis, and stroke were reported after Johnson & Johnson vaccine. Side effects reactions can occur with the administration of any vaccine. Several neurological manifestations such as transverse myelitis after the COVID-19 vaccination have been reported [60–66]. Pfizer and Moderna vaccines, constructed as messenger RNA vaccines, may trigger an autoimmune response, leading to the construction of antibodies against the myelin sheath [16]. Prasad et al. reported Guillain–Barre Syndrome after Janssen COVID-19 Vaccination and confirmed manifestation’s neurological after Janssen COVID-19 Vaccination [22].

5 Conclusions

After accepting COVID-19 vaccinates, a large spectrum of severe neurological unfavorable has been reported. One of the neurological complications is Bell’s palsy which was

reported after the mRNA vaccine. Additional severe unexpected complications include transverse myelitis, acute disseminated encephalomyelitis, and Guillain–Barre syndrome. These complications could occur as a result of molecular stimulation and later neuronal damage. Neurologists should be aware of the complications of COVID-19 vaccines and keep in mind their effects on CNS diseases. This knowledge helps physicians and neurologists to better diagnose and identification of vaccine-related adverse events, thereby facilitating improved management and treatment of these complications.

Generally, the advantages of COVID-19 vaccination are dominant on the risks of a neurological complication at both individual and population levels. Future investigations will be required to find any relationship between neurological complications and COVID-19 vaccines principally as new strains of the virus and new vaccines are technologically advanced against them.

Author contributions: All the authors have accepted responsibility for the entire content of this submitted manuscript and approved submission.

Research funding: None declared.

Conflict of interest statement: The authors declare no conflicts of interest regarding this article.

References

1. Lu H, Stratton CW, Tang YW. Outbreak of pneumonia of unknown etiology in Wuhan, China: the mystery and the miracle. *J Med Virol* 2020;92:401–2.
2. Espinosa PS, Rizvi Z, Sharma P, Hindi F, Filatov A. Neurological complications of coronavirus disease (COVID- 19): encephalopathy, MRI brain and cerebrospinal fluid findings: case 2. *Cureus* 2020;12:e7930.
3. Mintoff D, Pisani D, Betts A, Scerri L. SARS-CoV-2 mRNA vaccine-associated fixed drug eruption. *J Eur Acad Dermatol Venereol* 2021;35:e560.
4. Sinha A, Kumar R, Raj Singh A. Implication of mass COVID-19 vaccination on dermatology practice in 2021. *Dermatol Ther* 2021; 34:e14765.
5. Allen A, Szabo L, Kaiser Health News. NIH “very concerned” about serious side effect in coronavirus vaccine trial [Internet]. *Scientific American*; 2020. Available from: <https://www.scientificamerican.com/article/nih-very-concerned-about-serious-side-effect-in-coronavirus-vaccine-trial/> [Accessed 27 Feb 2021].
6. Voysey M, Clemens SAC, Madhi SA, Weckx LY, Folegatti PM, Aley PK, et al. Safety and efficacy of the ChAdOx1 nCoV-19 vaccine (AZD1222) against SARS-CoV-2: an interim analysis of four randomised controlled trials in Brazil, South Africa, and the UK. *Lancet* 2021;397:99–111.
7. Ledford H. US authorization of first COVID vaccine marks new phase in safety monitoring. *Nature* 2020;588:377–8.

8. CDC. COVID-19 vaccination considerations for persons with underlying medical conditions [Internet]. Centers for Disease Control and Prevention; 2021. Available from: <https://www.cdc.gov/coronavirus/2019-ncov/vaccines/recommendations/underlying-conditions.html> [Accessed 11 Mar 2021].
9. Keddie S, Pakpoor J, Mousele C, Pipis M, Machado PM, Foster M, et al. Epidemiological and cohort study finds no association between COVID-19 and Guillain-Barré syndrome. *Brain* 2021; 144:682–93.
10. Gee J. First month of COVID-19 vaccine safety monitoring United States December 14 2020 – January 13 2021 [Internet]. *MMWR Morb Mortal Wkly Rep* 2021;70:283–8.
11. IDSA COVID-19 Real Time Learning Network Editorial Staff. COVID-19 real-time learning network: vaccines FAQ. [Internet]; 2021. Available from: <https://www.idsociety.org/covid-19-real-time-learning-network/vaccines/vaccines-information-faq/> [Accessed 27 February 2021].
12. Ciotti JR, Valtcheva MV, Cross AH. Effects of MS disease-modifying therapies on responses to vaccinations: a review. *Mult Scler Relat Disord* 2020;45:102439.
13. Achiron A, Mandel M, Dreyer-Alster S, Harari G, Magalashvili D, Sonis P, et al. Humoral immune response to COVID-19 mRNA vaccine in patients with multiple sclerosis treated with high-efficacy disease-modifying therapies. *Ther Adv Neurol Disord* 2021;14:17562864211012835.
14. World Health Organization. Draft landscape and tracker of COVID-19 candidate vaccines. 2020. <https://www.who.int/publications/m/item/draft-landscape-of-covid-19-candidate-vaccines>.
15. Ramasamy M, Minassian AM. Safety and immunogenicity of ChAdOx1 nCoV-19 (AZD1222) vaccine administered in a prime-boost regimen in older adults (COV002): a phase 2/3 single blind, randomised controlled trial. *Lancet* 2021;396:1941–2084.
16. Waheed S, Bayas A, Hindi F, Rizvi Z, Espinosa PS. Neurological complications of COVID-19: guillain-Barre syndrome following Pfizer COVID-19 vaccine. *Cureus* 2021;13:e13426–30.
17. Sønderskov KM, Dinesen PT, Østergaard SD. Sustained COVID-19 vaccine willingness after safety concerns over the Oxford-AstraZeneca vaccine. *Dan Med J* 2021;68:A03210292.
18. MacNeil JR, Su JR, Broder KR, Guh AY, Gargano JW, Wallace M, et al. Updated recommendations from the Advisory Committee on Immunization Practices for use of the Janssen (Johnson & Johnson) COVID-19 vaccine after reports of thrombosis with thrombocytopenia syndrome among vaccine recipients—United States, April 2021. *Morb Mortal Wkly Rep* 2021;70:651.
19. Román GC, Gracia F, Torres A, Palacios A, Gracia K, Harris D. Acute transverse myelitis (ATM): clinical review of 43 patients with COVID-19-associated ATM and 3 post-vaccination ATM serious adverse events with the ChAdOx1 nCoV-19 vaccine (AZD1222). *Front Immunol* 2021;12:879.
20. Zuhorn F, Graf T, Klingebiel R, Schäbitz WR, Rogalewski A. Postvaccinal encephalitis after ChAdOx1 nCoV-19. *Ann Neurol* 2021;90:506–11.
21. Wolf ME, Luz B, Niehaus L, Bhogal P, Bänzner H, Henkes H. Thrombocytopenia and intracranial venous sinus thrombosis after “COVID-19 vaccine AstraZeneca” exposure. *J Clin Med* 2021; 10:1599.
22. Prasad A, Hurlburt G, Podury S, Tandon M, Kingree S, Sriwastava S. A novel case of bifacial diplegia variant of guillain-Barré syndrome following Janssen COVID-19 vaccination. *Neurol Int* 2021;13:404–9.
23. Brosh-Nissimov T, Sorek N, Yeshayahu M, Zherebovich I, Elmaliach M, Cahan A, et al. Oropharyngeal shedding of herpesviruses before and after BNT162b2 mRNA vaccination against COVID-19. *Vaccine* 2021;39:5729–31.
24. Garg I, Shekhar R, Sheikh AB, Pal S. COVID-19 vaccine in pregnant and lactating women: a review of existing evidence and practice guidelines. *Infect Dis Rep* 2021;13:685–99.
25. Queler SC, Towbin AJ, Milani C, Whang J, Sneag DB. Parsonage-Turner syndrome following COVID-19 vaccination: MR neurography. *Radiology* 2022;302:84–7.
26. FDA News Release. Coronavirus (COVID-19) Update: July 13, 2021. Available from: <https://www.fda.gov/news-events/press-announcements/coronavirus-covid-19-update-july-13-2021>. [Accessed 13 July 2021].
27. Hause AM, Gee J, Johnson T, Jazwa A, Marquez P, Miller E, et al. Anxiety-related adverse event clusters after Janssen COVID-19 vaccination—five US mass vaccination sites, April 2021. *CDC* 2021;70:685–8.
28. Bhandari B, Rayamajhi G, Lamichhane P, Shenoy AK. Adverse events following immunization with COVID-19 vaccines: a narrative review. *Biomed Res Int* 2022.
29. World Health Organization. MODULE 3: Adverse events following immunization MODULE 3 Adverse events following immunization nd. Available from: https://www.who.int/vaccine_safety/initiative/tech_support. Part-3. pdf.
30. Castelli GP, Pognani C, Sozzi C, Franchini M, Vivona L. Cerebral venous sinus thrombosis associated with thrombocytopenia post-vaccination for COVID-19. *Crit Care* 2021;25:1–2.
31. Clark RT, Johnson L, Billotti J, Foulds G, Ketels T, Heard K, et al. Early outcomes of bivalirudin therapy for thrombotic thrombocytopenia and cerebral venous sinus thrombosis after Ad26. COV2. S vaccination. *Ann Emerg Med* 2021;78:511–4.
32. Ryan E, Benjamin D, McDonald I, Barrett A, McHugh J, Ryan K, et al. AZD1222 vaccine-related coagulopathy and thrombocytopenia without thrombosis in a young female. *Br J Haematol* 2021;194:547–56.
33. George G, Friedman KD, Curtis BR, Lind SE. Successful treatment of thrombotic thrombocytopenia with cerebral sinus venous thrombosis following Ad26. COV2. S vaccination. *Am J Hematol* 2021;96:E301–3.
34. Gattringer T, Gressenberger P, Gary T, Wölfler A, Kneihsl M, Raggam RB. Successful management of vaccine-induced immune thrombotic thrombocytopenia-related cerebral sinus venous thrombosis after ChAdOx1 nCoV-19 vaccination. *Stroke Vasc Neurol* 2021;7:e001142.
35. Varona JF, García-Isidro M, Moeinvaziri M, Ramos-López M, Fernández-Domínguez M. Primary adrenal insufficiency associated with Oxford-AstraZeneca ChAdOx1 nCoV-19 vaccine-induced immune thrombotic thrombocytopenia (VITT). *Eur J Intern Med* 2021;91:90–2.
36. Pottegård A, Lund LC, Karlstad Ø, Dahl J, Andersen M, Hallas J, et al. Arterial events, venous thromboembolism, thrombocytopenia, and bleeding after vaccination with Oxford-AstraZeneca ChAdOx1-S in Denmark and Norway: population based cohort study. *Bmj* 2021;373:n1114–24.
37. Krzywicka K, Heldner MR, Sánchez van Kammen M, van Haaps T, Hiltunen S, Silvis SM, et al. Post-SARS-CoV-2-vaccination cerebral

- venous sinus thrombosis: an analysis of cases notified to the European Medicines Agency. *Eur J Neurol* 2021;28:3656–62.
38. Mehta PR, Mangion SA, Benger M, Stanton BR, Czuprynska J, Arya R, et al. Cerebral venous sinus thrombosis and thrombocytopenia after COVID-19 vaccination—A report of two UK cases. *Brain Behav Immun* 2021;95:514–7.
 39. Cao L, Ren L. Acute disseminated encephalomyelitis after severe acute respiratory syndrome coronavirus 2 vaccination: a case report. *Acta Neurol Belg* 2021;122:793–5.
 40. Ozonoff A, Nanishi E, Levy O. Bell's palsy and SARS-CoV-2 vaccines—an unfolding story—Authors' reply. *Lancet Infect Dis* 2021;21:1211–2.
 41. Águila-Gordo D, Flores-Barragán JM, Ferragut-Lloret F, Portela-Gutierrez J, LaRosa-Salas B, Porras-Leal L, et al. Acute myelitis and SARS-CoV-2 infection. A new etiology of myelitis? *J Clin Neurosci* 2020;80:280–1.
 42. GÜLER MA, Keskin F, Hüseyin TA. Acute myelitis secondary to COVID-19 in an adolescent: causality or coincidence? *New Trend Med Sci* 2020;1:132–6.
 43. Knoll MD, Wonodi C. Oxford—AstraZeneca COVID-19 vaccine efficacy. *Lancet* 2021;397:72–4.
 44. Graber JJ, Allie SR, Mullen KM, Jones MV, Wang T, Krishnan C, et al. Interleukin-17 in transverse myelitis and multiple sclerosis. *J Neuroimmunol* 2008;196:124–32.
 45. Vera-Lastra O, Medina G, Cruz-Dominguez MD, Jara LJ, Shoenfeld Y. Autoimmune/inflammatory syndrome induced by adjuvants (Shoenfeld's syndrome): clinical and immunological spectrum. *Expet Rev Clin Immunol* 2013;9:361–73.
 46. Sotoca J, Rodríguez-Álvarez Y. COVID-19-associated acute necrotizing myelitis. *Neurol Neuroimmunol NeuroIn* 2020;7. <https://doi.org/10.1212/nxi.0000000000000803>.
 47. Chakaya J, Khan M, Ntoumi F, Aklillu E, Fatima R, Mwaba P, et al. Global tuberculosis report 2020—reflections on the global TB burden, treatment and prevention efforts. *Int J Infect Dis* 2021; 113:57–12.
 48. Peitersen E. Bell's palsy: the spontaneous course of 2, 500 peripheral facial nerve palsies of different etiologies. *Acta Otolaryngol* 2002;122:4–30.
 49. Kempf W, Meylan P, Gerber S, Aebi C, Agosti R, Büchner S, et al. Swiss recommendations for the management of varicella zoster virus infections. *Swiss medical weekly* 2007;137:239–51.
 50. Santosh AB, Muddana K. Viral infections of oral cavity. *J Fam Med Prim Care* 2020;9:36.
 51. Lapenna F, Lochi L, De Mari M, Iliceto G, Lamberti P. Post-vaccinic opsoclonus—myoclonus syndrome: a case report. *Park Relat Disord* 2000;6:241–2.
 52. Ewer KJ, Barrett JR, Belij-Rammerstorfer S, Sharpe H, Makinson R, Morter R, et al. T cell and antibody responses induced by a single dose of ChAdOx1 nCoV-19 (AZD1222) vaccine in a phase 1/2 clinical trial. *Nat Med* 2021;27:270–8.
 53. Hervé C, Laupèze B, Del Giudice G, Didierlaurent AM, Tavares Da Silva F. The how's and what's of vaccine reactogenicity. *Npj Vaccines* 2019;4:1.
 54. Mehta P, McAuley DF, Brown M, Sanchez E, Tattersall RS, Manson JJ. COVID-19: consider cytokine storm syndromes and immunosuppression. *The lancet* 2020;395:1033–4.
 55. Blackburn KM, Wang C. Post-infectious neurological disorders. *Therap Adv Neurol Dis* 2020;13:1–17.
 56. Boziki MK, Mentis A-FA, Shumilina M, Makshakov G, Evdoshenko E, Grigoriadis N. COVID-19 immunopathology and the central nervous system: implications for multiple sclerosis and other autoimmune diseases with associated demyelination. *Brain Sci* 2020;10:345.
 57. Poser CM, Román GC, Emery ES 3rd. Recurrent disseminated vasculomyelinopathy. *Arch Neurol* 1978;35:166–70.
 58. Mancera-Páez O, Román GC, Pardo-Turriago R, Rodríguez Y, Anaya JM. Concurrent Guillain-Barré syndrome, transverse myelitis and encephalitis postZika: a case report and review of the pathogenic role of multiple arboviral immunity. *J Neurol Sci* 2018;395:47–53.
 59. Sharifian-Dorche M, Bahmanyar M, Sharifian-Dorche A, Mohammadi P, Nomovi M, Mowla A. Vaccine-induced immune thrombotic thrombocytopenia and cerebral venous sinus thrombosis post COVID-19 vaccination; a systematic review. *J Neurol Sci* 2021;428:117607.
 60. MacNeil JR, Su JR, Broder KR, Guh AY, Gargano JW, Wallace M, et al. Updated recommendations from the Advisory Committee on Immunization Practices for use of the Janssen (Johnson & Johnson) COVID-19 vaccine after reports of thrombosis with thrombocytopenia syndrome among vaccine recipients—United States, April 2021. *Morb Mortal Wkly Rep* 2021;70:651.
 61. Klein NP, Lewis N, Goddard K, Fireman B, Zerbo O, Hanson KE, et al. Surveillance for adverse events after COVID-19 mRNA vaccination. *JAMA* 2021;326:1390–9.
 62. Pagenkopf C, Südmeyer M. A case of longitudinally extensive transverse myelitis following vaccination against Covid-19. *J Neuroimmunol* 2021;358:577606.
 63. Gao JJ, Tseng HP, Lin CL, Shiu JS, Lee MH, Liu CH. Acute transverse myelitis following COVID-19 vaccination. *Vaccines* 2021;9:1008.
 64. Notghi AA, Atley J, Silva M. Lessons of the month 1: longitudinal extensive transverse myelitis following AstraZeneca COVID-19 vaccination. *Clin Med* 2021;21:e535.
 65. Nejad JH, Heiat M, Hosseini MJ, Allahyari F, Lashkari A, Torabi R, et al. Guillain-Barré syndrome associated with COVID-19: a case report study. *J Neurovirol* 2021;27:802–5.
 66. Rostami Z, Cegolon L, Jafari NJ, Gholami N, Mousavi SV, Allahyari F, et al. A rare case of coexistence of Wegener's granulomatosis and pulmonary tuberculosis with subsequent development of thrombosis of the cerebral veins. *BMC Infect Dis* 2021;21:1–8.