

Introduction

We recently had the opportunity to evaluate the Optos® ultra-widefield imaging device in our teaching hospital. Since installation we have been impressed by the image quality and additional value it has brought. We present below a case study demonstrating the value of Dynamic Ultra-widefield Fluorescein Angiography offered by the Optos® device in patients with Diabetic Retinopathy.

History

The patient was a 79-year-old female, with a history of moderate to severe NPDR in both eyes. She had previous focal macular laser treatment.

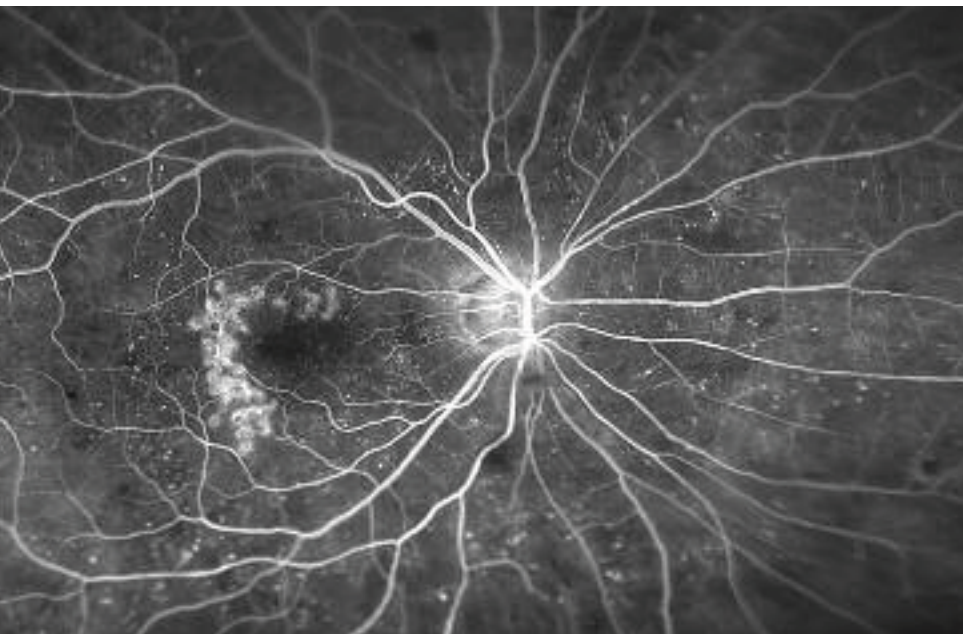Examination

The ability to see more than 80% of the retina in each image capture is clearly demonstrated. There is early evidence that a subset of patients with diabetic macular edema may have a component of peripheral nonperfusion, resulting in upregulation of VEGF and increased vascular permeability. It has been

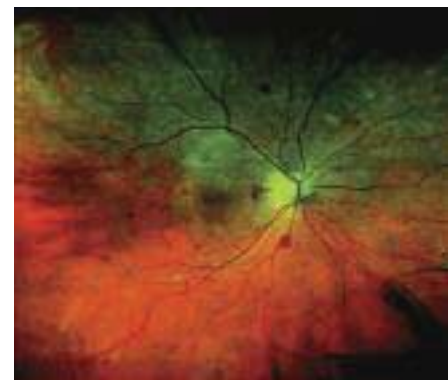
suggested that these patients may also benefit from scatter laser treatment to these areas of nonperfusion. It is worth highlighting that the resolution of the macula is excellent, allowing a clear view of the previously treated Clinically Significant Macular Edema (CSME), microaneurysms and dot hemorrhages.

Conclusion

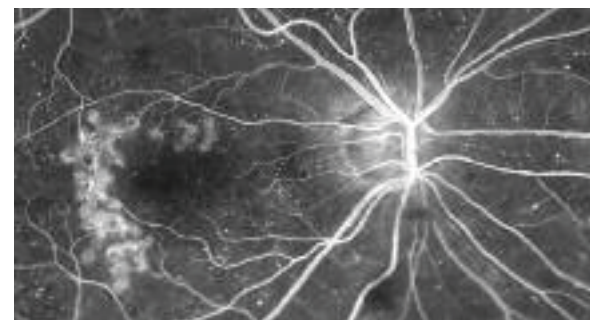Ultra-widefield fluorescein angiography aids in the simultaneous assessment of macular and peripheral retinal circulation in retinovascular condition, allowing us to more precisely classify subtypes of these conditions and guide our therapies.



optomap® fa image. Previously treated CSME, microaneurysms and peripheral hemorrhages can be clearly seen.



Ultra widefield optomap® plus image of the retina showing microaneurysms and dot & blot hemorrhages.



Magnifying the same optomap® fa image provides a detailed view of the previously treated CSME and microaneurysms.

