

# ANGIOGRAPHY VERSION 2.0

OCT angiography offers a more complete picture of the retinal and choroidal vasculature than dye-based imaging.

BY MARCO RISPOLI, MD; LUCA DI ANTONIO, MD, PhD; LEONARDO MASTROPASQUA, MD; AND BRUNO LUMBROSO, MD



Optical coherence tomography (OCT) can be used to detect and monitor fluid exudation and morphologic changes associated with vascular diseases in the posterior segment. However, structural OCT cannot directly detect capillary dropout or neovascularization, the major vascular changes associated with the leading causes of blindness—age-related macular degeneration (AMD) and diabetic retinopathy (DR).

The traditional imaging methods used in the study of normal and pathologic retinal vessels, fluorescein angiography (FA) and indocyanine green angiography (ICGA), also do not allow a precise view of neovascularization. They provide blurred images of the vascular network based on dye leakage. These imaging procedures hold a fundamental place in retinal imaging; however, their invasive nature sometimes causes patients to experience mild to serious side effects.

OCT angiography (OCTA) is a fast, easy, safe, and inexpensive option for diagnosing and monitoring a variety of retinal disorders. This article examines the use of OCTA, specifically with the AngioVue OCTA system (Optovue) in the visualization of the retinal and choroidal vasculature.

## TECHNOLOGY OVERVIEW

David Huang, MD, PhD, created the split-spectrum amplitude-decorrelation angiography (SSADA) algorithm,<sup>1</sup> which detects motion in blood vessels by measuring variations in the reflected OCT signal amplitude between consecutive cross-sectional scans and then processes it to



## AT A GLANCE

- FA and ICGA do not offer precise views of neovascularization.
- OCTA is a quick, safe, easy, and inexpensive method of diagnosing and monitoring retinal diseases.
- Better identification of nonperfused zones, capillary dropout areas, vascular dilatations and abnormalities, and neovascularization are possible with OCTA compared with classic retinal angiography.

enhance flow detection and reject axial bulk motion noise. The SSADA algorithm splits the OCT image into different spectral bands, thereby increasing the number of usable image frames and shortening the scan acquisition process. Compared with full-spectrum methods, SSADA improves

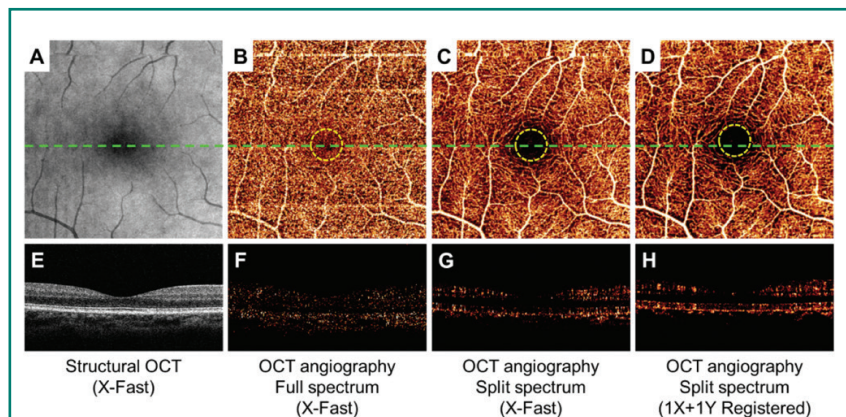
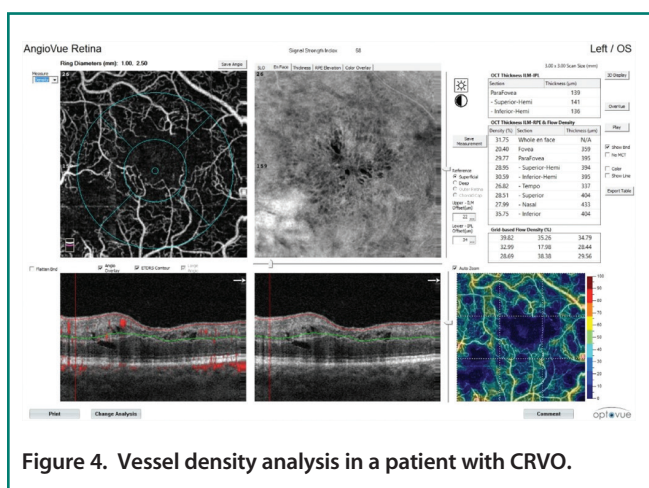
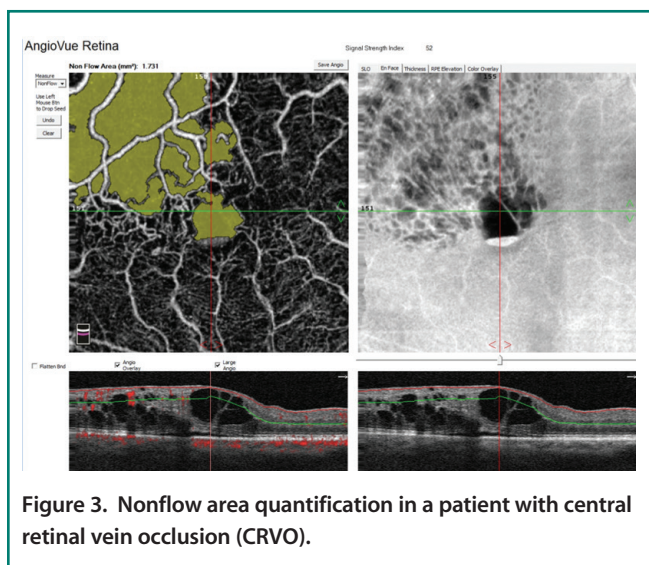
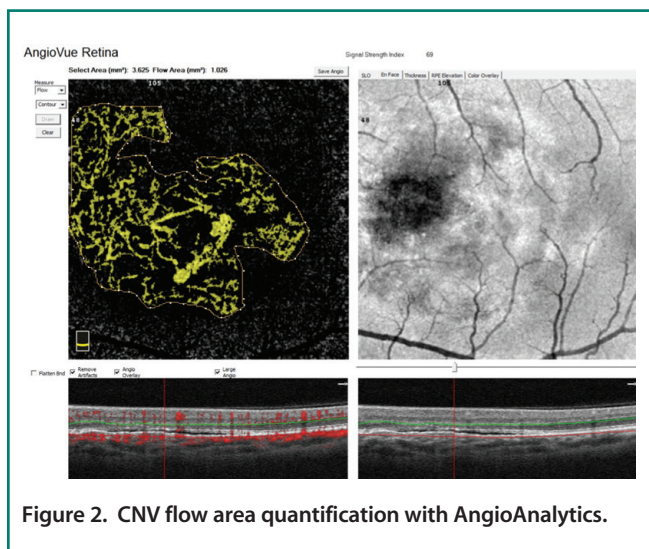


Figure 1. En face maximum decorrelation projections of retinal circulation show less noise inside the FAZ (within yellow dotted circles) and more continuous perifoveal vascular networks using the SSADA algorithm (C and D) compared with standard full-spectrum algorithm (B). The cross-sectional angiograms (scanned across the green dashed line in B, C, and D) show more clearly delineated retinal vessels and less noise using the SSADA algorithm (G and H) than the standard full-spectrum algorithm (F).



the signal-to-noise (SNR) ratio to provide clean and continuous imaging of the microvascular network with less noise inside the foveal avascular zone (FAZ) (Figure 1).

The AngioVue OCTA system uses the SSADA algorithm and incorporates other technological innovations, including DualTrac Motion Correction, which provides two levels of motion correction. The first level, real-time tracking, removes large artifacts such as those that occur when a patient blinks. The second level, performed in the image postprocessing phase, is a pixel-level correction for small eye motions such as saccades. With this combination, SNR and overall image quality are improved, particularly in distinct small retinal vessels. Image quality is further improved by proprietary software that detects projection artifacts and automatically removes ghost images of superficial capillary plexus vessels projected onto deeper retinal layers.

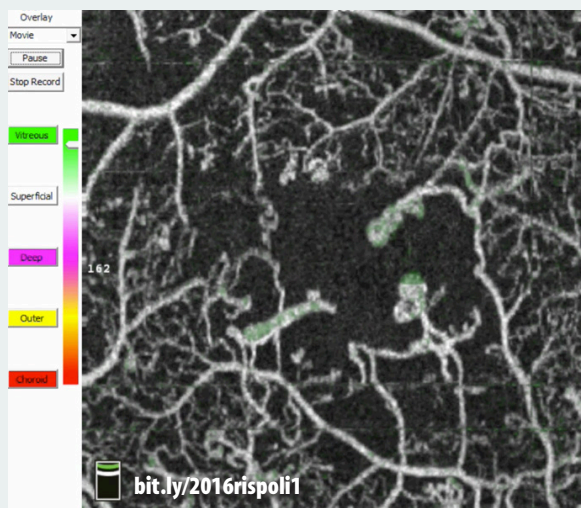
### Quantitative Analysis

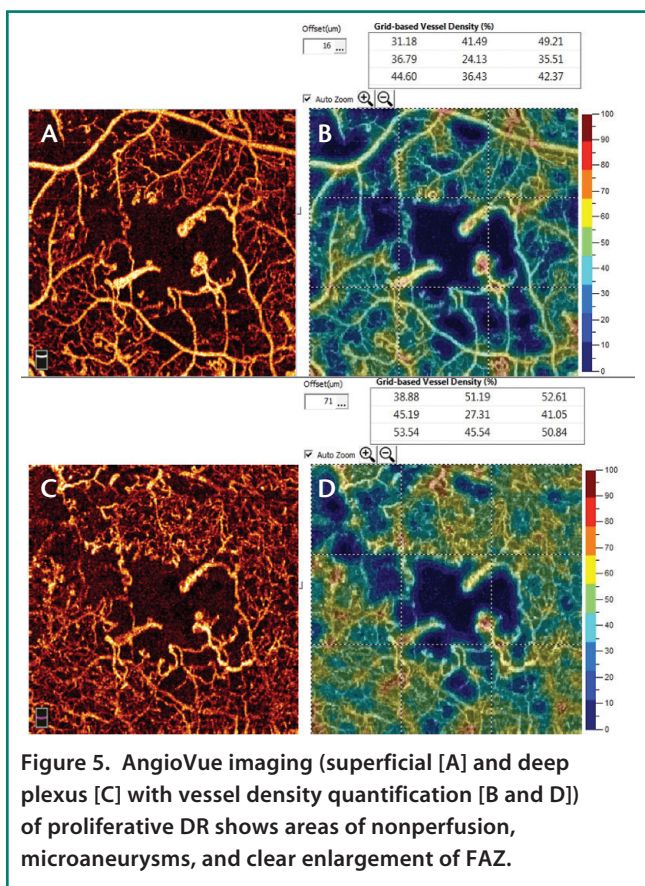
A helpful step for everyday clinical applications of OCTA has been the development of AngioAnalytics (Optovue), software that provides numerical data about flow area, nonflow area, and vessel density. The flow area measurement tool is useful in the follow-up of choroidal neovascularization (CNV). The operator simply draws the CNV boundary, and the software then calculates the

## WATCH IT NOW

### Video 1. Features of PDR

This video highlights features of PDR by segmenting the macula layer by layer.





**Figure 5.** AngioVue imaging (superficial [A] and deep plexus [C]) with vessel density quantification [B and D] of proliferative DR shows areas of nonperfusion, microaneurysms, and clear enlargement of FAZ.

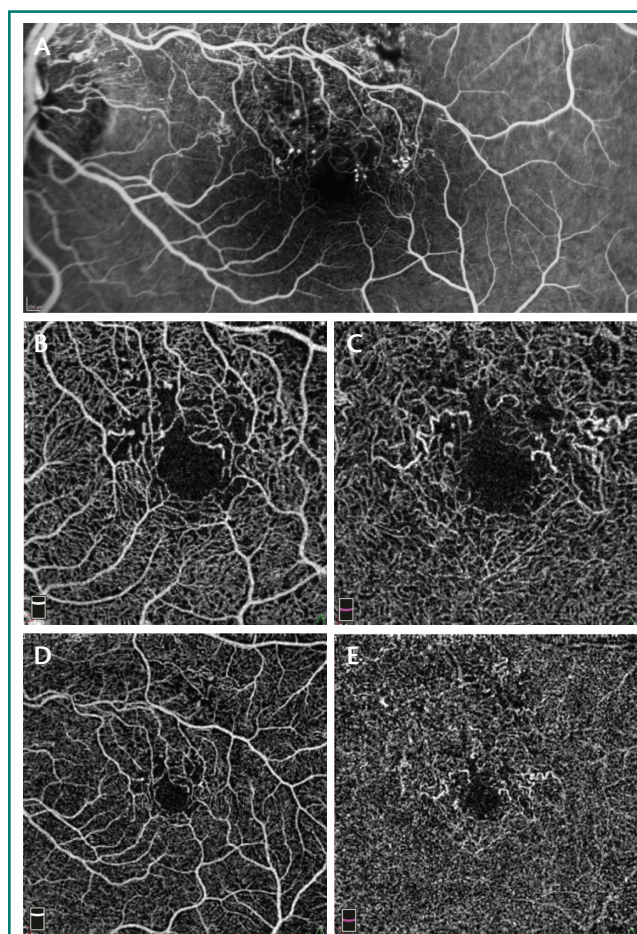
size of the drawn area and vessel area in square millimeters (Figure 2). The nonflow area tool allows clinicians to highlight and monitor the FAZ as well as nonperfused areas in ischemic retinopathies such as DR and retinal vein occlusions (Figure 3). Finally, the vessel density tool automatically calculates the percentage of flow versus nonflow area in an ETDRS grid centered on the macula and in a color-coded vessel density map divided into nine sectors (Figure 4).

### IMAGING RETINAL DISORDERS

OCTA produces 3-D images of the retinal and chorioidal microvasculature, allowing the user to view each layer separately to determine quickly and precisely from which layer pathology originates. Below is a rundown of some of the disease states in which OCTA can be a helpful tool.

#### Diabetic Retinopathy

In patients with DR, OCTA demonstrates retinal alterations including capillary dropout in the superficial and deep plexuses, FAZ enlargement, and microaneurysms (Figure 5). The ability to separately examine the superficial and deep capillary plexuses with OCTA helps



**Figure 6.** FA (A) and 3 mm x 3 mm (B) and 6 mm x 6 mm (D) superficial plexus OCTA of a 47-year-old man with ischemic BRVO show rarefaction of capillary texture, microaneurysms, and capillary dropout. By contrast, 3 mm x 3 mm (C) and 6 mm x 6 mm (E) deep plexus OCTA show capillary dilation and vessel congestion, probably due to high hydrostatic pressure. These features are not visible on FA.

users to delineate retinal involvement in various diabetic lesions (Video 1). For instance, widening of the FAZ is best seen in the superficial plexus, whereas capillary dropout and microaneurysms are best appreciated in the deep plexus. However, microaneurysms are visible on OCTA only in the presence of intravascular flow; therefore, those with slow flow or thrombosis will remain undetected. The detection of preretinal and prepapillary neovascularization is also facilitated with OCTA, as these new vessels are not blurred by leakage in dye-based angiography.

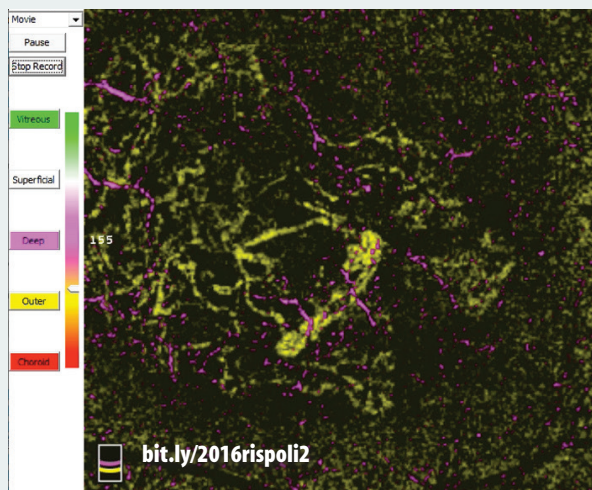
#### Retinal Vein Occlusion

OCTA highlights four important features of branch retinal vein occlusion (BRVO): FAZ enlargement, capillary dropout, microvascular abnormalities, and vascular congestion.

## WATCH IT NOW

### Video 2. Where's the CNV?


Segmentation of the macula layer by layer allows the surgeon to identify new vessels in the avascular zone.



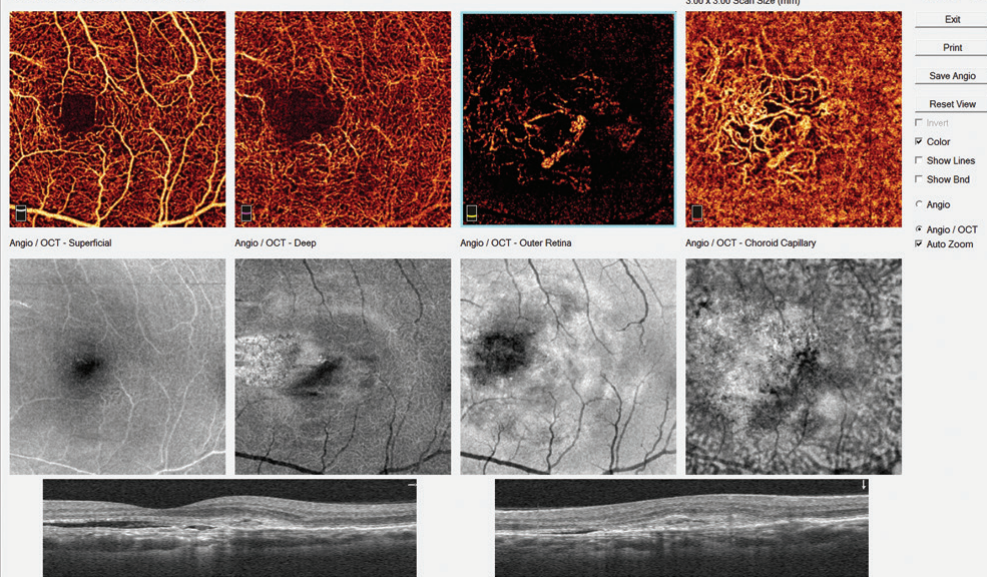
## WATCH IT NOW

### Video 3. A Better Appreciation of CNV

In this video, cystic black spaces seen in the deep capillary complex represent cystoid macular edema (CME) secondary to the exudative process. Both type 1 and type 2 CNV can also be seen.



#### Angio Structure-Function



**Figure 7.** Typical AngioVue report in type 1 CNV. The cross-sectional OCT shows irregular subretinal fluid with thickened photoreceptor outer segments. Hyperreflective material is evident at the fluid site with irregular retinal pigment epithelium. OCTA shows normal texture of the vascular retina (superficial and deep capillary plexuses). A large, irregular neovascular network is evident in the choriocapillaris layer.

Through our clinical experience with superficial and deep networks we have found that, unlike FA, OCTA allows in-depth study of vascular changes in vein occlusions. Changes in the structure of the superficial network can be observed in patients with macular ischemia. Occlusions are evident in the study of the superficial plexus and slightly less evident in the deep network. However, the demarcation of nonflow areas is more obvious in the superficial plexus. Additionally, arteriovenous anastomoses and vascular loops are easily observed.

## OPTIONS IN OCTA

### By the staff of *Retina Today*

The AngioVue OCTA system (Optovue) described in this article and the RS-3000 Advance OCT system used with Angioscan OCTA software (Nidek) described by Manish Nagpal, MD, DO, FRCS(Edin), in his article starting on page 57 are cleared by the US Food and Drug Administration (FDA) and are commercially available in most countries. These are not the only options for optical coherence tomography angiography (OCTA). At least two other companies have systems available in some markets.

AngioPlex OCT Angiography (Zeiss Medical Technology) is available on the Cirrus 5000 HD-OCT platform; the device's Fastrac software provides live tracking for motion-artifact-free images. AngioPlex requires a single additional OCT scan to generate a clear 3-D OCTA image. The AngioPlex can illustrate the presence of microaneurysms and areas of ischemia in patients with diabetic retinopathy, illustrate the presence of choroidal neovascularization in patients with age-related macular degeneration, and clearly delineate the location of occlusion and affected areas of

ischemia superior to the optic nerve head in patients with branch retinal vein occlusion. The AngioPlex was cleared by the FDA in September 2015.

For users outside the United States, the Spectralis imaging platform (Heidelberg Engineering) can be upgraded with the OCT Angiography Module to perform noninvasive, layer-by-layer examinations of flow in the vascular networks of the retina and choroid. The OCT Angiography Module also benefits from TruTrack Active Eye Tracking, which avoids motion artifacts and ensures high-resolution images. The Spectralis platform offers a hybrid approach to angiography with its combination of noninvasive OCTA and dye-based fluorescein angiography (FA) or indocyanine green angiography (ICGA) scanning laser angiography. This enables OCTA images to be directly correlated pixel to pixel with FA or ICGA. Additionally, a scan planning tool automates OCTA scan placement on a region of interest identified on FA or ICGA or any other previously acquired confocal scanning laser ophthalmoscope image.

### Case Example

We performed FA (Figure 6A) and OCTA of the superficial plexus (Figure 6B and 6D) in a 47-year-old man with ischemic BRVO. Both imaging modalities showed rarefaction of capillary texture, microaneurysms, and capillary dropout. OCTA of the deep plexus (Figure 6C and 6E) showed capillary dilation and vessel congestion, likely due to high hydrostatic pressure. These features were not visible on FA.

### Age-Related Macular Degeneration

In type 1 CNV secondary to AMD (Figure 7), the new vessels initially appear under the pigment epithelium, and no flow is seen in the avascular outer retina. The neovascular network is often extensive, with high flow and varied morphology (Video 2). New vessels may appear in a variety of shapes, including a medusa head, coral reef, bicycle wheel, fan, and dead tree. The tangled network generally contains filaments, loops, and a vascular arcade. The vascular complex almost always has a feeder trunk or a bundle of feeder vessels.

In type 2 CNV (Figure 8) new vessels are always located above the retinal pigment epithelium, but they also spread deeply into the outer retinal avascular area. The flow is high; however, the morphology is less varied than in type 1

(Continued on page 82)

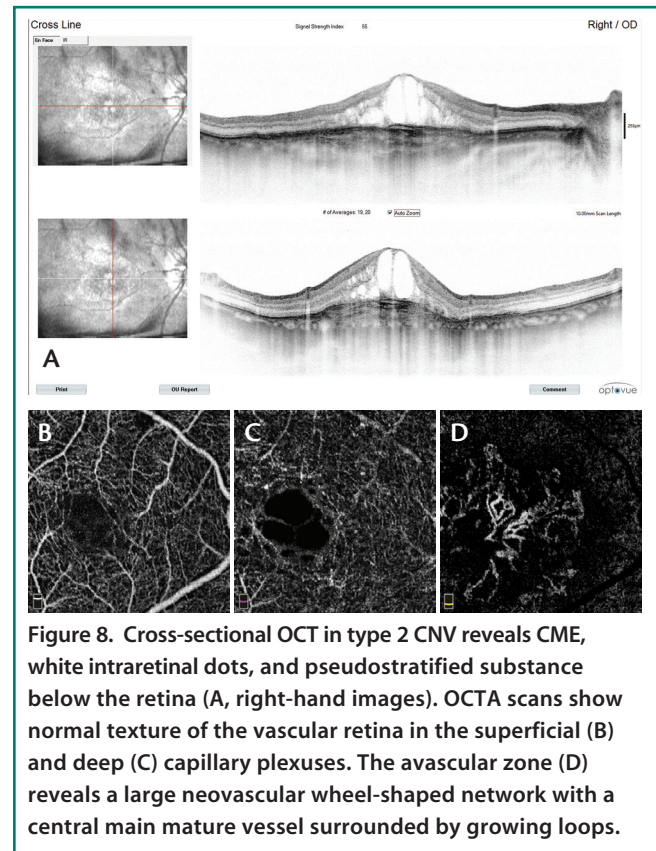


Figure 8. Cross-sectional OCT in type 2 CNV reveals CME, white intraretinal dots, and pseudostratified substance below the retina (A, right-hand images). OCTA scans show normal texture of the vascular retina in the superficial (B) and deep (C) capillary plexuses. The avascular zone (D) reveals a large neovascular wheel-shaped network with a central main mature vessel surrounded by growing loops.

(Continued from page 78)

CNV, with the morphology most frequently appearing as bicycle wheel or fan-like shapes (Video 3). The neovascular network area is smaller than in type 1 CNV.

## CONCLUSION

Patient examination with the AngioVue OCTA system is easier and faster than with FA or ICGA. Image acquisition takes less than 6 seconds, and image processing adds only a few additional seconds. Furthermore, the AngioAnalytics software enables improved clinical assessment of vascular retinal diseases by providing reliable and reproducible quantitative analysis.

OCTA is an important improvement over classic dye-based angiography, as it enables better identification of nonperfused zones, capillary dropout areas, vascular dilatations and abnormalities, and neovascularization. It is possible that OCTA will soon hold a more prominent role in the scientific and clinical examination of vascular retinal diseases, replacing the use of FA and ICGA in many clinical conditions. ■

1. Study shows new technology may improve management of leading causes of blindness [press release]. Portland, OR: Oregon Health & Sciences University; April 20, 2015.

### Luca Di Antonio, MD, PhD

- retina consultant for the Ophthalmology Department Center of Excellence, National Hightech Center and Italian School of Robotic Surgery in Ophthalmology University "G d'Annunzio" of Chieti-Pescara, Italy
- financial interest: none acknowledged
- monsieurluca@yahoo.com

### Bruno Lumbroso, MD

- director, Centro Oftalmologico Mediterraneo, Roma, Italy
- financial disclosure: consultant to Optovue
- bruno.lumbroso@gmail.com

### Leonardo Mastropasqua, MD

- full professor of ophthalmology, head of the ophthalmology department, and head of the Center of Excellence at National High-tech Center and Italian School of Robotic Surgery in Ophthalmology University "G d'Annunzio" of Chieti-Pescara, Italy; president of the Italian Council of University Professors in Ophthalmology; and president of the Italian Society of University Ophthalmologists
- financial interest: none acknowledged
- mastropa@unich.it

### Marco Rispoli, MD

- retina consultant at Centro Oftalmologico Mediterraneo Clinic and at Medical Retina Department of Nuovo Regina Margherita Hospital, both in Rome, Italy
- financial disclosure: consultant to Optovue
- rispolimarco@gmail.com