

# The Royal College of Paediatrics and Child Health and The Royal College of Ophthalmologists



## Abusive Head Trauma and the Eye in Infancy

June 2013

Scientific Department  
The Royal College of Ophthalmologists  
17 Cornwall Terrace  
Regent's Park  
London NW1 4QW  
Telephone: 020 7935 0702  
Facsimile: 020 7487 4674  
[www.rcophth.ac.uk](http://www.rcophth.ac.uk)

© The Royal College of Ophthalmologists 2013 All rights reserved  
For permission to reproduce any of the content contained herein please contact [events@rcophth.ac.uk](mailto:events@rcophth.ac.uk)

## **Executive Summary**

A child suspected of abusive head injury is referred by paediatricians to an ophthalmologist for evaluation. The incidence of abusive head injury in children is highest in infancy and less frequently seen in children over 3 years of age. Retinal haemorrhages have a high positive predictive rate for abusive head injury. In the presence of head injury without any plausible medical explanation the description of the retinal findings help in distinguishing between abusive injury and other causes. It is incumbent on the ophthalmologist to be familiar with clinical presentation, the differential diagnosis and controversies associated with attributing the presence or absence of retinal findings to abusive head injury in children.

The guidance was developed by a guideline working party (GWP) from the Royal College of Ophthalmologists (RCO) and the Royal College of Paediatrics and Child Health (RCPCH). It brings together previous publications of the RCO and an update of the literature since these publications.

The evidence underpinning the guidance is based on the hierarchy of levels of medical evidence and is graded according to the Scottish Intercollegiate guideline network. In addition, there are good practice points under the chapter guidance for the ophthalmologist.

The guidance is presented under a number of clinically relevant questions developed by the GWP. It is divided into four main chapters: 1. Aetiological factors and experimental models, 2. Clinical features and pathology. 3. Differential diagnosis and confounding conditions and 4. Guidance for the Ophthalmologist.

The guidance includes a standardised proforma for documenting retinal findings in [Appendix 3](#).

The guidance has primarily been developed for ophthalmologists but is an evidence based resource for any physician or surgeon involved in child protection.

The document with its appendices is available on the websites of the Royal College of Ophthalmologists ([www.rcophth.ac.uk](http://www.rcophth.ac.uk)) and the Royal College of Paediatrics and Child Health ([www.rcpch.ac.uk](http://www.rcpch.ac.uk)).

## Table of Contents

Executive Summary.....	2
Table of Contents .....	4
Abbreviations .....	6
Guideline Working Party (GWP) .....	7
Acknowledgements .....	8
1. INTRODUCTION.....	9
1.1. Background.....	9
1.2. Terminology .....	9
1.3 Aims of the guidance.....	9
1.4 Scope of guidance.....	10
2. METHODS.....	11
2.1. Clinical Questions .....	11
2.2. Gathering evidence.....	13
2.2.1. Search strategy.....	13
2.2.2. Databases and Journals.....	13
2.2.3. Search results and data extraction .....	13
2.2.4. Levels of evidence and grades of recommendations.....	13
2.2.5. External peer review.....	15
2.2.6. Date for Review of Document.....	15
2.2.7. Facilitation and Funding.....	15
3. CLINICAL QUESTIONS AND EVIDENCE.....	16
3.1. Aetiological factors and experimental models. ....	16
3.1.1. Forces .....	16
3.1.2. Impact.....	17
3.1.3. Vigorous handling and play.....	19
3.1.4. Mechanisms.....	21
3.1.5. Hypoxia .....	27
3.1.6. Computational and biomechanical models of ocular injury in AHT ...	28
3.1.7. Animal models.....	30
3.2. Clinical features and pathology .....	31
3.2.1. Age of child at presentation.....	31
3.2.2. Characteristics of retinal findings.....	32
3.2.3. Pathology.....	46

3.3. Differential diagnosis and confounding conditions.....	49
3.3.1. Accidental injury and retinal haemorrhage .....	49
3.3.2. Other childhood conditions and retinal haemorrhage .....	52
3.3.3. Period of birth haemorrhage.....	57
3.3.4. Bleeding diathesis or blood dyscrasia .....	58
3.3.5. Confounding conditions .....	60
3.3.6. Other causes of retinal haemorrhage .....	64
3.3.7. Short distance falls .....	65
3.3.8. Raised intracranial pressure.....	68
3.3.9. Crush injury .....	69
3.4. Guidance for the Ophthalmologist .....	71
3.4.1. Imaging of the retina in AHT .....	71
3.4.2. Procedures for the ophthalmologist and documentation .....	72
APPENDICES .....	80
Appendix 1: Search Strategy .....	80
Appendix 2: Critical appraisal form .....	83
Appendix 3: Proforma for recording ophthalmology findings in suspected AHT or haemorrhagic retinopathy in children .....	84
Reference List.....	86

## Abbreviations

1. AHT Abusive head trauma
2. ALTE Apparent life threatening event
3. CAF Critical appraisal form
4. CMV Cytomegalovirus
5. CNS Central nervous system
6. CPR Cardiopulmonary resuscitation
7. CRVO Central retinal vein occlusion
8. CSF Cerebrospinal fluid
9. CT Computerised tomography
10. ECMO Extra corporeal membrane oxygenation
11. ED Emergency departments
12. GPP Good practice points
13. GWP Guideline working party
14. ICP Intracranial pressure
15. MRI Magnetic resonance imaging
16. MVA Motor vehicle accident
17. MVC Motor vehicle crashes
18. NAHI Non accidental head injury
19. NAI Non accidental Injury
20. ND Named Doctor
21. NFL Nerve fibre layer
22. NICE National institute of Clinical Excellence
23. NN Named Nurse
24. OCT Optical coherence tomography
25. ONSH Optic nerve sheath haemorrhage
26. PM Post mortem
27. RH/s Retinal haemorrhage/Retinal haemorrhages
28. RCT Randomised control trial
29. RCO Royal College of Ophthalmologists
30. RCPCH Royal College of Paediatrics and Child Health.
31. ROP Retinopathy of Prematurity
32. RPE Retinal pigment epithelium
33. SCBU Special care baby unit
34. SBS Shaken baby syndrome
35. SIGN Scottish intercollegiate guidelines network
36. SDH Subdural haemorrhage

## Guideline Working Party (GWP)

### *Chairman*

Patrick Watts, Consultant Ophthalmologist, Cardiff, Wales

### *Working Party*

Gillian Adams Consultant Ophthalmologist, Moorfields Eye Hospital  
London  
John Ainsworth Consultant Ophthalmologist, Children's Hospital,  
Birmingham  
Susmito Biswas Consultant Ophthalmologist, Children's Hospital,  
Manchester  
Richard Bonshek Consultant Pathologist, Manchester Royal Eye Hospital  
Brian Fleck Consultant Ophthalmologist, Sick Children's Hospital  
Edinburgh  
Raina Goyal Consultant Ophthalmologist, Royal Glamorgan Hospital,  
Wales  
Saurabh Jain Consultant Ophthalmologist, London  
Jane Leitch Consultant Ophthalmologist, Surrey  
Vernon Long Consultant Ophthalmologist, Leeds  
Chris Lloyd Consultant Ophthalmologist, Children's Hospital,  
Manchester  
Phil Luthert Professor of Pathology, London  
Sabine Maguire Senior lecturer, Consultant Paediatrician, University of  
Cardiff  
Alan Mulvihill Consultant Ophthalmologist, Sick Children's Hospital  
Edinburgh  
Dinesh Rathod Consultant Ophthalmologist, Carmarthen, Wales  
Ian Simmons Consultant Ophthalmologist, Leeds  
Anamika Tandon Consultant Ophthalmologist, Coventry  
David Taylor Professor of Paediatric Ophthalmology, London  
Cathy Williams Consultant Ophthalmologist, Bristol  
Geoffrey Woodruff Consultant Ophthalmologist, Leicester.  
Patrick Watts Consultant Ophthalmologist, Cardiff, Wales

### RCPCH representative

Sabine Maguire, Senior lecturer, Consultant Paediatrician, University of Cardiff.

Information specialist: Mala Mann, MInfSc, MCLIP, School of medicine, Cardiff University, Cardiff UK.

Conflicts of interest: The following members of the guideline group declare that they undertake or have undertaken paid medico legal work in child maltreatment cases: Gillian Adams, John Ainsworth, Susmito Biswas, Richard Bonshek, Jane Leitch, Vernon Long, Chris Lloyd, Phil Luthert, Alan Mulvihill, Ian Simmons, David Taylor, Geoff Woodruff and Patrick Watts

## Acknowledgements

Anthony Moore	Professor and Consultant Ophthalmologist, Head of Scientific committee, RCO.
Alison Kemp	Professor and Consultant Paediatrician, Cardiff University School of Medicine, Wales
Laura Wain	Research assistant, Department of Paediatrics, Cardiff University School of Medicine, Wales
Geoff Debelle	Consultant Paediatrician, Birmingham Children's Hospital and Birmingham Community Healthcare NHS Trust.
Angela Moore	Consultant Paediatrician, Royal Wolverhampton Hospitals NHS Trust
Rita Ranmal	Clinical Standards Manager, RCPCH
Melanie Simpson	Psychometric Analysts, RCPCH
Rosa Nieto	Clinical Standards Facilitator, RCPCH



# 1. INTRODUCTION

## 1.1. Background

Child maltreatment includes child abuse and neglect. When asked to examine children suspected of being abused, the ophthalmologist is required to document her/his findings accurately and provide an opinion on the eye signs based on the clinical presentation, systemic findings and investigations of a multidisciplinary team. The interests of the child within a family are paramount when required to present evidence in family or criminal court proceedings. There are two previous Royal College of Ophthalmologists publications in 1999 (1) and 2004 (2) providing consensus opinion of the developments in child abuse literature relevant to the ophthalmologist. This document summarizes the previous publications and provides an update based on a comprehensive literature search of pertinent literature that has not been previously considered in these documents. The Royal College Ophthalmologists (RCO) document on procedures for the ophthalmologist who suspects abuse published in 2000 (3) is updated and brought in line with current practice replacing the previous document. The update is restricted to a target population of children under 3 years of age suspected of being subject to abusive head trauma (AHT).

This document is a joint endeavour between the Royal College of Ophthalmologists and the Royal College of Paediatrics and Child Health (RCPCH). The guidance has been primarily developed for ophthalmologists but is an evidence-based resource for any physician or surgeon involved in child protection.

It is incumbent on any ophthalmologist involved with child maltreatment to

1. Be aware of the standards of assessment and documentation.
2. Advise multidisciplinary teams of the presence of eye findings and their interpretation.
3. Follow local guidelines of the child safeguarding team.
4. Be aware of current literature and the controversies
5. Provide a balanced view on the interpretation of eye findings when requested to by legal services.

## 1.2. Terminology

Non accidental injury (NAI) or non-accidental head injury (NAHI) and shaken baby syndrome (SBS) are terms that have been used synonymously in previous college publications to describe the forms of physical abuse most relevant to the ophthalmologist. Abusive head trauma (AHT) is the currently accepted term and will be used in addition to the previously accepted terminology.

## 1.3 Aims of the guidance

1. To review the literature from the time of the last publications on AHT and the eye.
2. To update the previously published articles

3. To identify good practice in the management of cases referred with suspected abusive head trauma and encourage evidence based standardized assessment of such children.
4. To identify new information concerning conditions which may simulate the ocular findings in abusive head trauma in children.

#### **1.4 Scope of guidance**

This guidance deals with the new literature in the field of abusive head trauma to supplement and update the previous publications produced by the College. The previous publications asked a series of questions based on the published literature and provided a synopsis of the literature for each question at the time. This review will include an update on the answers to questions asked in the previous publications and additional questions that a review of the current literature identifies.

The guidance will be presented as 4 chapters, whereby each topic will be followed by the related bibliography to facilitate finding references related to a particular topic.

- i. Aetiological factors and experimental models
- ii. Clinical features and pathology
- iii. Differential diagnosis and confounding conditions
- iv. Guidance for the ophthalmologist.

#### **References**

- (1) The Ophthalmology Child Abuse Working Party. Child abuse and the eye. *Eye* 1999;13(1):3-10.
- (2) Adams G, Ainsworth J, Butler L, Bonshek R, Clarke M, Doran R, et al. Update from the ophthalmology child abuse working party: Royal College of Ophthalmologists. *Eye* 2004;18(8):795-8.
- (3) <http://www.rcophth.ac.uk/documents.asp?section=39&sectionTitle=Publications> (accessed January 2013)

## 2. METHODS

### 2.1. Clinical Questions

The guideline working party (GWP) consisted of paediatric ophthalmologists, pathologists and a paediatrician who represented the RCPCH. This group of professionals are directly involved in the care of, investigations of children with suspected abusive head trauma, are involved in current research in child protection or in the writing of medical reports and appearing as expert witnesses in Court in cases of abusive head trauma in children. Input from the College lay advisory group was sought.

The following clinical questions were developed:

- What forces are needed to produce retinal haemorrhages and other signs of intraocular trauma in infants without direct ocular injury? (see [section 3.1.1.](#))
- Is additional impact necessary for the production of very severe ocular injury? ([see 3.1.2.](#))
- Can normal handling (such as vigorous play) cause retinal and intracranial haemorrhages? ([see 3.1.3.](#))
- What are the postulated mechanisms of retinal haemorrhages in abusive and non abusive head trauma? ([see 3.1.4.](#))
- Does hypoxia give rise to the clinical picture of SBS? ([see 3.1.5.](#))
- What are the current computer and biomechanical models of AHT? ([see 3.1.6.](#))
- Are there any suitable animal models of AHT? ([see 3.1.7.](#))
- Are retinal haemorrhages in child abuse more common in infants than in older children? ([see 3.2.1.](#))
- What is the usual site and extent of retinal haemorrhages in child abuse? ([see 3.2.2.1.](#))
- Are any ocular fundus findings pathognomonic of child abuse? ([see 3.2.2.2.](#))
- Are unilateral retinal haemorrhages compatible with child abuse? ([see 3.2.2.3.](#))
- Can intraocular haemorrhage increase after injury? ([see 3.2.2.4.](#))
- Is it possible to determine from an examination of the retina, the time at which an injury occurred or whether there have been haemorrhages at more than one time? ([see 3.2.2.5.](#))
- Are there any retinal findings without intracranial findings or encephalopathy? ([see 3.2.2.6.](#))
- Are retinal haemorrhages secondary to intracranial bleeding? ([see 3.2.2.7.](#))
- Is intracranial damage always accompanied by retinal haemorrhages in AHT? ([see 3.2.2.8.](#))
- What is the optic nerve and orbital pathology seen in AHT ([see 3.2.3.1.](#))
- Can accidental injury cause retinal haemorrhages? ([see 3.3.1.](#))
- What other conditions of childhood may have retinal haemorrhages? ([see 3.3.2.](#))
- For how long can birth related retinal haemorrhages persist? ([see 3.3.3.](#))
- Can bleeding diathesis or blood dyscrasia cause retinal haemorrhages similar to those seen in child abuse? ([see 3.3.4.](#))

- Can seizures alone cause retinal haemorrhages as seen in cases of child abuse? ([see 3.3.5.1.](#))
- Can cardio-pulmonary resuscitation cause retinal haemorrhages? ([see 3.3.5.2.](#))
- Can prolonged vomiting, gagging cause retinal haemorrhages? ([see 3.3.5.3.](#))
- Is an apparent life threatening event associated with retinal haemorrhages? ([see 3.3.5.4.](#))
- Are vaccinations associated with retinal haemorrhages? ([see 3.3.5.5.](#))
- Do high cervical injuries from any other source give rise to retinal haemorrhages? ([see 3.3.6.](#))
- Can short distance falls cause retinal haemorrhages? ([see 3.3.7.](#))
- Do retinal haemorrhages similar to AHT occur with raised intracranial pressure? ([see 3.3.8.](#))
- What are the ocular findings in crush injury? ([see 3.3.9.](#))
- Which methods are useful in imaging the retina in AHT? ([see 3.4.1](#))

## 2.2. Gathering evidence

### 2.2.1. Search strategy

A search strategy was developed based on the clinical questions and comprehensive literature search was carried out from 2000-2011 with the help of an information specialist from Cardiff University. The text words and mesh headings used for Medline search are listed in [Appendix 1](#). The search was conducted on 19th January 2011.

### 2.2.2. Databases and Journals

ASSIA (Applied Social Sciences Index and Abstracts), BIOSIS, CINAHL (Cumulative Index to Nursing & Allied Health Literature), Cochrane Database of Systematic Reviews (CDSR), EMBASE (Excerpta Medica), ISI Science Citation Index, MEDLINE, MEDLINE In-Process & Other Non-Indexed Citations, SCOPUS and OpenSIGLE.

Hand search of American Journal of Ophthalmology, Archives of Ophthalmology, British Journal of Ophthalmology, Eye, Journal of American Association for Paediatric Ophthalmology and Strabismus and Ophthalmology. For new topics, a further search of relevant material published prior to 2000 was undertaken through Pub Med.

### 2.2.3. Search results and data extraction

A total of 5,823 abstracts were identified for the period 2000 to January 2011. After scanning for relevancy, 657 abstracts were selected. Each member of the working party reviewed the selected abstracts and called for relevant full text studies pertinent to the topic allocated to them. A critical appraisal form (CAF) ([Appendix 2](#)) was completed for each study reviewed. Studies were included for the update of each topic based on standardised inclusion criteria as detailed on the CAF form. In addition the update was restricted to children less than 3 years of age. ([Section 3.2.1](#) however comments on the age (range) of presentation of AHT are reported)

### 2.2.4. Levels of evidence and grades of recommendations

Though this work represents guidance only as recommendations are based on literature reviewed they will be graded according to an adapted Scottish intercollegiate guidelines network (SIGN)(4) (see Table 1). Grades of recommendation will be used based on the table below. In addition a further grade 'E' was added for experimental studies. Expert opinion was excluded given the polarized views that some experts express in this field. 'Good practice points' are used in the guidance for the ophthalmologist section.

**Table 1. Evidence statements and grades of recommendation taken from SIGN developer's handbook (4)**

LEVELS OF EVIDENCE	
1++	High quality meta-analyses, systematic reviews of RCTs, or RCTs with a very low risk of bias
1+	Well-conducted meta-analyses, systematic reviews, or RCTs with a low risk of bias
1-	Meta-analyses, systematic reviews, or RCTs with a high risk of bias
2++	High quality systematic reviews of case control or cohort or studies. High quality case control or cohort studies with a very low risk of confounding or bias and a high probability that the relationship is causal
2+	Well-conducted case control or cohort studies with a low risk of confounding or bias and a moderate probability that the relationship is causal
2-	Case control or cohort studies with a high risk of confounding or bias and a significant risk that the relationship is not causal
3	Non-analytic studies, e.g. case reports, case series
4	Expert opinion
GRADE OF RECOMMENDATION	
A	At least one meta-analysis, systematic review, or RCT rated as 1++, and directly applicable to the target population; or A body of evidence consisting principally of studies rated as 1+, directly applicable to the target population, and demonstrating overall consistency of results
B	A body of evidence including studies rated as 2++, directly applicable to the target population, and demonstrating overall consistency of results; or  Extrapolated evidence from studies rated as 1++ or 1+
C	A body of evidence including studies rated as 2+, directly applicable to the target population and demonstrating overall consistency of results; or Extrapolated evidence from studies rated as 2++
D	Evidence level 3 or 4; or Extrapolated evidence from studies rated as 2+
E	EXPERIMENTAL STUDIES
GPP	Recommended best practice based on the clinical experience of the GWP

### References

(4) Scottish Intercollegiate Guidelines Network. SIGN 50 A guideline developer's handbook. Edinburgh: Scottish Intercollegiate Guidelines Network; 2011 (<http://www.sign.ac.uk/guidelines/fulltext/50/index.html>) accessed January 2013

### **2.2.5. External peer review**

1. Members of Child maltreatment working party of the Royal College of Ophthalmologists.
2. Members of the Paediatric subcommittee of the Royal College of Ophthalmologists.
3. Members of the Royal College of Ophthalmologists Scientific committee.
4. Members of the Royal College of Ophthalmologists
  
5. Members of the Royal college of Paediatrics and Child Health.
6. Lay advisory group of the Royal College of Ophthalmologists.

### **2.2.6. Date for Review of Document**

This document will be reviewed for an update in 2018.

### **2.2.7. Facilitation and Funding**

This document was commissioned by the RCO. The paediatric subcommittee of the RCO elected the chairman. The guideline working party (GWP) was recruited from Ophthalmologists by an open invitation through an online forum of paediatric ophthalmologists, invitation of pathologists involved in the previous RCO child abuse documents and a paediatrician on recommendation of the RCPCH. The work carried out by the information specialist was funded by charitable funds of the Ophthalmology department in the University Hospital of Wales. The RCO funded a meeting of all the members of the GWP. The Chairman through electronic communications facilitated the work of all members of the GWP. The RCPCH has funded formatting of the document and its references. There was no external funding for the time, expertise and commitment of members of the GWP who completed tasks designated to them by the chairman within stipulated timelines. There are no barriers to the publication of this guidance.

## 3. CLINICAL QUESTIONS AND EVIDENCE

### 3.1. Aetiological factors and experimental models.

#### 3.1.1. Forces

*Clinical question: What forces are needed to produce retinal haemorrhages and other signs of intraocular trauma in infants without direct ocular injury?*

#### **Evidence from previous review 1999**

Retinal injury can be produced by positive or negative acceleration without impact or direct ocular injury. It has been suggested that this retinal injury may be due to vitreous traction (5). Evidence for retinal haemorrhages caused by angular acceleration without impact comes from adults exposed to emergency aircraft ejection (6), children involved in road traffic accidents without direct trauma to the eye (7), bungee jumping (8);(9);(10) and from perpetrator confessions (11). Indirect evidence of the forces involved in the production retinal injury comes from extrapolating data of cerebral and eye injury (12);(13) from animal experiments (14), infant models (15) and the observation that not all abused infants with retinal haemorrhages have signs of impact (16);(17). Retinal injury from accidental trauma is very rare and is predominantly seen in severe injury (11);(18). Tangential injury causes more brain deformation, and shear may explain the propensity for retinal injury with a shaking injury (11). Retinal haemorrhages are not reported in household falls even with skull fractures and are only seen in severe motor vehicle accidents (19). Additional retinal findings like perimacular retinal folds, sub retinal, choroidal and vitreous haemorrhage may indicate application of greater severity of forces (5);(13).

Conclusions: There are no absolute values for the angular acceleration forces required to produce retinal haemorrhages, but there is evidence that this must be considerable.

C,D,
------

#### **Evidence from update review 2012**

The forces involved in producing retinal haemorrhages in abusive head trauma are not known. Information on the forces involved is extrapolated from observational, experimental studies using computational and animal models. Please see sections [3.1.2](#), [3.1.3](#), [3.1.4](#) and [3.1.6](#).

#### *References*

- (5) Green MA, Lieberman G, Milroy CM, Parsons MA. Ocular and cerebral trauma in non-accidental injury in infancy: Underlying mechanisms and implications for paediatric practice. *Br J Ophthalmol* 1996;80(4):282-7.
- (6) Lyle DJ, Stapp JP, Button RR. Ophthalmologic hydrostatic pressure syndrome. *Am J Ophthalmol* 1957;44(1):652-7.
- (7) Gilliland MG, Folberg R. Shaken babies: Some have no impact injuries. *J Forensic Sci* 1996;41:114-6.
- (8) David DB, Mears T, Quinlan MP. Ocular complications of bungee jumping. *Br J Ophthalmol* 1994;78(3):234-5.



- (9) Jain BK, Talbot EM. Bungee jumping and intraocular haemorrhage. *Br J Ophthalmol* 1994;78(3):236-7.
- (10) Chan J. Ophthalmic complications after bungee jumping. *Br J Ophthalmol* 1994;78(3):239.
- (11) Duhaime AC, Alario AJ, Lewander WJ, Schut L, Sutton LN, Seidl T, et al. Head injury in very young children: Mechanisms, injury types, and ophthalmologic findings in 100 hospitalized patients younger than 2 years of age. *Pediatrics* 1992;90(2):179-85.
- (12) Budenz DL, Farger MG, Mirchandani HG, Park H, Rorke LB. Ocular and optic nerve haemorrhages in abused infants with intracranial injuries. *Ophthalmology* 1994;101:559-65.
- (13) Wilkinson WS, Han DP, Rappley MD, Owings CL. Retinal haemorrhage predicts neurologic injury in the shaken baby syndrome. *Arch Ophthalmol* 1989; 107(10):1472-4.
- (14) Ommaya AK, Faas F, Yarnell P. Whiplash injury and brain damage: An experimental study. *JAMA* 1968;204(4):285-9.
- (15) Duhaime AC, Gennarelli TA, Thibault LE, Bruce DA, Margulies SS, Wiser R. The shaken baby syndrome: A clinical, pathological and biomechanical study. *J Neurosurg* 1987;66:409-15.
- (16) Hadley MN, Sonntag VK, Rekate HL, Murphy A. The infant whiplash-shake injury syndrome: A clinical and pathological study. *Neurosurgery* 1989;24:536-40.
- (17) Guthkelch AN. Infantile subdural haematoma and its relationship to whiplash injuries. *BMJ* 1971;2:430-1.
- (18) Buys YM, Levin AV, Enzenauer RW, Elder JE, Letourneau MA, Humphreys RP, et al. Retinal findings after head trauma in infants and young children. *Ophthalmology* 1992;99(11):1718-23.
- (19) Reiber GD. Fatal falls in childhood: How far must children fall to sustain fatal head injury? Report of cases and review of the literature. *Am J Forensic Med Pathol* 1993;14:201-7.

### 3.1.2. Impact

*Clinical question: Is additional impact (in addition to shaking injury) necessary for the production of very severe ocular injury?*

#### **Evidence from previous review 1999**

Direct impact (blunt trauma) is likely to be involved in the most severe cases of abusive retinal haemorrhages as experimental models suggest direct impact involves greater deceleration forces than does shaking (15);(11). An autopsy series of 10 cases where children had died from suspected inflicted injury described signs of head injury where signs of impact were sometimes occult (20). Other studies have described severe eye injuries with and without evidence of direct impact (5);(7);(16);(17);(21).

**Conclusion:** In addition to a shaking injury impact may contribute to the severity of retinal damage but is not mandatory for its production.

#### **Evidence from review update 2012**

There were no studies found which were designed explicitly to address the question of the nature of retinal injuries seen in cases of shaking alone as compared with cases of shaking plus direct impact.

A biomechanical analysis of animal and neonatal cadaver models has suggested that the forces necessary for shaking to cause retinal haemorrhages would also lead to substantial cervical spine injuries. As neck injuries are uncommonly

described in AHT, the authors suggest a re-evaluation of the relative significance of impact and shaking as mechanisms of injury (22).

Severe retinal haemorrhages are described after some, but not all crush injuries to the head. They were reported in 6 of 10 children aged < 3 years who died with crush injuries to the head (23). In autopsy study one of the 16 children who died after a television fell on their head had retinal haemorrhages (to mid-equator) and 1/ 169 with crush injuries to the head had haemorrhages extending to the ora; this child had been unrestrained in a car accident (24).

In five cases where a perpetrator had confessed to shaking and causing a direct impact, retinal haemorrhages were seen bilaterally with no description of severity in three infants who had retinal examination as compared with in 17/24 where the perpetrator did not confess to causing impact, although 2 of these cases did have evidence of impact nonetheless (25). Severe haemorrhages were seen in 10/110 children referred for possible AHT and all were found to have definite evidence of inflicted injury, on the basis of evidence of impact to skull, or other bony fractures and no relevant history (26).

However severe haemorrhages are also reported where there is no evidence of impact. In 13/16 (81%) cases of admitted AHT severe haemorrhages were seen, whilst only 9/24 (38%) of these had evidence of impact (27), and similarly in another study severe haemorrhages were present in 25/45 (57%) cases of cases of admitted AHT, whilst only 10/45 (22%) of these had evidence of impact (28). No correlation was found between the number of retinal haemorrhages and evidence of direct impact, in 75 children with confirmed abusive head injuries (29).

A systematic review concluded that whilst it is difficult to confirm the relative contributions of shaking and direct impact to the presentation of retinal haemorrhages, the full spectrum of ocular injury can occur without evidence of direct impact (30).

Conclusion: In experimental research there remain uncertainties regarding the likely mechanical events leading to particular patterns of injury.

Severe retinal haemorrhages occur in some crush and head impact injuries but may be seen without any associated evidence of direct impact to the head.

B,C,D,
--------

### References

- (5) Green MA, Lieberman G, Milroy CM, Parsons MA. Ocular and cerebral trauma in non-accidental injury in infancy: Underlying mechanisms and implications for paediatric practice. *Br J Ophthalmol* 1996;80(4):282-7.
- (7) Gilliland MG, Folberg R. Shaken babies: Some have no impact injuries. *J Forensic Sci* 1996;41:114-6.
- (11) Duhaime AC, Alario AJ, Lewander WJ, Schut L, Sutton LN, Seidl T, et al. Head injury in very young children: Mechanisms, injury types, and ophthalmologic findings in 100 hospitalized patients younger than 2 years of age. *Pediatrics* 1992;90(2):179-85.
- (15) Duhaime AC, Gennarelli TA, Thibault LE, Bruce DA, Margulies SS, Wiser R. The shaken baby syndrome: A clinical, pathological and biomechanical study. *J Neurosurg* 1987;66:409-15.

- (16) Hadley MN, Sonntag VK, Rekate HL, Murphy A. The infant whiplash-shake injury syndrome: A clinical and pathological study. *Neurosurgery* 1989;24:536-40.
- (17) Guthkelch AN. Infantile subdural haematoma and its relationship to whiplash injuries. *BMJ* 1971;2:430-1.
- (20) Elnor SG, Elnor VM, Arnall M, Albert DM. Ocular and associated systemic findings in suspected child abuse: A necropsy study. *Arch Ophthalmol* 1990;108(8):1094-101.
- (21) Frank Y, Zimmerman R, Leeds NMD. Neurological manifestations in abused children who have been shaken. *Dev Med Child Neurol* 1985;27(3):312-6.
- (22) Bandak FA. Shaken baby syndrome: A biomechanics analysis of injury mechanisms. *Forensic Sci Int* 2005;151(1):71-9.
- (23) Kivlin J, Currie M, Greenbaum V, Simons K, Jentzen J. Retinal hemorrhages in children following fatal motor vehicle crashes: A case series. *Arch Ophthalmol* 2008;126(6):800-4.
- (24) Gnanaraj L, Gilliland MGF, Yahya RR, Rutka JT, Drake J, Dirks P, et al. Ocular manifestations of crush head injury in children. *Eye* 2007;21(1):5-10.
- (25) Adamsbaum C, Grabar S, Mejean N, Rey-Salmon C. Abusive head trauma: Judicial admissions highlight violent and repetitive shaking. *Pediatrics* 2010;126(3):546-55.
- (26) Binenbaum G, Mirza-George N, Christian CW, Forbes BJ. Odds of abuse associated with retinal hemorrhages in children suspected of child abuse. *J AAPOS* 2009;13(3):268-72.
- (27) Pierre-Kahn V, Roche O, Dureau P, Uteza Y, Renier D, Pierre-Kahn A, et al. Ophthalmologic findings in suspected child abuse victims with subdural hematomas. *Ophthalmology* 2003;110(9):1718-23.
- (28) Vinchon M, de Foort-Dhellemmes S, Desurmont M, Delestret I. Confessed abuse versus witnessed accidents in infants: Comparison of clinical, radiological, and ophthalmological data in corroborated cases. *Childs Nervous Syst* 2010;26(5):637-45.
- (29) Morad Y, Kim YM, Armstrong DC, Huyer D, Mian M, Levin AV. Correlation between retinal abnormalities and intracranial abnormalities in the shaken baby syndrome. *Am J Ophthalmol* 2002;134(3):354-9.
- (30) Bhardwaj G, Chowdhury V, Jacobs MB, Moran KT, Martin FJ, Coroneo MT. A systematic review of the diagnostic accuracy of ocular signs in pediatric abusive head trauma. *Ophthalmology* 2010;117(5):983-92.

### 3.1.3. Vigorous handling and play

*Clinical question: Can normal handling (such as vigorous play) cause retinal and intracranial haemorrhages?*

#### **Evidence from previous review 2004**

In 2001, Geddes (31);(32) reported the results of histopathological examination of the central nervous system (CNS) following fatal head injuries in 37 infants and 16 children. These studies have been interpreted by sections of the press (33) and some experts as suggesting that minor trauma, such as might occur during rough play, could cause the clinical picture commonly attributed to the Shaken Baby Syndrome (SBS). These studies (31);(32) showed that, in infants with abusive head trauma, there was evidence of hypoxic/ ischaemic neuronal damage rather than the diffuse axonal changes associated with traumatic brain injury. This concept is supported by neuroimaging (34);(35). In 13 of 37 infants reported by Geddes (32) there was axonal damage at the cranio-cervical junction. It was suggested that this injury to the respiratory centres had a role in producing hypoxia and brain damage. These studies raise the possibility of alternative explanations for the observed pathology. While previously, it was assumed that the forces used must be sufficient to cause shearing injury, it is now apparent that shearing is not

the sole pathogenesis of the changes seen in the brain (these reports specifically excluded discussion of the aetiology of retinal haemorrhages). Although the precise level of force required to cause retinal haemorrhages remains uncertain, the majority of these children were unequivocally the victims of severe trauma. Despite having access to full documentation in 52 cases, the authors did not cite a case in which they could link a less than violent event with fatal head injury. Nonetheless, in eight infants there was no bruising, skull fracture, or extra cranial injury to specifically indicate a violent event. It is now appreciated that evidence from mechanical models (15) may reveal an imperfect picture of the events occurring during injury (36). It has been conceded that, 'whilst controversy still exists as to the exact mechanism, most authors now agree that the forces necessary to cause this type of injury are far from trivial and, in fact, are considerable' and 'that this sort of injury is unlikely to be inflicted 'accidentally' by well-meaning carers who do not know that their behaviour can be injurious'(37).

**Conclusion:** It is highly unlikely that the forces required to produce retinal haemorrhage in a child less than two years of age would be generated by a reasonable person during the course of (even rough) play or an attempt to arouse a sleeping or apparently unconscious child.

#### **Evidence from review update 2012**

Some case studies are pertinent to this question but many do not give sufficient evidence of exclusion of abuse (38);(39);(40);(41);(42);(43) or do not have ophthalmological input into all cases (44). On the basis of a few case series (11) (45) and case studies (46), there is anecdotal evidence that retinal haemorrhages can occur in healthy children less than two years old during handling accidents and accidents during play. It is to be noted however that in all these studies where retinal haemorrhages have been reported in association with the accidental injury significant head injury coexists. These retinal haemorrhages are likely to be few, small and unilateral.

More severe haemorrhages in these circumstances should initiate concerns of there being an underlying medical condition or the possibility of prior non-accidental injury even in fully independently witnessed accidents.

C,D,E
-------

#### *References*

- (11) Duhaime AC, Alario AJ, Lewander WJ, Schut L, Sutton LN, Seidl TS, et al. Head injury in very young children: Mechanisms, injury types, and ophthalmologic findings in 100 hospitalized patients younger than 2 years of age. *Pediatrics* 1992;90(2):179-85.
- (15) Duhaime AC, Gennarelli TA, Thibault L, Bruce D, Margulies S, Wiser R. The shaken baby syndrome: A clinical, pathological and biomechanical study. *J Neurosurg* 1987;66:409-15.
- (31) Geddes JF, Hackshaw AK, Vowles GH, Nickols CD, Whitwell HL. Neuropathology of inflicted head injury in children. I. Patterns of brain damage. *Brain* 2001;124(7):1290-8.
- (32) Geddes JF, Vowles GH, Hackshaw AK, Nickols CD, Scott IS, Whitwell HL. Neuropathology of inflicted head injury in children. II. Microscopic brain injury in infants. *Brain* 2001;124(7):1299-306.
- (33) Coghlan A, LePage M. Gently does it. *New Scientist* 2001;4-5.

- (34) Biousse V, Suh DY, Newman NJ, Davis PC, Mapstone T, Lambert SR. Diffusion-weighted magnetic resonance imaging in shaken baby syndrome. *Am J Ophthalmol* 2002;133(2):249-255.
- (35) Jaspan T, Griffiths PD, McConachie NS, Punt JAG, The Trent NAI group. Neuroimaging for non-accidental head injury in childhood: A proposed protocol. *Clin Radiol* 2003;58(1):44-53.
- (36) Ommaya AK, Goldsmith W, Thibault L. Biomechanics and neuropathology of adult and paediatric head injury. *Br J Neurosurg* 2002;16(3):220-42.
- (37) Duhaime AC, Christian C. Child nervous systems. In: Choux M, Di Rocco C, Walker ML, editors. *Pediatric Neurosurgery*. 17 ed. London: Churchill Livingstone; 1999. p. 373-9.
- (38) Plunkett J. Fatal pediatric head injuries caused by short-distance falls. *Am J Forensic Med Pathol* 2001;22(3):322-336.
- (39) Gardner HB. A witnessed short fall mimicking presumed shaken baby syndrome (inflicted childhood neurotrauma). *Pediatr Neurosurg* 2007;43(5):433-5.
- (40) Lantz P, Couture DE. Fatal acute intracranial injury, subdural hematoma, and retinal hemorrhages caused by stairway fall. *J Forensic Sci* 2011;56(6):1648-53.
- (41) Sauvageau A, Bourgault A, Racette S. Cerebral traumatism with a playground rocking toy mimicking shaken baby syndrome. *J Forensic Sci* 2008;53(2):479-82.
- (42) Wickham T, Abrahamson E. Head injuries in infants: the risks of bouncy chairs and car seats. *Arch Dis Child* 2002;86(3):168-9.
- (43) Jones MD, James DS, Cory CZ, Leadbeater S, Nokes LDM. Subdural haemorrhage sustained in a baby-rocker?: A biomechanical approach to causation. *Forensic Sci Int* 2003;131(1):14-21.
- (44) Reece RM, Sege R. Childhood head injuries: Accidental or inflicted? *Arch Pediatr Adolesc Med* 2000;154(1):11-5.
- (45) Trenchs V, Curcoy A, Morales M, Serra A, Navarro R, Pou J. Retinal haemorrhages in head trauma resulting from falls: Differential diagnosis with non-accidental trauma in patients younger than 2-years of age. *Childs Nerv Syst* 2008;24(7):815-20.
- (46) Christian CW, Taylor AA, Hertle RW, Duhaime AC. Retinal hemorrhages caused by accidental household trauma. *J Pediatr* 1999;135(1):125-7.

### 3.1.4. Mechanisms

*Clinical question: What are the postulated mechanisms of retinal haemorrhages in abusive and non-abusive head trauma?*

#### **Evidence from previous review 1999**

Non-abusive or accidental head trauma is in general due to impact injury, rather than shaking injury. Retinal haemorrhages are not associated with witnessed accidental trauma unless the injury forces are very severe (7);(11);(18);(19) . Terson's syndrome (retinal haemorrhage associated with intracranial haemorrhage) is rare following accidental head trauma (or neurosurgery) in infants and young children (47).

The mechanisms of retinal haemorrhage that occur in abusive head trauma (AHT) are thought to be:

1. Direct vitreous traction on the retina (5), leading to angular positive and negative acceleration forces.
2. Sudden rise in intracranial pressure.
3. Sudden rise in central venous pressure.

AHT may be due to impact injury, repetitive flexion / extension shaking injury, or a combination of both. It should be noted that within the shaking injury of repetitive flexion and extension the infant's head might impact their chest and or back at the extremes of movement. The deceleration produced by impact is much greater than that produced by shaking flexion / extension of the head (11);(15). Signs of impact head injury is usually (7);(20), but not always (5);(16);(17);(21) found when retinal haemorrhages and cerebral damage are present.

Evidence that angular acceleration without impact can produce retinal haemorrhages includes:

1. Adults who have sustained emergency ejection forces, and in deceleration experiments (6).
2. Road traffic accidents in children (7).
3. Bungee jumpers (8);(10).
4. Confessed shaking injuries (7);(11).
5. Not all infants with retinal haemorrhages associated with abuse have signs of impact injury (5);(7);(16);(17).

Experimental information about forces necessary to produce brain injury is available. As the severity of brain injury and eye injury correlate, it has been argued that brain injury experiments may be extrapolated to eye injury. These include:

1. Whiplash injury experiments in monkeys (14).
2. Experiments in infant models (7);(15).
3. Tangential acceleration is associated with much more brain deformation and shear than an equivalent linear acceleration. This may account for the relationship between retinal haemorrhages and shaking injury in infants (11).
4. Severe eye injuries are likely to be associated with the severe level of forces that cause severe brain injuries (5);(13).

Speculation that hypoxia might cause retinal haemorrhages in the context of cervical injury-related apnoea, is not supported by evidence (48).

### **Evidence from review update 2012**

An understanding of the mechanisms of retinal haemorrhages (RHs) in AHT provides clinical insights into the condition, and enables the critical evaluation of alternative explanations of injury volunteered by those present at the time of the injury. As direct experimentation is not possible, much of the evidence for the mechanisms of RHs in AHT is both indirect, and incomplete.

RHs occur because of loss of integrity of blood vessel walls. In trauma, mechanical rupture of blood vessel walls may occur because of external traction, compression, and shearing forces transmitted by the vitreous, or by internal forces of increased intravascular pressure, which may occur due to transient acceleration effects or be secondary to transient or sustained raised intracranial pressure. The mechanical strength of retinal blood vessel walls may be low in infants, however the mechanical properties of human infant ocular tissues are not known.

While both internal and external forces on the blood vessel walls probably contribute to the occurrence of RHs in AHT, there are pointers towards the dominant factor in particular situations. For instance, the widespread, severe RHs occasionally seen in severe crush injuries of the head (24);(49) are likely to be due to transient very high intravascular pressure effects. In contrast, sustained periods of raised intracranial pressure and intrathoracic pressure have not been associated with the severity of RHs (29). In most circumstances it is not possible to differentiate the effects of transient external forces on retinal blood vessel walls and transient elevation of intravascular pressure.

Case series of AHT in which the perpetrator has confessed and described the abuse have shown that violent shaking, with or without head impact, has occurred (25);(50);(51). The onset of neurological signs is immediate, or occurs soon after the incident (25);(50);(51). RH have been found in almost all cases, and in most cases have been numerous and bilateral (25);(28);(50),(52).

A post mortem case series of 10 cases of severe road traffic accidents showed severe RHs in most cases (23). Retinoschisis and retinal folds were described in association with numerous retinal haemorrhages in a case of accidental severe crush injury of the head (49). However, in a series of 27 cases of fatal and non-fatal head crush injury, while retinal haemorrhages were found in some cases, there were no cases of retinoschisis or retinal folds (24). In a case series of 75 cases of abusive head trauma the severity of retinal haemorrhages correlated with the severity of head trauma (29). However, the severity of RHs did not correlate with periods of raised intracranial or intrathoracic pressure, head impact trauma, or the side of brain / retina injury (29). Conversely, in a series of 154 cases assessed following a fall, only three cases were found to have RHs. All 3 cases had unilateral RHs, and epidural haemorrhage was present in all 3 cases (45). In general, it would appear to be the case that severe RHs may occur in association with severe head injury, either due to inflicted shaking with or without impact, or due to severe (often fatal) accidental high velocity or crush injuries.

Attempts have been made to measure the forces that occur in various types of injury. Animal studies have added little information to clinical accounts. Intraocular haemorrhages, including peripheral RHs, have been induced by rapid head rotation in neonatal pigs (53). However, the pattern of haemorrhages was different from that seen in human abusive head trauma cases. Retinal haemorrhages have also been produced in mice shaken in brain injury studies, but no description of the pattern of retinal haemorrhages was given (54). Retinal haemorrhages have not been produced in other animal studies of shaking induced brain injury (55);(56).

Mechanical experiments and mathematical models have also added only limited additional understanding to date. A case of the violent use of a baby rocker chair was found in a re-creation engineering experiment to produce greater forces than those in shaking injury (57), however a similar experiment did not confirm this (43). A number of theoretical models of the mechanics of ocular trauma in shaking injury have been developed (58);(59);(60). However, as the mechanical properties of the tissues of human infant eyes is not known, it is difficult to be clear as to how well these models relate to clinical situations (58);(59);(60). The studies may

provide some insights into the patterns of injury seen. The possible significance of the tethering effect of the optic nerve in shaking injury has been considered (59). Modelling of stresses at the retinal surface has indicated that maximum stress may occur at the posterior pole, and at the retinal periphery (60). Engineering calculations of shaking and impact head injury based on available mechanical and animal models have been developed (36). It has been pointed out that forces required to produce brain injury is inversely proportional to its mass – brain injury will occur with lower levels of force than eye injury (36).

Models of the mechanics of head trauma in adults have also been developed (61), but once again it is difficult to relate these to clinical situations (62). Test dummy experiments showed that shaking with impact produces much greater acceleration /deceleration forces than either impact from a short fall, or shaking alone (61). Test dummy experiments of short falls demonstrated a low risk of significant head (or limb) injury (63). However, the use of head injury models using test dummies to assess infant shaking / impact injuries have been criticised as not being biofidelic by engineers, who propose using theoretical modelling (64), and alternative models using “Head Injury Criterion” have been proposed (64). Similarly, engineering calculations of the forces experienced in the neck of shaken infants found that severe cervical spine injury would be expected to occur in the context of the magnitude of forces assumed to occur with head shaking in an infant (22). There is therefore a discrepancy between the mechanical assumptions and calculations derived from these, and clinical experience. Engineering modelling of floor surfaces have shown that wide variation in the degree of injury will occur, dependent on the mechanical properties of the surface that the head impacts (65).

Conclusion: Possible mechanisms for RHs in abusive head trauma include: external forces on blood vessel walls (shaking or impact); internal forces of raised intravascular pressure (pulsed or maintained); biomechanical properties of blood vessel walls though this is not known and abnormalities of the blood (in various pathologies).

E

Evidence is indirect, and the mechanisms may well be mixed in most cases. There are some pointers towards the likely predominant mechanism in certain circumstances: external forces; confessed shaking injury, with / without impact very often associated with numerous, bilateral RHs; Shaking may indicate potential vitreous traction with external forces, and additional internal forces. In accidental impact trauma RHs are only associated with severe, high velocity injuries.

Head crush injury (abrupt severe elevation intravascular pressure) can produce severe RHs, however the severity of RHs does not correlate with periods of raised intracranial or intrathoracic pressure.

C,D

### References

- (5) Green MA, Lieberman G, Milroy CM, Parsons MA. Ocular and cerebral trauma in non-accidental injury in infancy: Underlying mechanisms and implications for paediatric practice. Br J Ophthalmol 1996;80(4):282-7.
- (6) Lyle DJ, Stapp JP, Button RR. Ophthalmologic hydrostatic pressure syndrome. Am J Ophthalmol 1957;44(1):652-7.



- (7) Gilliland MG, Folberg R. Shaken babies: Some have no impact injuries. *J Forensic Sci* 1996;41:114-6.
- (8) David DB, Mears T, Quinlan MP. Ocular complications of bungee jumping. *Br J Ophthalmol* 1994;78(3):234-5.
- (9) Jain BK, Talbot EM. Bungee jumping and intraocular haemorrhage. *Br J Ophthalmol* 1994;78(3):236-7.
- (10) Chan J. Ophthalmic complications after bungee jumping. *Br J Ophthalmol* 1994;78(3):239.
- (11) Duhaime AC, Alario AJ, Lewander WJ, Schut L, Sutton LN, Seidl T, et al. Head injury in very young children: Mechanisms, injury types, and ophthalmologic findings in 100 hospitalized patients younger than 2 years of age. *Pediatrics* 1992;90(2):179-85.
- (13) Wilkinson WS, Han DP, Rappley MD, Owings CL. Retinal haemorrhage predicts neurologic injury in the shaken baby syndrome. *Arch Ophthalmol* 1989; 107(10):1472-4.
- (14) Ommaya AK, Faas F, Yarnell P. Whiplash injury and brain damage: An experimental study. *JAMA* 1968;204(4):285-9.
- (15) Duhaime AC, Gennarelli TA, Thibault LE, Bruce DA, Margulies SS, Wiser R. The shaken baby syndrome: A clinical, pathological and biomechanical study. *J Neurosurg* 1987;66:409-15.
- (16) Hadley M, Sonntag V, ReKate H, Murphy A. The infant whiplash-shake injury syndrome: A clinical and pathological study. *Neurosurgery* 1989;24:536-40.
- (17) Guthkelch AN. Infantile subdural haematoma and its relationship to whiplash injuries. *BMJ* 1971;2:430-1.
- (18) Buys YM, Levin AV, Enzenauer RW, Elder JE, Letourneau MA, Humphreys RP, et al. Retinal findings after head trauma in infants and young children. *Ophthalmology* 1992;99(11):1718-23.
- (19) Reiber GD. Fatal falls in childhood: How far must children fall to sustain fatal head injury? Report of cases and review of the literature. *Am J Forensic Med Pathol* 1993;14:201-7.
- (20) Elnor SG, Elnor VM, Arnall M, Albert DM. Ocular and associated systemic findings in suspected child abuse: A necropsy study. *Arch Ophthalmol* 1990;108(8):1094-101.
- (21) Frank Y, Zimmerman R, Leeds NMD. Neurological manifestations in abused children who have been shaken. *Dev Med Child Neurol* 1985;27(3):312-6.
- (22) Bandak FA. Shaken baby syndrome: A biomechanics analysis of injury mechanisms. *Forensic Sci Int* 2005;151(1):71-9.
- (23) Kivlin J, Currie M, Greenbaum V, Simons K, Jentzen J. Retinal hemorrhages in children following fatal motor vehicle crashes: A case series. *Arch Ophthalmol* 2008;126(6):800-4.
- (24) Gnanaraj L, Gilliland MGF, Yahya RR, Rutka JT, Drake J, Dirks P, et al. Ocular manifestations of crush head injury in children. *Eye* 2007;21(1):5-10.
- (25) Adamsbaum C, Grabar S, Mejean N, Rey-Salmon C. Abusive head trauma: Judicial admissions highlight violent and repetitive shaking. *Pediatrics* 2010;126(3):546-55.
- (28) Vinchon M, de Foort-Dhellemmes S, Desurmont M, Delestret I. Confessed abuse versus witnessed accidents in infants: Comparison of clinical, radiological, and ophthalmological data in corroborated cases. *Childs Nervous Syst* 2010;26(5):637-45.
- (29) Morad Y, Kim YM, Armstrong DC, Huyer D, Mian M, Levin AV. Correlation between retinal abnormalities and intracranial abnormalities in the shaken baby syndrome. *Am J Ophthalmol* 2002;134(3):354-9.
- (36) Ommaya AK, Goldsmith W, Thibault L. Biomechanics and neuropathology of adult and paediatric head injury. *Br J Neurosurg* 2002;16(3):220-42.
- (43) Jones MD, James DS, Cory CZ, Leadbeater S, Nokes LDM. Subdural haemorrhage sustained in a baby-rocker?: A biomechanical approach to causation. *Forensic Sci Int* 2003;131(1):14-21.
- (45) Trenchs V, Curcoy A, Morales M, Serra A, Navarro R, Pou J. Retinal haemorrhages in head trauma resulting from falls: Differential diagnosis with non-accidental trauma in patients younger than 2-years of age. *Childs Nerv Syst* 2008;24(7):815-20.

- (47) Schloff S, Mullaney PB, Armstrong DC, Simantirakis E, Humphreys RP, Myseros JS, et al. Retinal findings in children with intracranial hemorrhage. *Ophthalmology* 2002;109(8):1472-6.
- (48) Oehmichen M, Gerling I, Meissner C. Petechiae of the baby's skin as differentiation symptom of infanticide versus SIDS. *J Forensic Sci* 2000;45(3):602-7.
- (49) Watts P, Obi E. Retinal folds and retinoschisis in accidental and non-accidental head injury. *Eye* 2008;22(12):1514-6.
- (50) Biron D, Shelton D. Perpetrator accounts in infant abusive head trauma brought about by a shaking event. *Child Abuse Neglect* 2005;29(12):1347-58.
- (51) Starling SP, Patel S, Burke BL, Sirotiak AP, Stronk S. Analysis of perpetrator admissions to inflicted traumatic brain injury in children. *Arch Pediatr Adolesc Med* 2004;158(5):454-8.
- (52) Margolin EA, Dev L, Trobe JD. Prevalence of retinal hemorrhages in perpetrator-confessed cases of abusive head trauma. *Arch Ophthalmol* 2010;128(6):795.
- (53) Coats B, Binenbaum G, Peiffer RL, Forbes BJ, Margulies SS. Ocular hemorrhages in neonatal porcine eyes from single, rapid rotational events. *Inv Ophthalmol Vis Sci* 2010;51(9):4792-7.
- (54) Bonnier C, Mesples B, Gressen P. Animal models of shaken baby syndrome: Revisiting the pathophysiology of this devastating injury. *Pediatr Rehabil* 2004;7(3):165-71.
- (55) Binenbaum G, Forbes BJ, Reghupathi R, Judkins A, Rorke L, Margulies SS. An animal model to study retinal hemorrhages in nonimpact brain injury. *J AAPOS* 2007;11(1):84-5.
- (56) Serbabescu I, Brown SM, Ramsay D, Levin AV. Natural animal shaking: A model for non-accidental head injury in children? *Eye* 2008;22(5):715-7.
- (57) de San Lazaro C, Harvey R, Ogden A. Shaking infant trauma induced by misuse of a baby chair. *Arch Dis Child* 2003;88(7):632-4.
- (58) Cirovic S, Bhola RM, Hose DR, Howard IC, Lawford PV, Parsons MA. A computational study of the passive mechanisms of eye restraint during head impact trauma. *Comp Meth Biomech Biomed Eng* 2005;8(1):1-6.
- (59) Hans SA, Bawab SY, Woodhouse ML. A finite element infant eye model to investigate retinal forces in shaken baby syndrome. *Graefes Arch Clin Exp Ophthalmol* 2009;247(4):561-71.
- (60) Rangarajan N, Kamalakkannan SB, Hasija V, Shams T, Jenny C, Serbanescu I, et al. Finite element model of ocular injury in abusive head trauma. *J AAPOS* 2009;13(4):364-9.
- (61) Prange MT, Coats B, Duhaime AC, Margulies SS. Anthropomorphic simulations of falls, shakes, and inflicted impacts in infants. *J Neurosurg* 2003;99(1):143-50.
- (62) Doorly MC, Gilchrist MD. The use of accident reconstruction for the analysis of traumatic brain injury due to head impacts arising from falls. *Comp Meth Biomech Biomed Eng* 2006;9(6):371-7.
- (63) Bertocci GE, Pierce MC, Deemer E, Aguel F, Janosky JE, Vogeley E. Using test dummy experiments to investigate pediatric injury risk in simulated short-distance falls. *Arch Pediatr Adolesc Med* 2003;157(5):480-6.
- (64) Cory CZ, Jones MD, James DS, Leadbeater S, Nokes LDM. The potential and limitations of utilising head impact injury models to assess the likelihood of significant head injury in infants after a fall. *Forensic Sci Int* 2001;123(2):89-106.
- (65) Cory CZ, Jones MD. Development of a simulation system for performing in situ surface tests to assess the potential severity of head impacts from alleged childhood short falls. *Forensic Sci Int* 2006;163(1):102-14.

### 3.1.5. Hypoxia

*Clinical question: Does hypoxia give rise to the clinical picture of SBS?*

#### **Evidence from previous review 2004**

The suggested consequences of axonal injury at the cranio-cervical junction are apnoea followed by hypoxia. However, in the absence of circulatory collapse or the vascular changes associated with high altitude (66), acute hypoxia alone is insufficient to cause subdural and retinal bleeding. Similarly, acute hypoxia similar to that which occurs in the lungs, heart, and occasionally other viscera, has not been shown to cause retinal haemorrhages (48).

It has been suggested that intradural and juxtadural bleeding in children dying from non-traumatic, hypoxic conditions provides an explanation for the subdural bleeding in SBS (67). In all, 72% of cases had intradural and juxtadural bleeding histologically identical to that found in three cases of SBS. However, these children suffered 'profound' hypoxia before birth for various reasons including bronchopneumonia and placental insufficiency. There is no indication in this study that apnoea from localised axonal damage can produce a similar picture. The authors hypothesise a sequence of events where severe hypoxia leads to brain swelling, raised intracranial pressure, subsequent subdural, and retinal haemorrhage this study however did not examine eyes.

**Conclusion:** Acute hypoxia resulting from transient apnoea has not been shown to result in the SBS picture. Hypoxia coupled with circulatory collapse may produce potentially fatal brain swelling.

#### **Evidence from review update 2012**

Recently in a postmortem study of premature babies and neonates intradural and subdural haemorrhages have been demonstrated in the setting of hypoxic ischaemic encephalopathy in the neonatal and perinatal period, but examination of the eyes was excluded and hence it is not known if retinal haemorrhages were present or that these postmortem findings could have any relevance to babies who survive with hypoxic ischaemic encephalopathy (68). "Dysphagic choking, apparent life threatening event (ALTE)" has been proposed as a mimic of non-accidental injury in a 4 month old infant where intracranial and bilateral retinal haemorrhages associated with disseminated intravascular coagulation were noted. The brain on autopsy demonstrated hypoxic changes however abusive injury could not be ruled out (69).

There are no clinical or experimental studies which directly address the question of hypoxia as a cause of retinal haemorrhage, but clinical studies in cases of ALTE reveal no retinal haemorrhage in 292 cases (70),(72) and post-mortem ocular endoscopy has revealed that in a single case of sudden infant death syndrome (SIDS) there was no evidence of any retinal pathology (73). One hundred cases where severe coughing led to hospitalisation revealed no instance of retinal haemorrhage (74) and 0/100 cases of intractable vomiting due to pyloric stenosis showed retinal haemorrhage, including one case in which there was respiratory arrest (75).

Local hypoxic damage of the retina has been associated with preretinal and vitreous haemorrhage where peripheral retinal non-perfusion in eyes of infants at variable time intervals following abusive head trauma have been reported (76);(77) and may result in the development of preretinal fibro vascular proliferation and tractional retinal detachment (77);(78).

Conclusion: Hypoxia resulting from apnoea or associated with choking or respiratory arrest during vomiting has not been shown to cause the clinical picture of AHT. Retinal hypo perfusion/ischemia as a result of non-accidental injury may lead to the development of preretinal fibro vascular proliferation and tractional retinal detachment.

D,
----

### References

- (48) Oehmichen M, Gerling I, Meissner C. Petechiae of the baby's skin as differentiation symptom of infanticide versus SIDS. *J Forensic Sci* 2000;45(3):602-7.
- (66) Mullner-Eidenbock A, Rainer G, Strenn K, Zidek T. High-altitude retinopathy and retinal vascular dysregulation. *Eye* 2000;14(5):724-9.
- (67) Geddes JF, Tasker RC, Hackshaw AK, Nickols CD, Adams GGW, Whitwell HL, et al. Dural haemorrhage in non-traumatic infant deaths: Does it explain the bleeding in 'shaken baby syndrome'? *Neuropathol Appl Neurobiol* 2003;29(1):14-22.
- (68) Cohen M, Scheimberg I. Evidence of occurrence of intradural and subdural hemorrhage in the perinatal and neonatal period in the context of hypoxic ischemic encephalopathy: An observational study from two referral institutions in the United Kingdom. *Pediatr Dev Pathol* 2008;12(3):169-76.
- (69) Barnes PD, Galaznik J, Gardner H, Shuman M. Infant acute life-threatening event-dysphagic choking versus nonaccidental injury. *Sem Ped Neurol* 2010;17:7-11.
- (70) Pitetti RD, Maffei F, Chang K, Hickey R, Berger R, Pierce MC. Prevalence of retinal hemorrhages and child abuse in children who present with an apparent life-threatening event. *Pediatrics* 2002;110(3):557-62.
- (71) Altman RL, Forman S, Brand DA. Ophthalmologic findings in infants after an apparent life-threatening event. *Eur J Ophthalmol* 2007;17:648-53.
- (72) Curcoy AI, Trenchs V, Morales M, Serra A, Pou J. Retinal hemorrhages and apparent life-threatening events. *Pediatr Emerg Care* 2010;26(2):118-20.
- (73) Davis NL, Wetli CV, Shakin JL. The retina in forensic medicine: Applications of ophthalmic endoscopy: The first 100 cases. *Am J Forensic Med Pathol* 2006;27(1):1-10.
- (74) Goldman M, Dagan Z, Yair M, Elbaz EL, Lahat E, Yair M. Severe cough and retinal hemorrhage in infants and young children. *J Pediatr* 2006;148(6):835-836.
- (75) Herr S, Pierce MC, Berger RP, Ford H, Pitetti RD. Does valsalva retinopathy occur in infants? An initial investigation in infants with vomiting caused by pyloric stenosis. *Pediatrics* 2004;113(6):1658-61.
- (76) Goldenberg DT, Wu D, Capone AJ, Drenser KA, Trese MT. Nonaccidental trauma and peripheral retinal nonperfusion. *Ophthalmology* 2010;117(3):561-6.
- (77) Caputo G, de Haller R, Metge F, Dureau P. Ischemic retinopathy and neovascular proliferation secondary to shaken baby syndrome. *Retina* 2008;28(3): S42-S46.
- (78) Sturm V, Landau K, Menke MN. Optical coherence tomography findings in shaken baby syndrome. *Am J Ophthalmol* 2008;146(3):363-8.

### 3.1.6. Computational and biomechanical models of ocular injury in AHT

*Clinical Question: What are the current computer and biomechanical models of AHT?*

### **Evidence from previous review 1999**

Biomechanical models do not provide a satisfactory explanation for the events during ocular injury (15);(36).

### **Evidence from review update 2012**

There is no single biofidelic 3 D model available, which takes into account all the biological features of an infant head, especially with regards to the presence of a fontanelle, nature of CSF, biological characteristics of all the tissue components and neck properties (61);(79). In addition there are no biofidelic infant eye models mimicking characteristics of vitreous or sclera (60). A range of values of physical parameters such as angular acceleration, angular velocity, peak 'g' force have been derived from mathematical models, accident reconstruction, adult volunteer and cadaveric studies. Tolerance limits derived from adult or subhuman primate studies and scaled down for assessing injury in AHT may not be valid in human paediatric population (43). To date, there is no biomechanical model which can be applied specifically to quantitatively assess head injury tolerance levels in the paediatric population (43). Small parametric variations (type of neck, head-neck insertion and chest and back padding) in Duhaime's original infant model (15) allowed for significant increase in the value of head angular acceleration. This makes Duhaime's original suggestion that shaking alone may not cause fatal injury doubtful (79). Anthropomorphic and rigid body models (not biofidelic) suggest that shaking alone cannot produce the head accelerations necessary to cause the brain injuries associated with SBS (80).

Finite element model studies suggest that shear stress forces between the eye and the intra orbital fat and the orbital bone oscillation and the forces produced at the posterior pole of the retina may be the mechanism for injury (59);(60);(81);(82). In cases with no evidence of impact, end point impact, of the chin to chest and the occiput to the back during shaking can exceed the injury tolerance limits (65).

Conclusion: A perfect biofidelic model of an infant does not exist and hence forces that are required to produce ocular injury calculated on current models will be imprecise. Data from recent computational models using finite element analysis suggest that shear forces are exerted maximally at the posterior retina. The precise force required to produce the ocular features of abusive head trauma is not known.

E
---

### **References**

- (15) Duhaime AC, Gennarelli TA, Thibault LE, Bruce DA, Margulies SS, Wiser R. The shaken baby syndrome: A clinical, pathological and biomechanical study. *J Neurosurg* 1987;66:409-15.
- (36) Ommaya AK, Goldsmith W, Thibault L. Biomechanics and neuropathology of adult and paediatric head injury. *Br J Neurosurg* 2002;16(3):220-42.
- (43) Jones MD, James DS, Cory CZ, Leadbeatter S, Nokes LDM. Subdural haemorrhage sustained in a baby-rocker?: A biomechanical approach to causation. *Forensic Sci Int* 2003;131(1):14-21.
- (59) Hans SA, Bawab SY, Woodhouse ML. A finite element infant eye model to investigate retinal forces in shaken baby syndrome. *Graefes Arch Clin Exp Ophthalmol* 2009;247(4):561-71.

- (60) Rangarajan N, Kamalakkannan SB, Hasija V, Shams T, Jenny C, Serbanescu I, et al. Finite element model of ocular injury in abusive head trauma. *J AAPOS* 2009;13(4):364-9.
- (61) Prange MT, Coats B, Duhaime AC, Margulies SS. Anthropomorphic simulations of falls, shakes, and inflicted impacts in infants. *J Neurosurg* 2003;99(1):143-50.
- (65) Cory CZ, Jones MD. Development of a simulation system for performing in situ surface tests to assess the potential severity of head impacts from alleged childhood short falls. *Forensic Sci Int* 2006;163(1):102-14.
- (79) Cory CZ, Jones MD. Can shaking alone cause fatal brain injury? *Med Sci Law* 2003;43(4):317-33.
- (80) Wolfson DR, McNally DS, Clifford MJ, Vloeberghs M. Rigid-body modelling of shaken baby syndrome. *J Engi Med* 2005;219(1):63-70.
- (81) Bholra RM, Cirovic S, Parson MA, Hose DR, Lawford PV, Howard IC. Modelling of the eye and orbit to simulate shaken baby syndrome. *Inv Ophthalmol Vis Sci* 2005;46(5):4090.
- (82) Cheng J, Batterbee D, Yoxall A, Sims ND, Rowson J, Howard IC. Shaken baby syndrome: A structural dynamics perspective. *Proceedings of ISMA* 2008:2003-14.

### 3.1.7. Animal models

*Clinical Question: Are there any suitable animal models of AHT?*

There are relatively few experimental studies that inform our understanding of inflicted injury and the formation of retinal and optic nerve sheath haemorrhages in man. Intraocular haemorrhages, including peripheral retinal haemorrhages, have been induced by rapid head rotation in neonatal pigs (53). However, the pattern of haemorrhages was different from that seen in human abusive head trauma cases. Retinal haemorrhages have also been produced in mice shaken in brain injury studies, but no description of the pattern of retinal haemorrhages was given (54). Retinal haemorrhages have not been produced in other animal studies of shaking induced brain injury (55);(56). In six piglets, 50 minutes of conventional, closed chest cardiopulmonary resuscitation gave rise to no retinal haemorrhages (83). Animal studies give various potential insights into the mechanism of the formation of retinal haemorrhages. It is well – known that retinal haemorrhages can form in cases of meningitis and this does not appear to be entirely the result of altered coagulation. One study has shown that experimental meningitis is associated with loss of autoregulation of retinal blood flow (84) raising the possibility of this being a contributory factor in the genesis of retinal haemorrhages. When fluid is rapidly infused into the cisterna magna, optic nerve sheath and retinal haemorrhages have been induced in a non-human primate but not in the dog (85). It has been suggested that the wood-pecker’s resistance to retinal haemorrhages despite substantial rotational forces being applied to the head is a function of lack of vitreous attachment combined with rigidity of the sclera and limited capacity for ocular movement within the orbit (86). There is an experimental study of some value to histopathologists examining eyes post-mortem (PM). In a study of 20 eyes of rhesus macaques with experimental central retinal vein occlusion it was concluded that it takes about two days for haemosiderin to be detectable and that in some but not all eyes, iron deposition can be found many months later (87).  
 Conclusions: There is no satisfactory primate or non-primate models reported that replicate retinal injury seen in children with abusive head trauma.

E
---

## References

- (53) Coats B, Binenbaum G, Peiffer RL, Forbes BJ, Margulies SS. Ocular hemorrhages in neonatal porcine eyes from single, rapid rotational events. *Inv Ophthalmol Vis Sci* 2010;51(9):4792-7.
- (54) Bonnier C, Mesples B, Gressen P. Animal models of shaken baby syndrome: Revisiting the pathophysiology of this devastating injury. *Pediatr Rehabil* 2004;7(3):165-71.
- (55) Binenbaum G, Forbes BJ, Reghupathi R, Judkins A, Rorke L, Margulies SS. An animal model to study retinal hemorrhages in nonimpact brain injury. *J AAPOS* 2007;11(1):84-5.
- (56) Serbabescu I, Brown SM, Ramsay D, Levin AV. Natural animal shaking: A model for non-accidental head injury in children? *Eye* 2008;22(5):715-7.
- (83) Fackler JC, Berkowitz ID, Green WR. Retinal hemorrhages in newborn piglets following cardiopulmonary resuscitation. *Am J Dis Child* 1992;146(11):1294-6.
- (84) Bottoli I, Beharry K, Modanlou HD, Norris K, Ling E, Noya F, et al. Effect of group B streptococcal meningitis on retinal and choroidal blood flow in newborn pigs. *Inv Ophthalmol Vis Sci* 1995;36(7):1231-9.
- (85) Smith DC, Kearns TP, Sayre GP. Preretinal and optic nerve-sheath hemorrhage: Pathologic and experimental aspects in subarachnoid hemorrhage. *Trans Am Acad Ophthalmol Otolaryngol* 1957;61(2):201-11.
- (86) Wagnanski-Jaffe T, Murphy CJ, Smith C, Kubai M, Christopherson P, Ethier CR, et al. Protective ocular mechanisms in woodpeckers. *Eye* 2007; 21(1):83-9.
- (87) Gilliland MC, Folberg R, Hayreh SS. Age of retinal hemorrhages by iron detection: an animal model. *Am J Forensic Med Pathol*. 2005;26(1):1-4.

## 3.2. Clinical features and pathology

### 3.2.1. Age of child at presentation

*Clinical question: Are retinal haemorrhages in child abuse more common in infants than in older children?*

#### **Evidence from previous review 1999**

Retinal haemorrhages due to shaking baby syndrome or shaking infant syndrome are most commonly described in infants less than 12 months of age and they become less frequent and less severe in older children (21);(88);(89). Retinal haemorrhages in older children are more commonly reported in accidental head injury (11);(90). Reports of retinal haemorrhages occurring in older children and adults are anecdotal and rare (91);(92);(93);(94).

#### **Evidence from review update 2012**

Retinal haemorrhages due to child abuse have been commonly and widely documented in children less than two years of age and the prevailing opinion is that such injuries are more or less limited to infancy. Much of the existing published literature involves a selected series of children below the age of 36 months reflecting the difficulty that perpetrators might have in inflicting a shaking injury in older, heavier children, with stronger neck muscles and the smaller head to body size ratio compared to infants. In addition many reported series have an upper age limit, which may exclude analysis RH in older children. One notable series of 123 children (95), all under the age of three years, diagnosed with AHT showed an increased incidence of retinal haemorrhages with increasing age of the

child. Twenty-two out of 24 children (91.6%) greater than 12 months of age and diagnosed with AHT were noted to have any type of RH versus 69 out of 99 infants (69.6%) less than 12 months of age having any type of RH. However, statistical analysis was not possible due to far fewer older children being present in the analysis. A few cases of children as old as eight years presenting with retinal haemorrhages in the context of abuse have also been reported (96);(97). There is no upper age limit to the presence of retinal haemorrhages, but the incidence is likely to be low with increasing age of the child.

Conclusions: Retinal injury in AHT is commonly reported in children under three years of age. The highest prevalence is seen in infancy though case studies of older children have been reported.

D,

### References

- (11) Duhaiame AC, Alario AJ, Lewander WJ, Schut L, Sutton L, Seidl T, et al. Head injury in very young children: Mechanisms, injury types, and ophthalmologic findings in 100 hospitalized patients younger than 2 years of age. *Pediatrics* 1992;90(2):179-85.
- (21) Frank Y, Zimmerman R, Leeds NMD. Neurological manifestations in abused children who have been shaken. *Dev Med Child Neurol* 1985;27(3):312-6.
- (88) Riffenburgh RS, Sathyavagiswaran L. The eyes of child abuse victims: Autopsy findings. *J Forensic Sci* 1991;36(3):741-7.
- (89) Gilliland MG, Luckenbach MW, Chenier TC. Systemic and ocular findings in 169 prospectively studied child deaths: Retinal hemorrhages usually mean child abuse. *Forensic Sci Int* 1994;68(2):117-32.
- (90) Johnson DL, Braun D, Friendly D. Accidental head trauma and retinal hemorrhage. *Neurosurgery* 1993;33(2):231-4.
- (91) Conradi S, Brissie R. Battered child syndrome in a four year old with previous diagnosis of Reye's syndrome. *Forensic Sci Int* 1986;30(2-3):195-203.
- (92) Hosokawa T, Hayasaka S, Yabata K, Tateda H. Two Japanese cases of battered child syndrome with retinal hemorrhage. *Ophthalmologica* 1986;192:17-21.
- (93) Pounder DJ. Shaken adult syndrome. *Am J Forensic Med Pathol* 1997; 18(4):321-4.
- (94) Carrigan TD, Walker E, Barnes S. Domestic violence: The shaken adult syndrome. *J Acci Emerg Medi* 2000;17(2):138-9.
- (95) Kivlin JD, Simons KB, Lazoritz S, Ruttum MS. Shaken baby syndrome. *Ophthalmology* 2000;107(7):1246-54.
- (96) Meirisch RF, Frasier LD, Braddock SR, Giangiacoimo J, Berkenbosch JW. Retinal hemorrhages in an 8-year-old child: An uncommon presentation of abusive injury. *Pediatr Emerg Care* 2004;20(2):118-20.
- (97) Salehi-Had H, Brandt JD, Rosas AJ, Rogers KK. Findings in older children with abusive head injury: Does shaken-child syndrome exist? *Pediatrics* 2006;117(5):e1039-e1044.

## 3.2.2. Characteristics of retinal findings

### 3.2.2.1. Site of retinal haemorrhages

*Clinical question: What is the usual site and extent of retinal haemorrhages in child abuse?*

#### **Evidence from previous review 1999**

Retinal haemorrhages (RH) predominantly seen at the posterior pole but retinal periphery may be difficult to examine clinically (98). Typically all layers of the retina are involved, but may be confined to a single layer (5);(12);(88);(99,102).



Severe retinal haemorrhages and perimacular folds are more likely seen in NAI but are not pathognomonic (20);(103;104), RH can be unilateral or highly asymmetrical (13);(105);(106).

### **Evidence from review update 2012**

A systematic review on the diagnostic accuracy of ocular signs has reported a sensitivity of 75% and a specificity of 94% of intraocular haemorrhage in AHT (30). Unilateral retinal haemorrhages are commonly reported (107). However, RHs are often too numerous to count and extend from posterior pole to ora serrata (27);(29);(108);(109);(110);(111;112).

Conclusion: RHs may be unilateral and asymmetrical but they are often reported as severe, multi-layered and bilateral.

B, C, D
---------

### *References*

- (5) Green MA, Lieberman G, Milroy CM, Parsons MA. Ocular and cerebral trauma in non-accidental injury in infancy: Underlying mechanisms and implications for paediatric practice. *Br J Ophthalmol* 1996;80(4):282-7.
- (12) Budenz DL, Farger MG, Mirchandani HG, Park H, Rorke LB. Ocular and optic nerve haemorrhages in abused infants with intracranial injuries. *Ophthalmology* 1994;101:559-65.
- (13) Wilkinson WS, Han DP, Rappley MD, Owings CL. Retinal haemorrhage predicts neurologic injury in the shaken baby syndrome. *Arch Ophthalmol* 1989; 107(10):1472-4.
- (20) Elnor SG, Elnor VM, Arnall M, Albert DM. Ocular and associated systemic findings in suspected child abuse: A necropsy study. *Arch Ophthalmol* 1990;108(8):1094-101.
- (27) Pierre-Kahn V, Roche O, Dureau P, Uteza Y, Renier D, Pierre-Kahn A, et al. Ophthalmologic findings in suspected child abuse victims with subdural hematomas. *Ophthalmology* 2003;110(9):1718-23.
- (29) Morad Y, Kim YM, Armstrong DC, Huyer D, Mian M, Levin AV. Correlation between retinal abnormalities and intracranial abnormalities in the shaken baby syndrome. *Am J Ophthalmol* 2002;134(3):354-9.
- (30) Bhardwaj G, Chowdhury V, Jacobs MB, Moran KT, Martin FJ, Coroneo MT. A systematic review of the diagnostic accuracy of ocular signs in pediatric abusive head trauma. *Ophthalmology* 2010;117(5):983-92.
- (88) Riffenburgh RS, Sathyavagiswaran L. The eyes of child abuse victims: Autopsy findings. *J Forensic Sci* 1991;36(3):741-7.
- (98) Munger CE, Peiffer RL, Bouldin TW, Kylstra JA, Thompson RL. Ocular and associated neuropathologic observations in suspected whiplash shaken infant syndrome. A retrospective study of 12 cases. *Am J Forensic Med Pathol* 1993;14(3):193-200.
- (99) Jensen AD, Smith RE, Olson MI. Ocular clues to child abuse. *J Pediatr Ophthalmol* 1971;8:270-2.
- (100) Mushin A, Morgan G. Ocular injury in the battered baby syndrome. *Br J Ophthalmol* 1971;55:343-7.
- (101) Rao N, Smith RE, Choi JH, Xu XH, Kornblum RN. Autopsy findings in the eyes of fourteen fatally abused children. *Forensic Sci Int* 1988;39(3):293-9.
- (102) Riffenburgh R, Sathyavagiswaran L. Ocular findings at autopsy of child abuse victims. *Ophthalmology* 1991;98(10):1519-24.
- (103) Gaynon MW, Koh K, Marmor MF, Frankel LR,. Retinal folds in the shaken baby syndrome. *Am J Ophthalmol* 1988;106(4):423-5.
- (104) Massicotte SJ, Folberg R, Torczynski E, Gilliland M, Luckenbach MW. Vitreoretinal traction and perimacular retinal folds in the eyes of deliberately traumatized children. *Ophthalmology* 1991;98(7):1124-7.

- (105) Tyagi A, Willshaw HE, Ainsworth JR. Unilateral retinal haemorrhages in non-accidental injury. *Lancet* 1997;349(9060):1224.
- (106) Ludwig S, Warman M. Shaken baby syndrome: A review of 20 cases. *Ann Emerg Med* 1984;13(2):104-7.
- (107) Arlotti SA, Forbes BJ, Dias MS, Bonsall DJ. Unilateral retinal hemorrhages in shaken baby syndrome. *J AAPOS* 2007;11(2):175-8.
- (108) Kobayashi Y, Yamada K, Ohba S, Nishina S, Okuyama M, Azuma N. Ocular manifestations and prognosis of shaken baby syndrome in two Japanese children's hospitals. *Japanese J Ophthalmol* 2009;53(4):384-8.
- (109) Levin AV. Retinal hemorrhage in abusive head trauma. *Pediatrics* 2010;126(5):961-70.
- (110) Saleh M, Schoenlaub S, Desprez P, Bourcier T, Gaucher D, Astruc D, et al. Use of digital camera imaging of eye fundus for telemedicine in children suspected of abusive head injury. *Br J Ophthalmol* 2009;93(4):424-8.
- (111) Shaw AD, Watts P, Maguire S, Holden S, Mann M, Kemp A. Are retinal findings in abused children different from those who suffer accidental head trauma? Results of a systematic review. *J AAPOS* 2010;14(1):e27.
- (112) Togioka BM, Arnold MA, Bathurst MA, Ziegfeld SM, Nabaweesi R, Colombani PM, et al. Retinal hemorrhages and shaken baby syndrome: An evidence-based review. *J Emerg Med* 2009;37(1):98-106.

### 3.2.2.2. Ocular fundus findings

*Clinical question: Are any ocular fundus findings pathognomonic of child abuse?*

#### **Evidence from previous review 1999**

Severe retinal haemorrhages (preretinal, intraretinal and subretinal) and perimacular retinal folds are frequently seen in child abuse (20);(98);(103) but they cannot be said to be pathognomonic (113). They have also been reported in severe accidental trauma and Terson's syndrome (114) although they are more common in AHT. The presence of perimacular folds may suggest that there have been cycles of acceleration and deceleration (98);(104). Haemorrhagic retinal cysts and retinoschisis are probably much more common in child abuse (20);(115);(116) than accidental trauma.

#### **Evidence from review update 2012**

There are no clinical ocular findings that are pathognomonic for abusive head trauma. Combined data from prospective studies indicate that intra ocular haemorrhages have a high specificity (94%) and sensitivity (75%) for child abuse (27);(30). The specificity is further increased when there is bilateral involvement, peripheral involvement, intraretinal, preretinal, premacular haemorrhages and moderate to severe intraocular haemorrhages (117).

Perimacular retinal folds and traumatic retinoschisis have a low sensitivity and high specificity for AHT. These findings are however not pathognomonic and have been reported in infants after fatal motor vehicle accidents (23) and crush head injuries (49);(118). Optic nerve sheath haemorrhages are significantly more common in abuse than in other conditions in autopsy studies (119).

There have also been case reports of RPE tear (120), epiretinal membrane (121), giant retinal tear (122) macular hole (123), bilateral fourth nerve palsy (124) and vertical sensory nystagmus (125) associated with abusive head trauma.

Conclusion: There are no fundus findings pathognomonic of child abuse though multi-layered retinal haemorrhages that are bilateral involving the posterior pole and periphery may be highly suggestive of it.

C, D

### References

- (20) Elner S, Elner V, Arnall M. Ocular and associated systemic findings in suspected child abuse: A necropsy study. *Arch Ophthalmol* 1990;108(8):1094-101.
- (23) Kivlin JD, Currie ML, Greenbaum VJ, Simons KB, Jentzen J. Retinal hemorrhages in children following fatal motor vehicle crashes: A case series. *Arch Ophthalmol* 2008;126(6):800-4.
- (27) Pierre-Kahn V, Roche O, Dureau P, Uteza Y, Renier D, Pierre-Kahn A, et al. Ophthalmologic findings in suspected child abuse victims with subdural hematomas. *Ophthalmology* 2003;110(9):1718-23.
- (30) Bhardwaj G, Chowdhury V, Jacobs M, Moran K, Martin F, Coroneo M. A systematic review of the diagnostic accuracy of ocular signs in pediatric abusive head trauma. *Ophthalmology* 2010;117(5):983-992.
- (49) Watts P, Obi E. Retinal folds and retinoschisis in accidental and non-accidental head injury. *Eye* 2008;22(12):1514-6.
- (98) Munger C, Peiffer R, Bouldin T, Kylstra J, Thompson R. Ocular and associated neuropathologic observations in suspected whiplash shaken infant syndrome. A retrospective study of 12 cases. *Am J Forensic Med Pathol* 1993;14(3):193-200.
- (103) Gaynon MW, Koh K, Marmor MF, Frankel LR. Retinal folds in the shaken baby syndrome. *Am J Ophthalmol* 1988;106(4):423-5.
- (104) Massicotte SJ, Folberg R, Torczynski E, Gilliland MG, Luckenbach MW. Vitreoretinal traction and perimacular retinal folds in the eyes of deliberately traumatized children. *Ophthalmology* 1991;98(7):1124-7.
- (113) Tongue AC. The ophthalmologist's role in diagnosing child abuse. *Ophthalmology* 1991;98(7):1009-10.
- (114) Keithahn MA, Bennett SR, Cameron D, Mieler WF. Retinal folds in Terson syndrome. *Ophthalmology* 1993;100(8):1187-90.
- (115) Greenwald MJ, Weiss A, Oesterle CS, Friendly DS. Traumatic retinoschisis in battered babies. *Ophthalmology* 1986;93(5):618-25.
- (116) Morris R, Kuhn F, Witherspoon CD. Hemorrhagic macular cysts. *Ophthalmology* 1994;101(1):1.
- (117) Bechtel K, Stoessel K, Leventhal JM, Ogle E, Teague B, Laviertes S, et al. Characteristics that distinguish accidental from abusive injury in hospitalized young children with head trauma. *Pediatrics* 2004;114(1):165-8.
- (118) Lantz PE, Sinal SH, Stanton CA, Weaver RG Jr. Perimacular retinal folds from childhood head trauma. *BMJ* 2004;328(7442):754-6.
- (119) Marshall DH, Brownstein S, Dorey MW, Addison DJ, Carpenter B. The spectrum of postmortem ocular findings in victims of shaken baby syndrome. *Canad J Ophthalmol* 2001;36(7):377-83.
- (120) Ho L, Goldenberg DT, Capone AJ. Retinal pigment epithelial tear in shaken baby syndrome. *Arch Ophthalmol* 2009;127(11):1547-8.
- (121) Ells AL, Kherani A, Lee D. Epiretinal membrane formation is a late manifestation of shaken baby syndrome. *J AAPOS* 2003;7(3):223-5.
- (122) Lash SC, Williams CP, Luff AJ, Hodgkins PR. 360 degree giant retinal tear as a result of presumed non-accidental injury. *Br J Ophthalmol* 2004;88(1):155
- (123) Ou J, Moshfeghy DM, Tawansy K, Sears JE. Macular hole in the shaken baby syndrome. *Arch Ophthalmol* 2006;124(6):913-5.

- (124) Cackett P, Fleck B, Mulvihill AO. Bilateral fourth-nerve palsy occurring after shaking injury in infancy. J AAPOS 2004;8(3):280-1.
- (125) Mulvihill A, Buncic JR. Vertical sensory nystagmus associated with intraocular haemorrhages in the shaken baby syndrome. Eye 2004;18(5):545-56.

### 3.2.2.3. Unilateral retinal haemorrhages

*Clinical question: Are unilateral retinal haemorrhages compatible with child abuse?*

#### **Evidence from previous review 1999**

Unilateral retinal haemorrhages are not uncommon with indirect child abuse injuries. This is based on the following evidence:

1. A report of three consecutive cases (105).
2. In 13 autopsy cases, 3 of the 9 in a group with direct head trauma had unilateral retinal haemorrhages (12).
3. Of 14 consecutive cases of presumed shaken baby, three had unilateral retinal haemorrhages (13).
4. Of 20 cases of shaken infants, four had unilateral retinal haemorrhages (106).
5. In one case out of 7 babies with “physical child abuse” there were haemorrhages on histopathology in only one eye (126).

Unilateral or highly asymmetrical retinal haemorrhages may also occur in pathological disease states and in accidental trauma (114);(126);(127);(128);(129);(130);(131);(132);(133;134).

Conclusions: Unilateral retinal haemorrhages can occur in both direct and indirect child abuse injuries and in other pathological processes.

#### **Evidence from review update 2012**

Unilateral retinal haemorrhages have been described in abusive head trauma (29); (30);(111);(117);(107);(135);(136);(137) and accidental head trauma (23);(30);(45);(111);(117);(137);(138). Bilateral haemorrhages are frequently seen in abusive head trauma (30);(111);(117), and are less prevalent in accidental head trauma (45);(111);(117). When retinal haemorrhages are unilateral, they may be ipsilateral to the side of brain trauma (139);(137);(140);(141), although one study failed to demonstrate this association (29).

Conclusion: While retinal haemorrhages are more commonly bilateral in cases of abusive head trauma, cases with unilateral haemorrhages do occur. They also occur in accidental head trauma, and in other pathologies. When they occur in association with unilateral intracranial haemorrhage, they are often but not exclusively ipsilateral.

B, C, D
---------

#### *References*

- (12) Budenz DL, Farger MG, Mirchandani HG, Park H, Rorke LB. Ocular and optic nerve hemorrhages in abused infants with intracranial injuries. Ophthalmology 1994;101:559-65.

- (13) Wilkinson WS, Han DP, Rappley MD, Owings CL. Retinal hemorrhage predicts neurologic injury in the shaken baby syndrome. *Arch Ophthalmol* 1989;107(10):1472-4.
- (23) Kivlin J, Currie M, Greenbaum V, Simons KB, Jentzen J. Retinal hemorrhages in children following fatal motor vehicle crashes: A case series. *Arch Ophthalmol* 2008;126(6):800-4.
- (29) Morad Y, Kim YM, Armstrong DC, Huyer D, Mian M, Levin AV. Correlation between retinal abnormalities and intracranial abnormalities in the shaken baby syndrome. *Am J Ophthalmol* 2002;134(3):354-359.
- (30) Bhardwaj G, Chowdhury V, Jacobs M, Moran K, Martin F, Coroneo M. A systematic review of the diagnostic accuracy of ocular signs in pediatric abusive head trauma. *Ophthalmology* 2010;117(5):983-992.
- (45) Trenchs V, Curcoy A, Morales M, Serra A, Navarro R, Pou J. Retinal haemorrhages in head trauma resulting from falls: Differential diagnosis with non-accidental trauma in patients younger than 2-years of age. *Childs Nerv Syst* 2008;24(7):815-20.
- (105) Tyagi A, Willshaw HE, Ainsworth JR. Unilateral retinal haemorrhages in non-accidental injury. *Lancet* 1997;349(9060):1224.
- (106) Ludwig S, Warman M. Shaken baby syndrome: A review of 20 cases. *Ann Emerg Med* 1984;13(2):104-7.
- (107) Arlotti SA, Forbes BJ, Dias MS, Bonsall DJ. Unilateral retinal hemorrhages in shaken baby syndrome. *J AAPOS* 2007;11(2):175-8.
- (111) Shaw AD, Watts P, Maguire S, Holden S, Mann M, Kemp A. Are retinal findings in abused children different from those who suffer accidental head trauma? Results of a systematic review. *J AAPOS* 2010;14(1):e27.
- (114) Keithahn MA, Bennett SR, Cameron D, Mieler WF. Retinal folds in Terson syndrome. *Ophthalmology* 1993;100(8):1187-90.
- (117) Bechtel K, Stoessel K, Leventhal Jm, Ogle E, Teague B, Lavietes S, et al. Characteristics that distinguish accidental from abusive injury in hospitalized young children with head trauma. *Pediatrics* 2004;114(1):165-8.
- (126) Betz P, Puschel K, Miltner E, Lignitz E, Eisenmenger W. Morphometrical analysis of retinal hemorrhages in the shaken baby syndrome. *Forensic Sci Int* 1996;78(1):71-80.
- (127) Fraser S, Horgan S, Bardavio J. Retinal haemorrhage in meningitis. *Eye* 1995;9(5):659-60.
- (128) Sandramoulli S, Robinson R, Tsaloumas M, Willshaw H. Retinal haemorrhages and convulsions. *Arch Dis Child* 1997;76(5):449-51.
- (129) Weissgold DJ, Budenz DL, Hood I, Rorke LB. Ruptured vascular malformation masquerading as battered/shaken baby syndrome: A nearly tragic mistake. *Surv Ophthalmol* 1995;39(6):509-12.
- (130) Burton TC. Unilateral Purtscher's retinopathy. *Ophthalmology* 1980;87(11):1096-1105.
- (131) Sethi SK. Retinal hemorrhages after extra corporeal membranous oxygenation. *N C Med J* 1990;51(5):246.
- (132) Carney MD, Wortham E, al-Mateen KB. Vitreous hemorrhage and extracorporeal membrane oxygenation. *Am J Ophthalmol* 1993;15(115):391-3.
- (133) Goetting MG, Sowa B. Retinal hemorrhage after cardiopulmonary resuscitation in children: An etiologic reevaluation. *Pediatrics* 1990;85:585-8.
- (134) Kelley JS. Purtscher's retinopathy related to chest compression by safety belts. Fluorescein angiographic findings. *Am J Ophthalmol* 1972;74(2):278-83.
- (136) Healey K, Schradling W. A case of shaken baby syndrome with unilateral retinal hemorrhage with no associated intracranial hemorrhage. *Am J Emerg Med* 2006;24(5):616-617.
- (137) Barry GPR, Romero KE, Forbes BJ, Christan CW, Binenbaum G. Pathologic brain and head findings associated with retinal hemorrhages in young children with abusive or accidental head injuries. *J AAPOS* 2010; 14(1):e11.

(138) Shaikh S, Fishman ML, Gaynon M, Alcorn D. Diffuse unilateral hemorrhagic retinopathy associated with accidental perinatal strangulation: A Clinicopathologic Report. *Retina* 2001;21(3):252-5.

(140) Gilles EE, McGregor ML, Levy-Clarke G. Retinal hemorrhage asymmetry in inflicted head injury: A clue to pathogenesis? *J Pediatr* 2003;143(4):494-499.

(141) Bhardwaj G, Jacobs MB, Moran KT, Tan K. Terson syndrome with ipsilateral severe hemorrhagic retinopathy in a 7-month-old child. *J AAPOS* 2010;14(5):441-3.

#### 3.2.2.4. Frequency of intraocular haemorrhage

*Clinical question: Can intraocular haemorrhage increase after injury?*


##### **Evidence from previous review 1999**

Retinal haemorrhages (RHs) rapidly increase in extent and severity while the trauma and immediate effects are in progress. However, many of the intracranial events that are associated with RHs do progress gradually. Therefore the finding of increasingly extensive intraocular haemorrhages could reflect observer error, further trauma, further haemorrhages as a result of continuation of the effects of the original trauma, or a spread of the haemorrhage from one layer or area of the retina to another, for example from the subhyaloid space into the vitreous. No references are provided to support this.

##### **Evidence from review update 2012**

Studies specifically dealing with whether or not RHs can increase after injury were not found in the literature reviewed. Most studies include single eye examinations with only a few including repeated or serial eye examinations. In a study of 123 children with subdural haematomas secondary to abuse (95) retinal haemorrhages were present in 83%; eye exams were approximately weekly. Authors document the rate of resolution of RHs of different appearances and layers of the retina (95). A further study of 241 consecutive infants (<3 years) with subdural haematomas (27) where ophthalmic examinations took place at regular intervals until retinal haemorrhages resolved. Neither of these studies reported any increases in retinal haemorrhages though this was not specifically studied. There is a single study which reports that new retinal haemorrhages may appear in premature babies being screened for retinopathy of prematurity (ROP), even in the absence of ROP (142). These haemorrhages are small in number and may resolve very slowly. There was however no control group and no detail regarding the eye screening exams, in particular no reference as to whether RetCam screening was employed. There is also little or no information on the infants underlying medical status. Also see [section 3.4.1](#).

Conclusion: Progressive increasing severity of RH in AHT has not been reported.



##### *References*

(27) Pierre-Kahn V, Roche O, Dureau P, Uteza Y, Renier D, Pierre-Kahn A, et al. Ophthalmologic findings in suspected child abuse victims with subdural hematomas. *Ophthalmology* 2003;110(9):1718-23.

(95) Kivlin JD, Simons KB, Lazowitz S, Ruttum MS. Shaken baby syndrome. *Ophthalmology* 2000;107(7):1246-1254.

(142) Fledelius HC. Retinal haemorrhages in premature infants: A pathogenetic alternative diagnosis to child abuse. *Acta Ophthalmol Scand* 2005;83(4):424-7.

### 3.2.2.5. Timing of haemorrhage injury

*Clinical question: Is it possible to determine from an examination of the retina, the time at which an injury occurred or whether there have been haemorrhages at more than one time?*

#### **Evidence from previous review 1999**

Data on the age of bruising of the skin by its change in colour is controversial (143) <sup>(see foot note 1)</sup> and a parallel cannot be drawn with retinal haemorrhages. It can be extrapolated from retinal haemorrhages (RH) related to birth trauma that superficial flame shaped RH resolve in 24 hours (144);(145) moderately severe haemorrhages take a few weeks to clear (146) and severe retinal haemorrhages with vitreous haemorrhage may take months to clear (147);(148).

The presence of haemosiderin noted in a retinal haemorrhage on pathology suggests it had been present for at least three days (149), hence the presence and absence of haemosiderin in different retinal haemorrhages indicates haemorrhages of different ages (20);(150).

#### **Evidence from review update 2012**

A study reporting on the timing of RHs as shown by clearance of retinal bleeding in AHT gives an wide time frame of 1-11 months (151). Indirect evidence on timing can be extrapolated from two sources where the time of ‘injury’ is known: birth (in humans) and experimental induction of central retinal venous occlusion in adult monkeys. The human birth studies suggest that whilst extensive intra retinal bleeding would be expected to clear by four weeks, with approximately 86% of them clearing within two weeks, discrete intra retinal haemorrhages can be seen up to 58 days after birth (152);(153). An animal study reported resolution of intra retinal bleeding ranging from two days to one month. Histopathologically haemosiderin has demonstrated in the retina which occurs as early as two days after CRVO and may last up to 16.8 months (87).

**Conclusion:** Direct evidence from cases of AHT and indirect evidence from birth studies; give similar timings for clearance of confluent intraretinal bleeding noted clinically. The majority of birth related retinal haemorrhages clear within two weeks though some intraretinal haemorrhages may persist up to 58 days ([see section 3.3.3](#)). Histopathologically the presence of haemosiderin in the retina may represent a haemorrhage, which has occurred between two days and 16.8 months prior to examination

D, E
------

---

<sup>1</sup> Current scientific evidence concludes that is not possible to age bruises from inspection: refer: [www.core-info.cardiff.ac.uk](http://www.core-info.cardiff.ac.uk) & Maguire S, Mann MK, Sibert J, Kemp A. Can you age bruises accurately in children? *Arch Dis Child* 2005;90(2):187-189).

## References

- (20) Elner SG, Elner VM, Arnall M, Albert DM. Ocular and associated systemic findings in suspected child abuse: A necropsy study. *Arch Ophthalmol* 1990;108(8):1094-101.
- (87) Gilliland MC, Folberg R, Hayreh SS. Age of retinal hemorrhages by iron detection: an animal model. *Am J Forensic Med Pathol* 2005;26(1):1-4.
- (143) Stephenson T. Ageing of bruising in children. *J R Soci Medi* 1997;90(6):312-4.
- (144) Sezen F. Retinal haemorrhages in newborn infants. *Br J Ophthalmol* 1970;55(4):248-53.
- (145) Baum JD, Bulpitt CJ. Retinal and conjunctival haemorrhage in the newborn. *Arch Dis Child* 1970;45:344-9.
- (146) Giangiacomo J, Barkett KJ. Ophthalmoscopic findings in occult child abuse. *J AAPOS* 1985;22(6):234-7.
- (147) Mathews GP, Das A. Dense vitreous hemorrhages predict poor visual and neurological prognosis in infants with shaken baby syndrome. *J AAPOS* 1996;33:260-5.
- (148) Ferrone PJ, de Juan EJ. Vitreous hemorrhage in infants. *Arch Ophthalmol* 1994;112(9):1185-9.
- (149) Gilliland MG, Luckenbach MW, Massicotte SJ, Folberg R. The medicolegal implications of detecting hemosiderin in the eyes of children who are suspected of being abused. *Arch Ophthalmol* 1991;109(3):321-2.
- (150) Elner SG, Elner VM, Albert DM, Arnall M. The medicolegal implications of detecting hemosiderin in the eyes of children who are suspected of being abused (reply to letter from Gilliland et al). *Arch Ophthalmol* 1991;109:322.
- (151) McCabe CF, Donahue SP. Prognostic indicators for vision and mortality in shaken baby syndrome. *Arch Ophthalmol* 2000;118(3):373-7.
- (152) Hughes LA, May K, Talbot JF, Parson MA. Incidence, distribution and duration of birth-related retinal hemorrhages: A prospective study. *J AAPOS* 2006;10(2):102-6.
- (153) Emerson MV, Pieramici DJ, Stoessel KM, Berreen JP, Gariano RF. Incidence and rate of disappearance of retinal hemorrhage in newborns. *Ophthalmology* 2001;108(1):36-9.

### 3.2.2.6. Intracranial findings or encephalopathy

*Clinical question: Are there any retinal findings without intracranial findings or encephalopathy?*

#### **Evidence from previous review 1999**

There is a correlation of the severity of retinal haemorrhages and intracranial Injuries (5);(13);(154) though it can be difficult to estimate the severity of, or diagnose intracranial injury on an initial CT scan (155). AHT patients with subdural haemorrhages and other intracranial injuries typically exhibit retinal haemorrhages, but the association is not invariable (5); between 11% (156) and 39% (88) of abused children do not have retinal haemorrhages. Conversely there is little reference to retinal haemorrhages occurring in the absence of intracranial findings although it is suggested that violent chest compression in child abuse may cause retinal haemorrhages (157);(158);(159).

#### **Evidence from review update 2012**


There are case series/case reports suggesting that retinal haemorrhages may be identified in the presence of normal neuro-imaging (136);(160);(161);(162). In the majority of these studies the imaging performed was a CT scan. The CT scan



appears to be relatively insensitive to picking up very thin film subdural bleeding. Morad et al (161) identified eight children with cerebral oedema on CT scanning. Seven of these had very severe cerebral oedema and five died. All had extensive retinal haemorrhages but the CT scan failed to detect any signs of intracranial bleeding. The authors hypothesised that rapidly developing cerebral oedema causes increased intracranial pressure and subsequent tamponade of any accumulating intracranial blood. They also indicated that the prognosis in such cases was very poor. The same group (162) identified nine children diagnosed with AHT with normal CT scan results but retinal or vitreous haemorrhage. All had a normal CT scan at admission to hospital but three were found to have evidence of subdural bleeding on subsequent MRI scanning. The authors recommended that an MRI scan be performed 5-7 days after the presumed injury and postulated that earlier scans may fail to detect acute subdural haemorrhage (because an acute haematoma's density is similar to CSF or brain tissue). They note that MRI scans are also superior to CT in detecting small accumulations of blood, non-haemorrhagic intra-axial injuries such as cortical contusion or shearing and in dating blood collections. They conclude that the diagnosis of AHT can still be made in children with normal CT imaging but emphasised that careful assessment of the combination of clinical signs at presentation is important in children suspected of suffering an inflicted injury. Healey and Schrading (136) reported a single case of a child with a history of apnoea, abnormal neurological signs and unilateral retinal haemorrhages. The CT and MRI scans were normal but the mother admitted shaking the child.

Conclusion: RH's are relatively rare in the absence of encephalopathy or intracranial bleeding in AHT.

CT imaging is relatively insensitive in picking up small subdural haemorrhages and very thin film subdural bleeding. MRI is thus used as definitive method to CT scan to increase diagnostic yield. However, it appears that in some severely injured children, early CT and MR imaging may indicate an absence of intracranial haemorrhage but reveal extensive cerebral oedema. Marked cerebral oedema may prevent intracranial blood accumulation and may in fact be a marker of more severe head injury.



### References

- (5) Green MA, Lieberman G, Milroy CM, Parsons MA. Ocular and cerebral trauma in non-accidental injury in infancy: Underlying mechanisms and implications for paediatric practice. *Br J Ophthalmol* 1996;80(4):282-7.
- (13) Wilkinson WS, Han DP, Rappley MD, Owings CL. Retinal hemorrhage predicts neurologic injury in the shaken baby syndrome. *Arch Ophthalmol* 1989;107:1472-4.
- (89) Riffenburgh RS, Sathyavagiswaran L. The eyes of child abuse victims: Autopsy findings. *J Forensic Sci* 1991;36(3):741-7.
- (136) Healey K, Schrading W. A case of shaken baby syndrome with unilateral retinal hemorrhage with no associated intracranial hemorrhage. *Am J Emerg Med* 2006;24(5): 616-7.
- (154) Zimmerman RA, Bilaniuk LT, Bruce D, Schut L, Uzzell B, Goldberg H. Interhemispheric acute subdural hematoma: a computed tomographic manifestation of child abuse by shaking. *Neuroradiology* 1978;16:39-40.
- (155) Giangiacomo J, Khan JA, Levine C, Thompson VM. Sequential cranial computed tomography in infants with retinal hemorrhages. *Ophthalmology* 1988;95(3):295-9.

- (156) Billmire ME, Myers PA. Serious head injury in infants:accident or abuse? *Pediatrics* 1985;75:340-2.
- (157) Kanter RK. Retinal hemorrhage after cardiopulmonary resuscitation or child abuse. *J Pediatr* 1986;108(3):430-2.
- (158) Tomasi LG, Rosman NP. Purtscher retinopathy in the battered child syndrome. *Am J Dis Child* 1975;129(11):1335-7.
- (159) Carter J, McCormick AQ. Whiplash shaking syndrome: Retinal hemorrhages and computerised axial tomography of the brain. *Child Abuse Neglect* 1983;1983:279-86.
- (160) Wahl NG, Woodall BN. Hypothermia in shaken infant syndrome. *Pediatr Emer Care* 1995;11(4):223-4.
- (161) Morad Y, Avni I, Capra L, Case ME, Feldman K, Kodsi SR, et al. Shaken baby syndrome without intracranial hemorrhage on initial computed tomography. *J AAPOS* 2004;8(6):521-7
- (162) Morad Y, Avni I, Benton SA, Berger RP, Byerley JS, Coffman K, et al. Normal computerized tomography of brain in children with shaken baby syndrome. *J AAPOS* 2004;8(5): 445-50.

### 3.2.2.7. Intracranial bleeding

*Clinical question: Are retinal haemorrhages secondary to intracranial bleeding?*

#### **Evidence from previous review 1999 & 2004**

There is indirect evidence linking brain and eye injury though there is no clear indication that RHs are secondary to intracranial haemorrhage. Reports suggest similar causation for RHs and intracranial haemorrhage (5);(7);(9);(10);(11);(12);(13);(18);(19).

AHT with subdural haemorrhages are often associated with retinal haemorrhages (5);(13);(154). However infants with other intracranial injuries may have retinal haemorrhages (5);(88);(156).

Terson's syndrome (114), described as an association of subarachnoid haemorrhage (either from rupture of intracranial arterial aneurysms or arteriovenous malformations) and retinal haemorrhage in adults (129);(163).

Further reports of Terson's syndrome describe a wider association of any intracranial bleeding with intraocular bleeding (47);(164);(165);(166). A prospective observational study revealed very little evidence for Terson's syndrome in children (47) reporting isolated haemorrhages in children with a mean age of 10.3 years. Intracranial bleeding with associated intraocular haemorrhage was seen in older children in this group.

Conclusion: Terson's syndrome is rare in children and haemorrhages if they occur tend to be concentrated around the optic disc.

#### **Evidence from review update 2012**

A report (141) of a seven month old infant who was diagnosed with a ruptured complex fusiform aneurysm of the right middle cerebral artery resulting in a large acute subarachnoid haemorrhage was found to have extensive right-sided pre and intraretinal haemorrhages.

A further report (167) of a ruptured middle cerebral aneurysm resulting in a subarachnoid haemorrhage in a seven month old infant revealed bilateral extensive intra and preretinal haemorrhages extending to the ora serrata with haemorrhagic optic nerve sheaths on post-mortem examination. It was hypothesized that the ocular and optic nerve sheath haemorrhage was due to a rapid rise in intracranial pressure.

Bilateral retinal haemorrhages, retinal detachment, subdural haemorrhage, subarachnoid haemorrhage, cerebral and cervical cord swelling with multiple rib fractures in a 4.5 month old infant who presented with choking and received cardiopulmonary resuscitation has been reported (69). Though abusive injury could not be excluded the retinal bleeding was attributed to disseminated intravascular coagulopathy, raised intracranial pressure and the attempted CPR.

An infant born to a mother with primary anti-phospholipid syndrome had an extensive occipital infarction with bilateral vitreous haemorrhage and hyphaema (168). It has been postulated that the retinal haemorrhage may have been due to maternally transferred antibodies causing a hypercoagulable state in the neonate resulting in retinal vascular occlusion, or massive cerebral hypoxia and subsequent raised pressure leading to a Terson's like syndrome.

A case of a 38 week gestation infant who died with severe brain oedema, had bilateral extensive peripapillary haemorrhage noted on postmortem examination which was postulated to be caused by a Terson-like phenomenon (142).

Accidental low impact head injury associated with epidural haemorrhage and retinal haemorrhages have been reported (169). In this study the retinal haemorrhages were seen in five cases and were unilateral in four. The retinal haemorrhages were mild concentrated in the posterior pole. It is hypothesized that the mechanism of retinal haemorrhage was secondary to a sudden rise in intracranial pressure due to the epidural haemorrhage. However surgical evacuation of the epidural haemorrhages and the initial trauma may play a role as causal factors of the retinal haemorrhages.

In a prospective study (45), 154 children who sustained vertical falls from a height, 16 infants had epidural haemorrhages and three had mild unilateral retinal haemorrhages. This suggests that RHs with epidural haematomas are rare in children who sustain vertical falls unless there is a midline shift.

Conclusions: Current evidence demonstrates that intra ocular bleeding secondary to intra cranial haemorrhage from intracranial pathology or accidental trauma is rare in young children. Retinal findings however may closely resemble those seen in AHT. Cases where intra ocular and intra cranial haemorrhage are seen together include those with clear evidence of a ruptured aneurysm, severe accidental head injury, epidural haemorrhage and neurosurgical intervention. The severity of the ocular findings being directly related to the severity of the intracranial event with an acute, sharp rise in intracranial cranial pressure playing a role in the mechanism of retinal haemorrhages.

B, C, D
---------

## References

- (5) Green M, Lieberman G, Milroy C, Parsons M. Ocular and cerebral trauma in non-accidental injury in infancy: Underlying mechanisms and implications for paediatric practice. *Br J Ophthalmol* 1996;80(4):282-7.
- (7) Gilliland MG, Folberg R. Shaken babies: Some have no impact injuries. *J Forensic Sci* 1996;41:114-6.
- (9) Jain BK, Talbot EM. Bungee jumping and intraocular haemorrhage. *Br J Ophthalmol* 1994;78:236-7.
- (10) Chan J. Ophthalmic complications after bungee jumping. *Br J Ophthalmol* 1994;78(3):329.
- (11) Duhaime AC, Alario AJ, Lewander WJ, Schut L, Sutton LN, Seidl T, et al. Head injury in very young children: Mechanisms, injury types, and ophthalmologic findings in 100 hospitalized patients younger than 2 years of age. *Pediatrics* 1992;90(2):179-85.
- (12) Budenz DL, Farger MG, Mirchandani HG, Park H, Rorke LB. Ocular and optic nerve haemorrhages in abused infants with intracranial injuries. *Ophthalmology* 1994;101:559-65.
- (13) Wilkinson WS, Han DP, Rappley MD, Owings CL. Retinal haemorrhage predicts neurologic injury in the shaken baby syndrome. *Arch Ophthalmol* 1989; 107(10):1472-4.
- (18) Buys YM, Levin AV, Enzenauer RW, Elder JE, Letourneau MA, Humphreys RP, et al. Retinal findings after head trauma in infants and young children. *Ophthalmology* 1992;99(11):1718-23.
- (19) Reiber GD. Fatal falls in childhood: How far must children fall to sustain fatal head injury? Report of cases and review of the literature. *Am J Forensic Med Pathol* 1993;14:201-7.
- (45) Trenchs V, Curcoy A, Morales M, Serra A, Navarro R, Pou J. Retinal haemorrhages in head trauma resulting from falls: differential diagnosis with non accidental trauma in patients younger than 2 years of age. *Childs Nerv Syst* 2008;24(7):815-20.
- (47) Schloff S, Mullaney PB, Armstrong DC, Simantirakis E, Humphreys RP, Myseros JS, et al. Retinal findings in children with intracranial hemorrhage. *Ophthalmology* 2002;109(8):1472-6.
- (69) Barnes PD, Galaznik J, Gardner H, Shuman M. Infant acute life-threatening event-dysphagic choking versus nonaccidental injury. *Sem Pediatr Neurol* 2010;17:7-11.
- (88) Riffenburgh RS, Sathyavagiswaran L. The eyes of child abuse victims: Autopsy findings. *J Forensic Sci* 1991;36(3):741-7.
- (114) Keithahn MA, Bennett SR, Cameron D, Mieler WF. Retinal folds in Terson syndrome. *Ophthalmology* 1993;100(8):1187-90.
- (129) Weissgold DJ, Budenz DL, Hood I, Rorke LB. Ruptured vascular malformation masquerading as battered/shaken baby syndrome: A nearly tragic mistake. *Surv Ophthalmol* 1995;39(6):509-12.
- (141) Bhardwaj G, Jacobs MB, Moran KT, Tan K. Terson syndrome with ipsilateral severe hemorrhagic retinopathy in a 7-month-old child. *J AAPOS* 2010;14(5):441-3.
- (142) Fledelius HC. Retinal haemorrhages in premature infants: A pathogenetic alternative diagnosis to child abuse. *Acta Ophthalmol Scand* 2005;83(4):424-7.
- (154) Zimmerman RA, Bilianuk LT, Bruce D, Schut L, Uzzell B, Goldberg HI. Interhemispheric acute subdural hematoma: a computed tomographic manifestation of child abuse. *Neuroradiology* 1978;16:39-40.
- (156) Billmire ME, Myers PA. Serious head injury in infants: Accident or abuse? *Pediatrics* 1985;75(2):340-2.
- (163) McLellan NJ, Prasad R, Punt J. Spontaneous subhyaloid and retinal haemorrhages in an infant. *Arch Dis Child* 1986;61(11):1130-2.
- (164) Terson A. Le syndrome du corps vitré et de l'hémorragie intracrânienne spontane. *Ann Oculist* 1926;163:666-73.
- (165) Garfinkle AM, Danys IR, Nicolle DA, Colohan AR, Brem S. Terson's syndrome: A reversible cause of blindness following subarachnoid hemorrhage. *J Neurosurg* 1992;76(5):766-71.

- (166) Pfausler B, Belcl R, Metzler R, Mohsenipour I, Schmutzhard E. Terson's syndrome in spontaneous subarachnoid hemorrhage: a prospective study in 60 consecutive patients. *J Neurosurg* 1996;85(3):392-4.
- (167) Mena OJ, Paul I, Reichard RR. Ocular findings in raised intracranial pressure: A case of Terson syndrome in a 7-month-old infant. *Am J Forensic Med Pathol.* 2011;32(1):55-7
- (168) Noel LP, Botash AS, DeSilva A. Maternal antiphospholipid antibodies and vitreous hemorrhages in the newborn: A case report. *Arch Ophthalmol* 2001;119(6):914-6.
- (169) Forbes BJ, Cox M, Christian CW. Retinal hemorrhages in patients with epidural hematomas. *J AAPOS* 2008;12(2), 177-80.

### 3.2.2.8. Intracranial damage and retinal haemorrhage

*Clinical question: Is intracranial damage always accompanied by retinal haemorrhages in AHT?*

#### **Evidence from previous review 1999**

There is a close correlation between the severity of retinal haemorrhages and intracranial injuries (5);(13);(154) although it is sometimes difficult to estimate the severity of or even to diagnose intracranial injury, on the initial CT scan (155).

It is usual for AHT patients with subdural haemorrhage and other intracranial injuries to have retinal haemorrhages, but the association is not invariable as between 11% and 39% of abused children do not have retinal haemorrhages (88); (156).

#### **Evidence from review update 2012**

There is conflicting information about the incidence of retinal haemorrhage in abusive head trauma in the literature.

A systematic review of the diagnostic accuracy of ocular signs in abusive head trauma found that intra-ocular haemorrhage had a 75% sensitivity for abusive head trauma (30). Retinal haemorrhages are reported in 53- 89% of cases of AHT (27); (29);(95);(112);(117);(170);(171). As intracranial haemorrhage is used as inclusion criterion for the diagnosis of abusive injury in many of these studies this introduces circular logic potentially confounding efforts to make an accurate assessment of incidence. These studies suggest that though retinal haemorrhages are frequently seen in the presence of intracranial injury they are not always present.

A report of prosecuted perpetrators of fatal AHT revealed bilateral RH in all 6 cases (119). Though this report provides evidence that retinal haemorrhages are usual in AHT, limitations of the study prevent firm conclusions as to whether retinal haemorrhages are always associated with brain injury in AHT as the diagnosis was made on the basis of the findings of subdural hematoma of the brain and retinal haemorrhages. Hence it is possible that children with brain injury from abusive head trauma without retinal haemorrhages could have been excluded from the study. Further perpetrator confessed studies of AHT report RH in 46/54 cases (172) and unilateral retinal haemorrhages in 3/17 cases (52).

Conclusion: There is clear evidence that retinal haemorrhage is found in approximately two-thirds of intracranial injury caused by abusive head trauma.

B, C, D

### References

- (5) Green MA, Lieberman G, Milroy CM, Parsons MA. Ocular and cerebral trauma in non-accidental injury in infancy: Underlying mechanisms and implications for paediatric practice. *Br J Ophthalmol* 1996;80(4):282-7.
- (13) Wilkinson WS, Han DP, Rappley MD, Owings CL. Retinal haemorrhage predicts neurologic injury in the shaken baby syndrome. *Arch Ophthalmol* 1989; 107(10):1472-4.
- (27) Pierre-Kahn V, Roche O, Dureau P, Uteza Y, Renier D, Pierre-Kahn A, et al. Ophthalmologic findings in suspected child abuse victims with subdural hematomas. *Ophthalmology* 2003;110(9):1718-23.
- (29) Morad Y, Kim YM, Armstrong DC, Huyer D, Mian M, Levin AV. Correlation between retinal abnormalities and intracranial abnormalities in the shaken baby syndrome. *Am J Ophthalmol* 2002;134(3):354-9.
- (30) Bhardwaj G, Chowdhury V, Jacobs MB, Moran KT, Martin FJ, Coroneo MT. A systematic review of the diagnostic accuracy of ocular signs in pediatric abusive head trauma. *Ophthalmology* 2010;117(5):983-92.
- (52) Margolin EA, Dev L, Trobe JD. Prevalence of retinal hemorrhages in perpetrator-confessed cases of abusive head trauma. *Arch Ophthalmol* 2010;128(6):795.
- (88) Riffenburgh RS, Sathyavagiswaran L. The eyes of child abuse victims: Autopsy findings. *J Forensic Sci* 1991;36(3):741-7.
- (95) Kivlin JD, Simons KB, Lazowitz S, Ruttum MS. Shaken baby syndrome. *Ophthalmology* 2000;107(7):1246-54.
- (112) Togioka BM, Arnold MA, Bathurst MA, Ziegfeld SM, Nabaweesi R, Colombani PM, et al. Retinal hemorrhages and shaken baby syndrome: An evidence-based review. *J Emerg Med* 2009;37(1):98-106.
- (117) Bechtel K, Stoessel K, Leventhal Jm, Ogle E, Teague B, Lavietes S, et al. Characteristics that distinguish accidental from abusive injury in hospitalized young children with head trauma. *Pediatrics* 2004;114(1):165-8.
- (119) Marshall DH, Brownstein S, Dorey MW, Addison DJ, Carpenter B. The spectrum of postmortem ocular findings in victims of shaken baby syndrome. *Canad J Ophthalmol* 2001;36(7):377-83.
- (154) Zimmerman RA, Bilaniuk LT, Bruce D, Schut L, Uzzell B, Goldberg HI. Interhemispheric acute subdural hematoma: a computed tomographic manifestation of child abuse by shaking. *Neuroradiology* 1978;16:39-40.
- (155) Giangiacomo J, Khan JA, Levine C, Thompson VM. Sequential cranial computed tomography in infants with retinal hemorrhages. *Ophthalmology* 1988;95(3):295-9.
- (156) Billmire MF, Myers PA. Serious head injury in infants: Accident or abuse? *Pediatrics* 1985;75(2):340-2.
- (170) Aryan H, Ghosheh FR, Jandial R, Levy ML. Retinal hemorrhage and pediatric brain injury: Etiology and review of the literature. *J Clin Neurosci* 2005;12(6):624-31.
- (171) Ghahreman A, Bhasin V, Chaseling R, Andrews B, Lang EW. Nonaccidental head injuries in children: A Sydney experience. *J Neurosurg* 2005;103(3):213-8.
- (172) Leestma JE. Case analysis of brain-injured admittedly shaken infants: 54 cases, 1969-2001. *Am J Forensic Med Pathol*. 2005;26(3):199-212.

### 3.2.3. Pathology

#### 3.2.3.1. What is the optic nerve and orbital pathology seen in AHT

### **Evidence from previous review 1999**

Optic nerve sheath haemorrhage associated with the rupture of a subarachnoid vascular malformation was reported in 2 children who were initially suspected of having AHT (129);(163).

### **Evidence from review update 2012**

The first description of optic nerve sheath haemorrhage (ONSH) in AHT was reported in 1986 (173). Since then, there have been 17 studies in which optic nerves have been examined pathologically in cases of deaths due to AHT, accidental trauma, and non-traumatic causes (5);(12); (20); (24);(88);(89);(98);(101);(102);(104);(119);(126);(174);(175);(176);(177);(178). Four involve the sequential inclusion of autopsy case material between 1984 to 1999 (88);(102);(176) (101), therefore the last study of this series was included for analysis (176). Two studies contain details of orbital pathology in addition to the optic nerve (20);(177). Six studies are controlled, with inclusion of non-AHT case material (5);(12);(102);(126);(176);(177). One study focuses on accidental crush head injury (24). Overall, in the studies included, ONSH was found in 229 of 486 (47%) of cases of AHT and retinal haemorrhage was found in 250 cases (51%). There was variation from series which included all forms of child abuse (176);(178), where 50% were found to have ONSH, to series which included RH as an inclusion criterion (98);(119);(174) where 86% had ONSH. Where this feature was documented, subdural ONSH was more prevalent than subarachnoid haemorrhage. Most cases in which there was ONSH also had RHs; a small number of cases occurred in which ONSH or RHs were found in isolation.

In non-AHT cases, ONSH was found in 28 of 545 cases (5%) and RH in 34 (6%). In two controlled studies, severe accidental head injury was associated with optic nerve sheath haemorrhage in 7/21 cases (33%) (126);(177). A post-mortem study on orbital pathology found that subarachnoid haemorrhage in the optic nerve sheath was only seen in cases of non-accidental injury. They also found that orbital pathology was more common in cases of AHT. Extraocular muscle haemorrhage was only seen in cases of AHT (28%), and bleeding into orbital fat was more common in AHT (50%) compared with accidental injury (22%). Bleeding in the posterior orbit was also more common. This study focussed on the examination of the optic nerves and orbital contents (177). A study of severe accidental crush head injury found ONSH in 9 cases (33%) (24). In controlled studies where death was due to non-traumatic causes (e.g. Sudden Infant Death Syndrome, asphyxia, etc.) ONSH was found in 1 of 18 cases (12);(101);(126), and in that case ONSH was demonstrable only on microscopic examination (12).

Bleeding at the optic nerve-scleral junction in the region of the vascular circles of Zinn and Haller (peripapillary intrascleral haemorrhage) is noted in 97 of 208 cases (47%) of AHT, where this feature was sought (20);(24);(89);(119);(173). In 89 control cases a study which included cases of accidental head injury, there was a case of peripapillary intrascleral haemorrhage (1%) (89). Some authors have hypothesised that bleeding at this location was consistent with the action of shearing/torsional forces at the junction of the eye and the optic nerve and, thus was suggestive of, shaking (179). Over 50% of the cases in their study showed no evidence of impact, all had perimacular folds, and 98% had optic nerve haemorrhage. In a study of Terson's syndrome in adults, author (179) proposed an

alternative explanation for the peripapillary intrascleral bleeding, invoking rapid and severely raised intracranial pressure transmitted into the optic nerve sheath, impeding retinal venous outflow from the optic nerve and blood flow via the retinochoroidal anastomoses at the optic nerve-scleral interface. This model also provides an explanation of the optic nerve sheath, premacular and retinal bleeding seen in Terson's syndrome.

Conclusions: Optic nerve sheath haemorrhages are common in AHT, however they may also be seen in cases of accidental head injury. The only study which specifically examined orbital tissues in detail found that bleeding into orbital fat and especially the extraocular muscles and posterior orbit may be of significance in distinguishing AHT from accidental injury, but more work is required to confirm this. Scleral haemorrhage at the junction between the optic nerve and sclera is common in AHT, and is seen in association with ONSH and RH, but the number of studies documenting this finding is small.

D
---

### References

- (5) Green MA, Lieberman G, Milroy CM, Parsons MA. Ocular and cerebral trauma in non-accidental injury in infancy: Underlying mechanisms and implications for paediatric practice. *Br J Ophthalmol* 1996;80(4):282-7.
- (12) Budenz DL, Farger MG, Mirchandani HG, Park H, Rorke LB. Ocular and optic nerve hemorrhages in abused infants with intracranial injuries. *Ophthalmology* 1994;101:559-65.
- (20) Elnor SG, Elnor VM, Arnall M, Albert DM. Ocular and associated systemic findings in suspected child abuse: A necropsy study. *Arch Ophthalmol* 1990;108(8):1094-101.
- (24) Gnanaraj L, Gilliland MGF, Yahya RR, Rutka JT, Drake J, Dirks P, et al. Ocular manifestations of crush head injury in children. *Eye* 2007;21(1):5-10.
- (88) Riffenburgh RS, Sathyavagiswaran L. The eyes of child abuse victims: Autopsy findings. *J Forensic Sci* 1991;36(3):741-7.
- (89) Gilliland MG, Luckenbach MW, Chenier TC. Systemic and ocular findings in 169 prospectively studied child deaths: Retinal hemorrhages usually mean child abuse. *Forensic Sci Int* 1994;68(2):117-32.
- (98) Munger CE, Peiffer RL, Bouldin TW, Kylstra JA, Thompson RL. Ocular and associated neuropathologic observations in suspected whiplash shaken infant syndrome. A retrospective study of 12 cases. *Am J Forensic Med Pathol* 1993;14(3):193-200.
- (101) Rao N, Smith RE, Choi JH, Xu XH, Kornblum RN. Autopsy findings in the eyes of fourteen fatally abused children. *Forensic Sci Int* 1988;39(3):293-9.
- (102) Riffenburgh RS, Sathyavagiswaran L. Ocular findings at autopsy of child abuse victims. *Ophthalmology* 1991;98(10):1519-24.
- (104) Massicotte SJ, Folberg R, Torczynski E, Gilliland MG, Luckenbach MW. Vitreoretinal traction and perimacular retinal folds in the eyes of deliberately traumatized children. *Ophthalmology* 1991;98(7):1124-7.
- (119) Marshall DH, Brownstein S, Dorey MW, Addison DJ, Carpenter B. The spectrum of postmortem ocular findings in victims of shaken baby syndrome. *Can J Ophthalmol* 2001;36(7):377-83.
- (126) Betz P, Puschel K, Miltner E, Lignitz E, Eisenmenger W. Morphometrical analysis of retinal hemorrhages in the shaken baby syndrome. *Forensic Sci Int* 1996;78(1):71-80
- (129) Weissgold DJ, Budenz DL, Hood I, Rorke LB. Ruptured vascular malformation masquerading as battered/shaken baby syndrome: A nearly tragic mistake. *Surv Ophthalmol* 1995;39(6):509-12.
- (163) McLellan NJ, Prasad R, Punt J. Spontaneous subhyaloid and retinal haemorrhages in an infant. *Arch Dis Child* 1986;61(11):1130-2.



- (173) Lambert SR, Johnson TE, Hoyt CS. Optic nerve sheath and retinal hemorrhages associated with the shaken baby syndrome. *Arch Ophthalmol* 1986 ;104(10):1509-12.
- (174) Mills M. Funduscopic lesions associated with mortality in shaken baby syndrome. *J AAPOS* 1998;2(2):67-71.
- (175) Gilles EE, McGregor ML, Levy-Clarke G. Retinal hemorrhage in autopsies asymmetry in inflicted head injury: A clue to pathogenesis. *J Pediatr* 2003;143:494-9.
- (176) Riffenburgh RS. Ocular hemorrhage in autopsies in child abuse victims. *Clin Surg Ophthalmol* 2005;23:178-86.
- (177) Wagnanski-Jaffe T, Levin AV, Shafiq A, Smith C, Enzenauer RW, Elder JE, Morin JD, Stephens D, Atenafu E. Postmortem orbital findings in shaken baby syndrome. *Am J Ophthalmol* 2006;142(2):233-40.
- (178) Emerson MV, Jakobs E, Green WR. Ocular Autopsy and Histopathologic Features of Child Abuse. *Ophthalmology* 2007;114(7):1384-94.
- (179) Muller P, Deck JH. Intraocular and optic nerve sheath hemorrhage in cases of sudden intracranial hypertension. *J Neurosurg* 1974;41(2):160-6.

### 3.3. Differential diagnosis and confounding conditions

#### 3.3.1. Accidental injury and retinal haemorrhage

*Clinical question: Can accidental injury cause retinal haemorrhages?*

#### **Evidence from previous review 1999**

Retinal haemorrhages (RHs) are rare after accidental injury. They may be seen after severe head injury complicated by fractures and diffuse or focal intracranial damage. Children who sustain fatal injuries after reported short falls are more likely to have been subjected to non-accidental trauma (11);(18);(19);(89);(90);(101);(126);(156);(180);(181);(182).

Data from falls in 3357 premobile infants reported fractures in less than 1% with less than 16 infants requiring hospitalization (183). Short falls in infants only rarely show evidence of neurological or ocular damage (184);(185). In studies where a history of short falls are elicited the injuries were ultimately found to be inflicted (19);(186). Retinal haemorrhages in children who sustained accidental household trauma were reported in three cases which were ‘mild’ unilateral, in posterior pole and with no extension to ora serrata (46). A further study of short falls which were estimated to range from 0.6 to 2.4 metres in witnessed playgrounds incidents reported three children with bilateral retinal haemorrhages (38).

Subdural haemorrhage (SDH) with RHs is rarely associated with high velocity accidental injuries in children. Child abuse needs to be considered when SDH and RH exist without an adequate explanation or a medical cause.

#### **Evidence from review update 2012**

An accidental injury is deemed to have occurred when there is a consistent history, a witnessed accident, an accident in a public place, which was witnessed or where the clinicians and investigating authorities concluded an accidental injury occurred (187) Retinal haemorrhages (RHs) are rare in accidental injury and occur in 0% to 15% of children less than 3 years (26) (28);(45);(117);(188);(189). RHs due to accidental trauma involve falls (26);(28);(39);(45);(47);(117);

(169);(187);(188);(190);(191) motor vehicle accidents (MVA)  
(23);(28);(47);(117);(189);(192),(187) crush injury (24);(49);(118);(192);(193) to  
the head between unyielding surfaces and accidents during play (41).

Retinal haemorrhages are predominantly unilateral, mild and located in the posterior pole in case series reporting falls which range from less than 4 feet to over 10 feet (28);(45);(117). RH confined to the posterior pole, few in number and either intra or pre retinal are reported from short falls (a couch, bed, tables, caretakers arms, baby walkers and trolleys) (28);(45);(169). Falling backwards from a sitting position on a carpeted floor in a 11 month old infant was associated with bilateral retinal haemorrhages in all four quadrants of the retina (194) and a 21 month child who fell from a standing position on a chair onto a tiled floor sustained bilateral retinal haemorrhages with retinal folds (190). An 11metre fall of a 24 month old girl who fell onto a concrete surface was associated with bilateral preretinal, intraretinal and subretinal haemorrhages with bilateral macular retinoschisis and a possible retinal fold (191).

Retinal haemorrhages that occur in children who survive MVA's have been reported as mild pre and intra retinal and located in the posterior pole (28);(117) (187);(192);(189). However in children who die from their injuries bilateral, multilayered, numerous RH in the posterior pole and periphery associated with retinal folds are described in autopsy series (23).

In crush injuries to the head the severity of RH varies from mild mainly in the posterior pole, pre and intra retinal (24) to extensive multilayered bilateral RH associated with retinal folds and retinoschisis (49);(118);(192);(193).

Head injury which may include either skull fractures, intracranial haemorrhage (epidural, subdural and subarachnoid) or parenchymal brain injury usually accompanies retinal findings.

Conclusion: RHs are rare in accidental injury. Though the majority of reports suggest that these RHs are mainly mild in severity and predominantly unilateral, few in number either pre or intra retinal and located to the posterior pole, a pattern of bilateral extensive multi-layered RHs extending from the posterior pole to the periphery, associated with retinoschisis and retinal folds have been the subject of a few recent case reports and autopsy series with predominantly severe crush head injury.

C, D
------

### *References*

- 11) Duhaime AC, Alario AJ, Lewander WJ, Schut L, Sutton LN, Seidl T, et al. Head injury in very young children: Mechanisms, injury types, and ophthalmologic findings in 100 hospitalized patients younger than 2 years of age. *Pediatrics* 1992;90(2):179-85.
- (18) Buys YM, Levin AV, Enzenauer RW, Elder JE, Letourneau MA, Humphreys RP, et al. Retinal findings after head trauma in infants and young children. *Ophthalmology* 1992;99(11):1718-23.
- (19) Reiber GD. Fatal falls in childhood: How far must children fall to sustain fatal head injury? Report of cases and review of the literature. *Am J Forensic Med Pathol* 1993;14:201-7.

- (23) Kivlin J, Currie M, Greenbaum V, Simons K, Jentzen J. Retinal hemorrhages in children following fatal motor vehicle crashes: A case series. *Arch Ophthalmol* 2008;126(6):800-4.
- (24) Gnanaraj L, Gilliland MGF, Yahya RR, Rutka JT, Drake J, Dirks P, et al. Ocular manifestations of crush head injury in children. *Eye* 2007;21(1):5-10.
- (26) Binenbaum G, Mirza-George N, Christian CW, Forbes BJ. Odds of abuse associated with retinal hemorrhages in children suspected of child abuse. *J AAPOS* 2009;13(3):268-72.
- (28) Vinchon M, de Foort-Dhellemmes S, Desurmont M, Delestret I. Confessed abuse versus witnessed accidents in infants: Comparison of clinical, radiological, and ophthalmological data in corroborated cases. *Childs Nervous Syst* 2010;26(5):637-45.
- (38) Plunkett J. Fatal pediatric head injuries caused by short-distance falls. *Am J Forensic Med Pathol* 2001; 22(3):322-336.
- (39) Gardner HB. A witnessed short fall mimicking presumed shaken baby syndrome (inflicted childhood neurotrauma). *Pediatr Neurosurg* 2007;43(5):433-5.
- (41) Sauvageau A, Bourgault A, Racette S. Cerebral traumatism with a playground rocking toy mimicking shaken baby syndrome. *J Forensic Sci* 2008;53(2):479-82.
- (45) Trenchs V, Curcoy A, Morales M, Serra A, Navarro R, Pou J. Retinal haemorrhages in head trauma resulting from falls: Differential diagnosis with non-accidental trauma in patients younger than 2-years of age. *Childs Nervous Syst* 2008;24(7):815-20.
- (46) Christian CW, Taylor AA, Hertle RW, Duhaime AC. Retinal hemorrhages caused by accidental household trauma. *J Pediatr* 1999;135(1):125-127.
- (47) Schloff S, Mullaney PB, Armstrong DC, Simantirakis E, Humphreys RP, Myseros JS, et al. Retinal findings in children with intracranial hemorrhage. *Ophthalmology* 2002;109(8):1472-6.
- (49) Watts P, Obi E. Retinal folds and retinoschisis in accidental and non-accidental head injury. *Eye* 2008;22(12):1514-6.
- (89) Gilliland MG, Luckenbach MW, Chenier TC. Systemic and ocular findings in 169 prospectively studied child deaths: Retinal hemorrhages usually mean child abuse. *Forensic Sci Int* 1994;68(2):117-32.
- (91) Johnson DL, Braun D, Friendly D. Accidental head trauma and retinal hemorrhage. *Neurosurgery* 1993;33(2):231-4.
- (101) Rao N, Smith RE, Choi JH, Xu XH, Kornblum RN. Autopsy findings in the eyes of fourteen fatally abused children. *Forensic Sci Int* 1988;39(3):293-9.
- (117) Bechtel K, Stoessel K, Leventhal JM, Ogle E, Teague B, Laviertes S, et al. Characteristics that distinguish accidental from abusive injury in hospitalized young children with head trauma. *Pediatrics* 2004;114(1):165-8.
- (118) Lantz PE, Sinal SH, Stanton CA, Weaver RGJr. Perimacular retinal folds from childhood head trauma. *BMJ* 2004;328(7442):754-6.
- (126) Betz P, Puschel K, Miltner E, Lignitz E, Eisenmenger W. Morphometrical analysis of retinal hemorrhages in the shaken baby syndrome. *Forensic Sci Int* 1996;78(1):71-80.
- (156) Billmire ME, Myers PA. Serious head injury in infants: Accident or abuse? *Pediatrics* 1985;75(2):340-2.
- (169) Forbes Bj, Cox M, Christian CW. Retinal hemorrhages in patients with epidural hematomas. *J AAPOS* 2008;12(2):177-80.
- (180) Eisenbrey AB. Retinal hemorrhage in the battered child. *Childs Brain* 1979;5(1):40-4.
- (181) Alario AD, Lewander W, Tsiaras W, Wallach M, O'Shea JS. Do retinal hemorrhages occur with accidental head trauma in young children. *Am J Dis Child* 1990;144:445.
- (182) Elder JE, Taylor RG, Klug GL. Retinal haemorrhage in accidental head trauma in childhood. *J Paediatr Child Health* 1991;27(5):286-9.
- (183) Warrington SA, Wright CM. Accidents and resulting injuries in premobile infants: data from the ALSPAC study. *Arch Dis Child* 2001;85(2):104-7.

- (184) Maddocks GB, Sibert JR, Brown BM. A four week study of accidents to children in South Glamorgan. *Public Health* 1978;92(4):171-6.
- (185) Rivara FP, Kamitsuka MD, Quan L. Injuries to children younger than 1 year of age. *Pediatrics* 1988;81(1):93-7.
- (186) Jayawant S, Rawlinson A, Gibbon F, Price J, Schulte J, Sharples P, et al. Subdural haemorrhages in infants: population based study. *BMJ* 1998;317(7172):1558-61.
- (187) Feldman KW, Bethel R, Shugerman RP, Grossman DC, Grady MS, Ellenbogen RG. The cause of infant and toddler subdural hemorrhage: A prospective study. *Pediatrics* 2001;108(3):636-46.
- (188) Sturm V, Knecht PB, Landau K, Menke MN. Rare retinal haemorrhages in translational accidental head trauma in children. *Eye* 2009;23(7):1535-41.
- (189) Vinchon M, Noizet O, Defoort-Dhellemmes S, Soto-Ares G, Dhellemmes P. Infantile subdural hematomas due to traffic accidents. *Pediatric Neurosurg* 2002;37(5):245-53.
- (190) Barnes PD, Krasnokutsky MV, Monson KL, Ophoven J. Traumatic spinal cord injury: Accidental versus nonaccidental injury. *Semin Pediatr Neurol* 2008; 15(4): 178-84.
- (191) Reddie IC, Bhardwaj G, Dauber SL, Jacobs MB, Moran KT. Bilateral retinoschisis in a 2-year-old following a three-storey fall. *Eye* 2010;24(8):1426-7.
- (192) Keenan HT, Runyan DK, Marshall SW, Nocera MA, Merten DF. A population-based comparison of clinical and outcome characteristics of young children with serious inflicted and noninflicted traumatic brain injury. *Pediatrics* 2004;114(3):633-9.
- (193) Lueder G, Turner JW, Paschall R. Perimacular retinal folds simulating nonaccidental injury in an infant. *Arch Ophthalmol* 2006;124(12):1782-3.

### 3.3.2. Other childhood conditions and retinal haemorrhage

*Clinical question: What other conditions of childhood may have retinal haemorrhages?*

#### **Evidence from previous review 1999**

- Leukaemia: Reports suggest that RH seen in leukaemia may or may not be associated with other blood abnormalities like thrombocytopenia (195);(196).
- Haemorrhagic disease of the newborn: A study states that there is no association between thrombotest results and birth related RH (145).
- Sickle Cell retinopathy: The retinal findings have distinguishing features which suggest a diagnosis of sickle cell retinopathy (197).
- ECMO treatment: The intraretinal haemorrhages reported may not be due to the ECMO itself but due to other comorbidity (131);(132);(198);(199).
- Retinopathy of prematurity (ROP): The retinal features suggest a diagnosis of ROP.
- Galactosemia: Vitreous haemorrhages described (200).
- Henoch-Schonlein purpura: Transient punctate RH is reported (201).

- Thrombocytopaenic purpura: RHs have been reported (202).
- Maternal ingestion of Cocaine: RH are reported that last longer than typical newborn RH (203).
- Meningitis: RHs associated with meningococcal meningitis is reported (127).
- Intracranial vascular malformation: Subhyaloid and RH is reported in an infant with intracranial arterial aneurysm, and optic sheath haemorrhage in child with ruptured Subarachnoid malformation (129);(163).
- Optic disc drusen, tuberous sclerosis, X linked retinoschisis: Vitreous haemorrhage is reported in these conditions (204);(205).
- Intracranial pathology: Chronic, severe papilloedema may cause peripapillary haemorrhage, and acute, severely raised ICP may cause widespread haemorrhage.
- Intraocular surgery: Multiple RH are reported (206);(207).
- Severe hypertension: RH often present.


### **Evidence from review update 2012**

- Galactosemia: Further evidence noting vitreous haemorrhage is reported (208).
- Homocystinuria: RH with vitreous haemorrhages and SDH is reported in a five week old baby (209).
- Glutaric aciduria: Numerous studies describe the association between glutaric aciduria and RH as well as other retinal features, in young infants many of who may have co-existent SDH. However, neuroradiologically this condition has characteristic findings (210),(212).
- Osteogenesis Imperfecta: Three cases are reported with RH, and one case with vitreous haemorrhages, only in the posterior pole. One case had multiple, large shaped, preretinal, flame dot and blot haemorrhages but no other associated retinal findings (213).
- Osteoporosis- pseudoglioma syndrome: One study noted the presence of RH in the context of exudative vitreoretinopathy, although unlikely to pose a clinical dilemma (214).
- Incontinentia Pigmenti: One newborn infant noted to have RH and vitreous body haemorrhage, progressing to retinal detachment, in the context of a family history and characteristic skin findings (215).

- X - linked retinoschisis: A further 2 cases are recorded with bilateral vitreous haemorrhage by three months of age (216).
- Central retinal vein occlusion: A newborn with macular haemorrhages and associated hydrops with intracerebral haemorrhages, diagnosed as CRVO (217).
- Prematurity proposed as a predisposition to RH from hyperflexion/extension of head during normal handling: This is an unsubstantiated hypothesis relating to preterm infants undergoing ROP screening, of whom 11 had RH or vitreous haemorrhages. Abuse was not explicitly excluded, as it was implied that since the infants were in a special care baby unit (SCBU) it had not occurred. They detail retinal bleeding, and propose that retinal vascular immaturity may play a role in bleeding in these cases (142).
- Infections: Newborn CMV noted to cause retinitis, including RH (218), a child with HSV 6 noted to have a retinal vein occlusion (219), acute retinal necrosis caused by HSV 1 in a newborn (220) numerous reports detail RH in Malaria with associated characteristic changes of the disease, often using it as an indication of cerebral malaria (221),(223), meningococcal septicaemia causing multiple posterior RH in 5/12 children with severe septicaemia and disseminated intravascular coagulation (224) streptococcus pyogenes meningitis in a neonate with glycosylation disorder noted to have RH (225) and also in a neonate with Strep. pneumoniae meningitis had bilateral ‘too numerous to count’ RH found extending to ora serrata in association with CRVO in one case (226), congenital toxoplasmosis infants noted to have RH in association with extensive ocular features of the disease (227).
- Fibromuscular dysplasia: a nonatheromatous, non-inflammatory, multifocal segmental angiopathy of uncertain aetiology. A single case has been recorded of an 11 month old infant with intracerebral and intraventricular haemorrhage in association with extensive subhyaloid and intraretinal haemorrhages (228).
- Tersons syndrome: Although this association is well recognised in the adult literature, this is the first study including children. It included 16 deceased individuals, whose age ranged from 3 months to 90 years. Unfortunately details were only given on one 7 year old child, involved in a MVC, and no specific details of this case were given, nor details as to how Terson’s was confirmed as the aetiology of the RH (229).
- Asphyxia: Two cases of asphyxia causing RH are described, one reports a 12 year old ‘playing’ with others who developed a dense preretinal haemorrhage in his right eye (230), while the other study reported an asphyxiated neonate who had had the umbilical cord tightly wrapped around his neck, with oedematous and ecchymotic eyelids. On day 13 an ophthalmological examination noted a preretinal haemorrhage in right eye,

and diffuse reddish discolouration thought to be severe RH; normal left eye. He died and post mortem (PM) examination revealed multiple RHs in the right eye (138).

- Preterm neonates undergoing Retcam recordings: A 33/40 infant being screened for ROP was examined including a Retcam image, showed no RHs and two areas of vitreous haemorrhage. He was re-examined 10 minutes later by a senior ophthalmologist and noted to have moderate intraretinal dot and blot haemorrhages and a few flame haemorrhages in right posterior pole, predominantly peripapillary (231). However in response to the above study another group examined 50 eyes in 25 children 60 minutes after a Retcam examination for ROP, and none had developed RHs (232).



### References

- (127) Fraser SG, Horgan SE, Bardavio J. Retinal haemorrhage in meningitis. *Eye* 1995;9(5):659-60.
- (129) Weissgold DJ, Budenz DL, Hood I, Rorke LB. Ruptured vascular malformation masquerading as battered/shaken baby syndrome: A nearly tragic mistake. *Surv Ophthalmol* 1995;39(6):509-12.
- (131) Sethi SK. Retinal hemorrhages after extra corporeal membranous oxygenation. *N C Med J* 1990;51(5):246.
- (132) Carney M, Wortham E, al-Mateen K. Vitreous hemorrhage and extracorporeal membrane oxygenation. *Am J Ophthalmol* 1993;15(115):391-3.
- (138) Shaikh S, Fishman ML, Gaynon M, Alcorn D. Diffuse unilateral hemorrhagic retinopathy associated with accidental perinatal strangulation: A Clinicopathologic Report. *Retina* 2001;21(3):252-5.
- (142) Fledelius HC. Retinal haemorrhages in premature infants: A pathogenetic alternative diagnosis to child abuse. *Acta Ophthalmol Scand* 2005;83(4):424-7.
- (145) Baum JD, Bulpitt CJ. Retinal and conjunctival haemorrhage in the newborn. *Arch Dis Child* 1970;45:344-9.
- (163) McLellan NJ, Prasad R, Punt J. Spontaneous subhyaloid and retinal haemorrhages in an infant. *Arch Dis Child* 1986;61(11):1130-2.
- (195) Guyer DR, Schachat AP, Vitale S, Markowitz JA, Braine H, Burke P, et al. Leukemic retinopathy. Relationship between fundus lesions and hematologic parameters at diagnosis. *Ophthalmology* 1989;96(6):860-4.
- (196) Robb RM, Ervin L, Sallan SE. A pathological study of eye involvement in acute leukemia of childhood. *Trans Am Acad Ophthalmol Otolaryngol* 1978;76:90-101.
- (197) Gagliano, DA, Goldberg, MF. The evolution of salmon-patch hemorrhages in sickle cell retinopathy. *Arch Ophthalmol* 1989;107:1814-5.
- (198) Young TL, Quinn GE, Baumgart S, Petersen RA, Schaffer DB. Extracorporeal membrane oxygenation causing asymmetric vasculopathy in neonatal infants. *J AAPOS*. 1997;1(4):235-40.
- (199) Patrias MC, Rabinowicz IM, Klein MD. Ocular findings in infants treated with extracorporeal membrane oxygenator support. *Pediatrics* 1988;82(4):560-4.
- (200) Levy HL, Brown AE, Williams SE, de Juan EJr. Vitreous hemorrhage as an ophthalmic complication of galactosemia. *J Pediatr* 1996;129(6):922-5.
- (201) Petersen S, Taaning E, Söderström T, Pilgaard B, Tranebjaery L, Christensen T, et al. Immunoglobulin and complement studies in children with Schönlein-Henoch syndrome and other vasculitic diseases. *Acta Paediatr Scand* 1991;80(11):1037-43.
- (202) Raja SC, Fekrat S, Connor TBJr. Bilateral macular vitelliform lesions in a thrombocytopenic patient. *Arch Ophthalmol* 1995;113(4):411-3.

- (203) Silva-Araujo AL, Tavares MA, Patacao MH, Carolino RM. Retinal hemorrhages associated with in utero exposure to cocaine: Experimental and clinical findings. *Retina* 1996;16(5):411-8.
- (204) Atkinson A, Sanders MD, Wong V. Vitreous haemorrhage in tuberous sclerosis. Report of two cases. *Br J Ophthalmol* 1973;57(10):773-9.
- (205) George ND, Yates JR, Bradshaw K, Moore A. Infantile presentation of X linked retinoschisis. *Br J Ophthalmol* 1995;79(7):653-7.
- (206) Christiansen S, Muñoz M, Capó H. Retinal hemorrhage following lensectomy and anterior vitrectomy in children. *J AAPOS* 1993;30(1):24-7.
- (207) Mets MB, Del Monte M. Hemorrhagic retinopathy following uncomplicated pediatric cataract extraction. *Arch Ophthalmol* 1986;104(7):975-9.
- (208) Laumonier E, Labalette P, Morisot C, Mouriaux F, Dobbelaere D, Rouland JF. Vitreous hemorrhage in a neonate with galactosemia. A case report. *J Fr Ophthalmol* 2005;28(5):490-6.
- (209) Francis PJ, Calver DM, Barnfield P, Turner C, Dalton RN, Champion MP. An infant with methylmalonic aciduria and homocystinuria (cblC) presenting with retinal haemorrhages and subdural haematoma mimicking non-accidental injury. *Eur J Pediatr* 2004;163(7):420-1.
- (210) Hartley LM, Sonntag VK, ReKate HL. Glutaric aciduria type 1 and nonaccidental head injury. *Pediatrics* 2001;107(1):174-5.
- (211) Kafil-Hussain NA, Monavari A, Bowell R, Thornton P, Naughten E, O'Keefe M. Ocular findings in glutaric aciduria type 1. *J AAPOS* 2000;37(5):289-93.
- (212) Gago LC, Wegner RK, Capone AJ, Williams GA. Intraretinal hemorrhages and chronic subdural effusions: Glutaric aciduria type 1 can be mistaken for shaken baby syndrome. *Retina* 2003;23(5):724-6.
- (213) Ganesh A, Jenny C, Geyer J, Shouldice M, Levin AV. Retinal hemorrhages in type I osteogenesis imperfecta after minor trauma. *Ophthalmology* 2004;111(7):1428-31.
- (214) Ai M, Heeger S, Bartels CF, Schelling DK, Osteoporosis-Pseudoglioma Collaborative Group. Clinical and molecular findings in osteoporosis-pseudoglioma syndrome. *Am J Hum Gen* 2005;77(5):741-53.
- (215) Chang JT, Chiu PC, Chen YY, Wang HP, Hsieh KS. Multiple clinical manifestations and diagnostic challenges of incontinentia pigmenti-12 years' experience in 1 medical center. *J Chin Med Asso* 2008;71(9):455-60.
- (216) Lee JJ, Kim JH, Kim SY, Park SS, Yu YS. Infantile vitreous hemorrhage as the initial presentation of X-linked juvenile retinoschisis. *Kor J Ophthalmol* 2009;23(2):118-20.
- (217) Chen CY, Tsao PN, Young C, Peng SS, Tsou KI. Bilateral central retinal vein occlusion with multiple intracerebral hemorrhage in a neonate. *Pediatric Neurol* 2003;28(5):400-2.
- (218) Barampouti F, Rajan M, Aclimandos W. Should active CMV retinitis in non-immunocompromised newborn babies be treated? *Br J Ophthalmol* 2002;86(2):248-9.
- (219) Takizawa Y, Hayashi S, Fujimaki T, Mizota A, Yokoyama T, Tanaka M, et al. Central retinal vein occlusion caused by human herpesvirus 6. *J AAPOS* 2006;43(3):176-8.
- (220) Jalali S, Kolari RS, Pathengay A, Athmanathan S. Severe hemorrhagic retinopathy as initial manifestation of acute retinal necrosis caused by herpes simplex virus. *Indian J Ophthalmol* 2007;55(4):308-10.
- (221) Lewallen S, Bronzan RN, Beare NA, Harding SP, Molyneux ME, Taylor TE. Using malarial retinopathy to improve the classification of children with cerebral malaria. *Trans R Soc Tropical Med Hygiene* 2008;102(11):1089-1094.
- (222) Beare NA, Southern C, Chalira C, Taylor TE, Molyneux ME, Harding SP. Prognostic significance and course of retinopathy in children with severe malaria. *Arch Ophthalmol* 2004;122(8):1141-7.
- (223) White VA, Lewallen S, Beare NA, Molyneux ME, Taylor TE. Retinal Pathology of Pediatric Cerebral Malaria in Malawi. *PLoS ONE* 2009;4(1):e4317.



- (224) Dinakaran S, Chan TK, Rogers NK, Brosnahan DM. Retinal hemorrhages in meningococcal septicemia. *J AAPOS* 2002;6(4):221-3.
- (225) Ong BB, Gole GA, Robertson T, McGill J, de Lore D, Crawford M. Retinal hemorrhages associated with meningitis in a child with a congenital disorder of glycosylation. *Forensic Sci Med Pathol* 2009;5(4):307-12.
- (226) Lopez JP, Roque J, Torres J, Levin AV. Severe retinal hemorrhages in infants with aggressive, fatal *Streptococcus pneumoniae* meningitis. *J AAPOS* 2010;14(1):97-8.
- (227) Vasconcelos-Santos DV, Machado Azevedo DO, Campos WR, Orefice F, Queiroz-Andrade GM, Carellos E, et al. Congenital Toxoplasmosis in Southeastern Brazil: Results of Early Ophthalmologic Examination of a Large Cohort of Neonates. *Ophthalmology* 2009;116(11):2199-205.
- (228) Currie AD, Bentley CR, Bloom PA. Retinal haemorrhage and fatal stroke in an infant with fibromuscular dysplasia. *Arc Dis Child* 2001;84:263-4.
- (229) Ko F, Knox DL. The ocular pathology of Terson's syndrome. *Ophthalmology* 2010;117:1423-9.
- (230) Gicquel J, Bouhamida J, Dighiero P. Ophthalmological complications of the asphyxiophilic "scarf game" in a 12-year-old child. *J Fr Ophtalmol.* 2004;27(10):1153-5.
- (231) Lim Z, Tehrani NN, Levin AV. Retinal haemorrhages in a preterm infant following screening examination for retinopathy of prematurity. *Br J Ophthalmol* 2006;90(6):799-800.
- (232) Azad RV, Chandra P, Pal N, Singh DV. Retinal haemorrhages following Retcam screening for retinopathy of prematurity. *Eye* 2005;19(11):1221-2.

### 3.3.3. Period of birth haemorrhage

*Clinical question: For how long can birth-related retinal haemorrhages persist?*

#### **Evidence from previous review 1999**

RHs are common at birth, occurring in between 2.6% and 59% of newborn infants (135);(144);(145);(233). The RHs are present after birth and disappear rapidly with very few exceptions. The finest nerve fibre layer (NFL) haemorrhages can disappear in 24 hours, whilst even extensive NFL haemorrhages are usually gone within a few days. Half of all haemorrhages disappear within 48 hours (135) and 2.6% persisted at 72-120 hours after birth (144). Larger subhyaloid and larger intraretinal haemorrhages seem to persist for the longest time (145). Most neonatal retinal haemorrhages have no visual sequelae (234);(235), although occasional cases of long-term impairment have been reported in association with macular haemorrhages (236).

#### **Evidence from review update 2012**

Emerson et al examined 149 newborns within 30 hours of birth using binocular indirect ophthalmoscopy (237). Intraretinal haemorrhage was present in 34% of newborns and varied from a single dot haemorrhage in one eye to bilateral widespread haemorrhages, occasionally with white centres. The incidence of haemorrhage was higher for vacuum-assisted (75%) than normal vaginal delivery (33%) and was least if born by caesarean section (7%). The mean maternal age was greater for infants with retinal haemorrhage. Within two weeks after birth, retinal haemorrhage resolved in 86% of eyes, and at four weeks no intraretinal haemorrhage was detected, although a single subretinal haemorrhage persisted until six weeks after birth (237). Hughes et al reported similar findings (152). RHs occurred in 34% of births (77% if vacuum; 30% if forceps or normal vaginal

delivery (NVD); 8% if caesarean section). All haemorrhages were intraretinal and all resolved by 16 days of age except two infants (post vacuum birth) where a small number of discrete foveal haemorrhages persisted for up to two months after birth.

Conclusions: RHs are common in newborn babies; they are more prevalent in assisted births and least common after elective caesarean sections. They may range from few to widespread bilateral RHs. They largely resolve within two weeks though dense foveal intraretinal RH may persist for months.

D
---

### References

- (135) Giles CL. Retinal haemorrhages in the newborn. *Am J Ophthalmol* 1960;49:1005-10.
- (144) Sezen F. Retinal haemorrhages in newborn infants. *Br J Ophthalmol* 1970;55(4):248-53.
- (145) Baum JD, Bulpitt CJ. Retinal and conjunctival haemorrhage in the newborn. *Arch Dis Child* 1970;45:344-9.
- (152) Hughes LA, May K, Talbot JF, Parson MA. Incidence, distribution and duration of birth-related retinal hemorrhages: A prospective study. *J AAPOS* 2006;10(2):102-106.
- (233) Von Barsewisch B. Perinatal retinal haemorrhages: morphology, aetiology and significance. Berlin: Springer-Verlag; 1979.
- (234) Bonamour G. Le pronostic éloigné des hémorragies rétiniennes du nouveau-né. *Bull Mem Soci Franc Ophtalmol* 1949;62:227-36.
- (235) Von Noorden GK, Khodahoust A. Retinal hemorrhage in newborns and organic amblyopia. *Ann Ophthalmol* 1973;89:91-3.
- (236) Zwaan J, Cardenas R, O'Connor PS. Long-term outcome of neonatal macular haemorrhage. *J AAPOS* 1997;(34):286-8.
- (237) Emerson M, Pieramici D, Stoessel K, Berreen J, Gariano R. Incidence and rate of disappearance of retinal hemorrhage in newborns. *Ophthalmology* 2001;108(1):36-9.

### 3.3.4. Bleeding diathesis or blood dyscrasia

*Clinical question: Can bleeding diathesis or blood dyscrasia cause retinal haemorrhages similar to those seen in child abuse?*

#### **Evidence from previous review 1999**

A report suggests that a bleeding diathesis should be excluded in all suspected abuse cases (238). RHs in leukaemia can be difficult to distinguish from those in AHT, but the abnormal white cell count would help to distinguish leukaemia from AHT (195);(239). Extensive RHs have been described in Von Willebrand's disease (240), vitreous haemorrhages in protein C deficiency (241);(242). Bleeding disorders may co-exist with Abusive Head Trauma (243);(244), and a haematological opinion should be sought.

#### **Evidence from review update 2012**

A case of minor head injury in an 11 month old who fell backwards from standing height onto a wooden floor, sustaining extensive SDH and bilateral, extensive, multilayered RHs. Original investigations for coagulopathy were normal, abuse was diagnosed, but six months later a re-evaluation of the bloods suggested mild von Willebrand's disease which was then accepted as a cause of the bleeding

(245). A 14 year old boy with acute myeloid leukaemia is described as having bilateral, extensive multilayered RHs, including perimacular folds, in the absence of trauma (246). Other bleeding disorders with RHs described include Hemansky-Pudlak syndrome (247), where a seven week old infant presented with SDH and RHs in the posterior pole, involving subhyaloid, intraretinal, and subretinal on one side, and a single macular haemorrhage in the other eye; a case of haemophagocytic lymphohistiocytosis in an 11 day old, who presented collapsed with SDH and peripheral perivascular RHs (248); a 36 day old pre-term infant being examined for possible ROP who was found to have bilateral retinal and vitreous haemorrhage in the absence of ROP with low fibrinogen levels (249); an eight year old boy who presented four months after bone marrow transplant for aplastic anemia, who was noted to have atypical ischaemic maculopathy, including scattered flame shaped haemorrhages bilaterally (250).

Conclusion: Bleeding diathesis should be excluded in all suspected cases of AHT with RHs <sup>(see footnote2)</sup>.

D
---

### References

- (195) Guyer DR, Schachat AP, Vitale S, Markowitz JA, Braine H, Burke PJ, et al. Leukemic retinopathy. Relationship between fundus lesions and hematologic parameters at diagnosis. *Ophthalmology* 1989;96(6):860-4.
- (238) Gayle MO, Hered RW, Harwood-Nuss A, Kissoon N. Retinal haemorrhages in the young child: A review of etiology, predisposed conditions, and clinical implications. *J Emerg Med* 1995;13(233):239.
- (239) Shaw NJ, Eden OB. Juvenile chronic myelogenous leukemia and neurofibromatosis in infancy presenting as ocular hemorrhage. *Pediatr Hematol-Oncol* 1989;6:23-6.
- (240) Shiono T, Abe S, Watabe T, Noro M, Tamai M, Akutso Y. Vitreous, retinal and subretinal haemorrhages associated with von Willebrand's syndrome. *Graefes Arch Clin Exp Ophthalmol* 1992;230:496-7.
- (241) Pulido JS, Lingua RW, Cristol BS, Byrne SF. Protein C deficiency associated with vitreous hemorrhage in a neonate. *Am J Ophthalmol*. 1987;104(546):547.
- (242) Cassels-Brown A, Minford AMB, Chatfield SL, Bradbury JA. Ophthalmic manifestations of neonatal protein C deficiency. *Br J Ophthalmol* 1994;78:486-7.
- (243) O'Hare AE, Eden OB. Bleeding disorders and non-accidental injury. *Arch Dis Child* 1984;9:860-4.
- (244) Hymel KP, Abshire TC, Luckey DW, Jenny C. Coagulopathy in pediatric abusive head trauma. *Pediatrics* 1997;99:371-5.
- (245) Stray-Pedersen A, Omland S, Nedregard B, Klevberg S, Torleiv O. An infant with subdural hematoma and retina hemorrhages: Does von Willebrand disease explain the findings? *Forensic Sci Med Pathol* 2010; 7:37-41.
- (246) Bhatnagar A, Wilkinson LB, Tyagi AK, Wilshaw HE. Subinternal limiting membrane hemorrhage with perimacular fold in leukemia. *Arch Ophthalmol* 2009;127(11):1548-50.
- (247) Russell-Eggitt IM, Thompson D, Khair K, Liesner R, Hann I. Hermansky-Pudlak syndrome presenting with subdural haematoma and retinal haemorrhages in infancy. *J R Soc Med*. 2000;93(11):591-2
- (248) Rooms L, Fitzgerald N, McClain KL. Hemophagocytic lymphohistiocytosis masquerading as child abuse: Presentation of three cases and review of central nervous system findings in hemophagocytic lymphohistiocytosis. *Pediatrics* 2003;111(5):636-40.

<sup>2</sup> Note that the handbook on Child Protection Companion edited by RCPCH (in press) includes details on how to exclude bleeding diatheses (see <http://www.rcpch.ac.uk/child-health/standards-care/child-protection/publications/child-protection-publications>).

- (249) Marshman W, Adams G, Ohri R. Bilateral vitreous hemorrhages in an infant with low fibrinogen levels. *J AAPOS*. 1999;3(4):255-6
- (250) Naithani P, Venkatesh P, Sankaran P, Vashisht N, Garg S. Early-onset atypical ischemic maculopathy after bone marrow transplantation. *J AAPOS* 2010;14(2):187-9.

### 3.3.5. Confounding conditions

#### 3.3.5.1. Seizures

*Clinical question: Can seizures alone cause retinal haemorrhages as seen in cases of child abuse?*


#### **Evidence from previous review 1999**

There were no retinal haemorrhages in 560 cases of adult seizures (251). There were no retinal haemorrhages seen in 65 children after seizures (128);(252). There was one case of extensive retinal haemorrhages in an adult after status epilepticus (253). It was considered that convulsions alone in children rarely, if ever, cause retinal haemorrhages.

#### **Evidence from review update 2012**

A number of studies have looked at children presenting with recent onset seizures. Known cases of trauma were excluded and an ophthalmologist performed a fundus examination with an indirect ophthalmoscope within 48 or 72 hours of admission. In a study of 153 children aged less than two years, only one retinal haemorrhage in an eight month old child was detected (254). A study of 31 children reported two children each with only one retinal haemorrhage (255). A further study examined 182 children under two years and found retinal haemorrhages in two cases that also had subdural haemorrhages (SDH) and were considered to be due to inflicted head injury (256). The reported cases of RH attributed to convulsions seem to be confined to very few haemorrhages located close to the optic discs.

Conclusions: Retinal haemorrhages are rarely caused by seizures alone. If RHs are found in a child with convulsions, this finding should prompt a search for another cause.



#### *References*

- (128) Sandramoulli S, Robinson R, Tsaloumas M, Willshaw H. Retinal haemorrhages and convulsions. *Arch Dis Child* 1997;76(5):449-51.
- (251) Kirby S, Sadler R. Injury and death as a result of seizures. *Epilepsia* 1995;36(1):25-8.
- (252) Tyagi AK, Scotcher S, Kozeis N, Willshaw H. Can convulsions alone cause retinal haemorrhages in infants? *Br J Ophthalmol* 1998;82:659-60.
- (253) Feyi-Waboso AC, Beck L. Minerva column. *BMJ* 1997;314:688.
- (254) Mei-Zahav M, Uziel Y, Raz J, Ginot N, Wolach B, Fainmesser P. Convulsions and retinal haemorrhage: Should we look further? *Arch Dis Child* 2002;86:334-5.
- (255) Aghadoost D, Talebian A. Convulsions and retinal hemorrhages. *Indian Pediatr* 2004;41:1271-2.
- (256) Curcoy AI, Trenchs V, Morales M, Serra A, Pineda M, ou J. Do retinal haemorrhages occur in infants with convulsions? *Arch Dis Child* 2009;94:873-5.

### 3.3.5.2. Cardio-pulmonary resuscitation (CPR)

*Clinical question: Can cardio-pulmonary resuscitation cause retinal haemorrhages?*

#### **Evidence from previous review 1999**

Closed chest massage, even by trained doctors, can cause a marked rise in intracranial pressure (257). Violent chest compression in child abuse may cause retinal haemorrhages (157);(159). Attempted CPR by untrained individuals has been advanced as an innocent cause of retinal haemorrhages in a single case report (258) although AHT was not convincingly excluded.

There have been other reports of retinal haemorrhages occurring after CPR without other explanation for the haemorrhages (133);(259). One neonate with meconium aspiration who had CPR during the first day of life before being put onto ECMO suffered seizures with vitreous haemorrhages being noted on the 11th day. A further study found no case of retinal haemorrhage in their autopsy study of 169 cases, 131 of which had prolonged resuscitation (260).

Retinal haemorrhages were found on non-mydiatric ophthalmoscopy in only 1 of 45 children who had not had prior trauma and were successfully or unsuccessfully resuscitated: the child with RHs had severe arterial hypertension and seizures. Of 9 trauma victims, 5 had retinal haemorrhages; 4 of these were correctly suspected as being due to child abuse and the other had head and chest injuries in an automobile accident. A further 5 children could not be examined who had corneal clouding or miosis. The conclusion was that 'when retinal haemorrhage is detected in the pediatric patient after CPR, prior trauma should be assumed and retinal haemorrhage should not be attributed to the mechanical effects of CPR (157). Experimental evidence from studies on piglets showed no retinal haemorrhages despite high, monitored intra-cranial and intra-thoracic pressure (83).

Conclusion: CPR is very unlikely to cause retinal haemorrhages, even if carried out by unskilled individuals.

#### **Evidence from review update 2012**

A study reports a case of a preterm infant with retinopathy of prematurity (ROP) that had bilateral retinal haemorrhages following CPR. The infant was a black male infant born at 24 weeks with bilateral stage 3 ROP. His left eye had 7 clock hours of stage 3 plus and some intra-retinal haemorrhage with the right eye having no retinal haemorrhages. During intravenous sedation in preparation for laser treatment, the child suffered severe apnoea and needed 15 minutes of chest compression. Fundoscopy 90 minutes later showed multiple flame-shaped intraretinal haemorrhages, some with white centres, diffusely distributed throughout entire vascularised retina (including the posterior pole) in both eyes. The child's immature retina may have been a factor in the development of these haemorrhages (261).

Conclusion: CPR is very unlikely to cause retinal haemorrhages, even if carried out by unskilled individuals. A caveat could be added to exclude very premature children on the basis of the case report.

D
---

## References

- (83) Fackler JC, Berkowitz ID, Green WR. Retinal hemorrhages in newborn piglets following cardiopulmonary resuscitation. *Am J Dis Child* 1992;146(11):1294-6.
- (133) Goetting MG, Sowa B. Retinal hemorrhage after cardiopulmonary resuscitation in children: An etiologic reevaluation. *Pediatrics* 1990;85:585-8.
- (157) Kanter RK. Retinal hemorrhage after cardiopulmonary resuscitation or child abuse. *J Pediatr* 1986;108(3):430-2.
- (158) Tomasi LG, Rosman NP. Purtscher retinopathy in the battered child syndrome. *Am J Dis Children* 1975;129(11):1335-7.
- (159) Carter J, McCormick AQ. Whiplash shaking syndrome: Retinal hemorrhages and computerised axial tomography of the brain. *Child Abuse Neglect* 1983;279-86.
- (257) Rogers MC, Nugent SK, Stidham GL. Effects of closed chest massage on intracranial pressure. *Crit Care Med* 1979;7:454-6.
- (259) Bacon CJ, Sayer GC, Howe J. Extensive retinal haemorrhages in infancy: An innocent cause. *BMJ* 1978;1:281.
- (259) Weedn VW, Mansour AM, Nichols MM. Retinal hemorrhage in an infant after cardiopulmonary resuscitation. *Am J Forensic Pathol* 1990;11:79-82.
- (260) Gilliland MG, Luckenbach MW. Are retinal hemorrhages found after resuscitation attempts? *Am J Forensic Med Pathol* 1993;14:187-92.
- (261) Polito A, Au Eong K-G, Repka MX, Pieramici DJ. Bilateral retinal hemorrhages in a preterm infant with retinopathy of prematurity immediately following cardiopulmonary resuscitation. *Arch Ophthalmol* 2001;119(6):913-4.

### 3.3.5.3. Choking, gagging and vomiting

*Clinical question: Can prolonged vomiting, or gagging cause retinal haemorrhages?*

#### **Evidence from previous review 1999**

Various causes of Valsalva manoeuvre may be associated with retinal haemorrhage in adults (262) but no cases have been described in children

#### **Evidence from review update 2012**

The medical literature in this area remains limited. Geddes and Talbert (263) published a hypothesis paper in 2006 suggesting a computer modelling approach to investigate feeding accidents as a trigger for intracranial and retinal bleeding. A dynamic circulatory model of a three-month-old infant was induced to “cough” and the response to changes in physiological variables monitored. The authors proposed that paroxysmal coughing could cause intracranial and intraluminal pressures to rise exponentially to approach a level which could be sufficient to damage veins. Barnes et al (69) reported a four and half month old male infant with no previous health problems in whom dysphagic choking was suggested as a component in the production of retinal haemorrhages and subdural haemorrhages. However the authors indicated that the carer’s account was inconsistent with the clinical and imaging features and that AHT could not be ruled out. Herr et al (75) examined 100 infants with hypertrophic pyloric stenosis. No retinal haemorrhages were identified in any of the children although one had developed facial petechiae and two had subconjunctival haemorrhages. However, although a dilated

fundoscopic examination was performed in all, an ophthalmologist did not necessarily carry this out.

Conclusion: RHs appear to be very rare (if they occur at all) as a result of Valsalva manoeuvre in young children.

D

### References

- (69) Barnes PD, Galaznik J, Gardner H, Shuman M. Infant acute life-threatening event–dysphagic choking versus nonaccidental injury. *Sem Pediatr Neurol* 2010;17(1):7-11.
- (75) Herr S, Pierce MC, Berger RP, Ford H, Pitetti RD. Does valsalva retinopathy occur in infants? An initial investigation in infants with vomiting caused by pyloric stenosis. *Pediatrics* 2004;113(6):1658-61.
- (262) Duane TD. Valsalva hemorrhagic retinopathy. *Transactions of the Am Ophthalmol Soc* 1972;70:298-313.
- (263) Geddes JF, Talbert DG. Paroxysmal coughing, subdural and retinal bleeding: a computer modelling approach. *Neuropathol Appl Neuro* 2006;32(6):625-34.

### 3.3.5.4. Apparent life threatening event (ALTE)

*Clinical question: Is an apparent life threatening event associated with retinal haemorrhages?*

#### **Evidence from review update 2012**

An apparent life threatening event in an infant is defined as a condition characterized by some combination of apnoea, colour change, marked change in muscular tone, choking or gagging and is frightening to the observer (70).

In a study of 128 infants (70) who presented to the emergency department with an ALTE where the mean age of the infants was 2.1 months (range 0.07- 16 months) 71 infants had a fundoscopic examination by a paediatric ophthalmologist. There was one child in this group who had a diagnosis of abuse with bilateral RHs, rib fractures and a confession of vigorous shaking by the father. In a series reporting on the ophthalmic findings 120 children (less than 12 months of age) who presented with an ALTE only the children diagnosed with AHT had retinal haemorrhages. There were no retinal findings in 114 children with non AHT (71). In a recent prospective study of 108 infants with a median age of 1.5 months (range 0.5-13.8 months) who presented with an ALTE a detailed fundoscopic examination by an ophthalmologist using indirect ophthalmoscopy and dilated pupils revealed no retinal haemorrhages. Combining these studies (70);(72) reporting on 292 children less than 24 months who presented clinically with an ALTE, not due to AHT, none of the children had any retinal haemorrhages.

Conclusion: ALTE has not been reported to be associated with RHs.

D

### References

(70) Pitetti RD, Maffei F, Chang K, Hickey R, Berger R, Pierce MC. Prevalence of retinal hemorrhages and child abuse in children who present with an apparent life-threatening event. *Pediatrics* 2002;110(3):557-62.

(71) Altman RL, Forman S, Brand DA. Ophthalmologic findings in infants after an apparent life-threatening event. *Eur J Ophthalmol* 2007;17:648-53.

(72) Curcoy AI, Trenchs V, Morales M, Serra A, Pou J. Retinal hemorrhages and apparent life-threatening events. *Pediatr Emerg Care* 2010;26(2):118-20.

### 3.3.5.5. Vaccinations and retinal haemorrhages

*Clinical question: Are vaccinations associated with retinal haemorrhages?*

#### **Evidence from review update 2012**

A number of authors have hypothesized a link between the presence of multiple bone fractures, sub-dural haemorrhages and retinal haemorrhages and routine vaccination due to elevated histamine and reduction of vitamin C (264);(265). However, this remains unsubstantiated by clinical evidence and there are no reported cases in the literature of retinal haemorrhages occurring following childhood immunizations although cases of retinal vein occlusion have been associated with hepatitis B vaccination in adults (266);(267).

**Conclusion:** The association of RH and vaccinations has not been reported in children.

#### *References*

(264) Clemetson CAB. Elevated blood histamine caused by vaccinations and Vitamin C deficiency may mimic the shaken baby syndrome. *Med Hypotheses* 2003;62(4):533-6.

(265) Gardner HB. Immunisations, retinal and subdural hemorrhages: Are they related? *Med Hypotheses* 2005;64(3):663.

(267) Granel B, Disdier P, Devin F, Swiader L, Riss JM, Coupier L, et al. Occlusion of the central retinal vein after vaccination against viral hepatitis B with recombinant vaccines. 4 cases. *Presse Med* 1997;26(2):62-5.

(266) Devin F, Roques G, Disdier P, Rodor F, Weiller P. Occlusion of central retinal vein after hepatitis B vaccination. *Lancet* 1996;347(9015):1626.

### 3.3.6. Other causes of retinal haemorrhage

*Clinical question: Do high cervical injuries from any other source give rise to retinal haemorrhages?*

#### **Evidence from previous review 2004**

Cervical injuries alone did not give rise to retinal haemorrhages but could give rise to apnoea. Inflicted cervical spinal injury coupled with circulatory collapse had the potential to produce hypoxic ischaemic encephalopathy (268);(269).

#### **Evidence from review update 2012**

There were no further studies that reported specifically on high cervical injuries and retinal haemorrhages.

Two studies reported the results of biomechanical experiments on whether forceful rocking or bouncing in baby seats could account for subdural and retinal bleeding



and may involve high cervical injury in the process. The experiments were conducted to assess a carer's account about how infants under their care suffered injury. Both infants were eight weeks of age and had suffered bilateral subdural and bilateral retinal bleeding. The retinal bleeding was not described by an ophthalmologist in either case.

The outcomes in the two experiments differ with Jones (43) reporting that violent rocking was insufficient to cause the threshold values for subdural bleeding, whilst the study by de San Lazaro (57) reported that violent rocking in a baby chair (which may have included head impact on the floor) could give rise to a sufficient acceleration/deceleration to cause head injury. This study therefore gives the mechanism as acceleration /deceleration in the baby chair similar to shaking.

A case report of a 21 month old child who died after a short fall was found at autopsy to have a fatal cervico medullary cord lesion and a cranial impact site (190). The child suffered bilateral subdural and subarachnoid haemorrhage with bilateral retinal bleeding. The child was reported to have had bilateral retinal haemorrhages and perimacular folds whilst on intensive care, but at autopsy the retinal bleeding was identified in the ganglion cell layer, more anteriorly than posteriorly, with bilateral optic nerve sheath haemorrhage. The child was confirmed as having raised intracranial pressure on intracranial monitoring.

Conclusions: These studies describe a mechanism of injury, which may involve the cervical cord but do not prove that high cervical injury alone can give rise to retinal bleeding.

E
---

### References

- (43) Jones MD, James DS, Cory CZ, Leadbeatter S, Nokes LDM. Subdural haemorrhage sustained in a baby-rocker?: A biomechanical approach to causation. *Forensic Sci Int* 2003;131(1):14-21.
- (57) de San Lazaro C, Harvey R, Ogden A. Shaking infant trauma induced by misuse of a baby chair. *Arch Dis Child* 2003;88(7):632-4.
- (190) Barnes PD, Krasnokutsky MV, Monson KL, Ophoven J. Traumatic spinal cord injury: Accidental versus nonaccidental injury. *Sem Pediatr Neurol* 2008;15(4):178-84.
- (268) Koch LE, Bierdermann H, Saternus K-S. High cervical stress and apnoea. *Forensic Sci Int* 1998;97(1):1-9.
- (269) Bohn D, Armstrong DC, Becker L, Humphreys RP. Cervical spine injuries in children. *J Traum* 1990;30(4):463-9.

### 3.3.7. Short distance falls

*Clinical question: Can short distance falls cause retinal haemorrhages?*

#### **Evidence from previous review 2004**

Tangential acceleration associated with shearing forces is well documented as causing retinal haemorrhages but the situation is less clear with short distance falls. Short distance household falls were found to be neurologically benign with no associated retinal haemorrhages even in the presence of skull fractures (11);(18). Accidental trauma, or rough play would be unlikely to cause retinal haemorrhages in children less than two years of age (31);(32).

A few reports have described unilateral or bilateral haemorrhages in children following short falls (38);(46). However, it seems clear that minor falls can, only exceptionally, give rise to subdural and retinal bleeding ([see section 3.1.3](#)).

### **Evidence from review update 2012**

A group studied the association of haemorrhages and epidural haematomas associated with accidental head trauma following short distance falls. Of the nine children included in the study, five were found to have retinal haemorrhages. These were all superficial, few in number, confined to the posterior pole and no deep or sub retinal haemorrhages were noted. The authors pointed out that all the examinations were done after surgical evacuation of the haematoma that may have had an impact on the development of the haemorrhages (169).

Minor head trauma, in the absence of underlying medical conditions such as osteogenesis imperfecta type I, is only very rarely associated with severe intracranial injury or retinal haemorrhage, particularly the extensive multi-layered haemorrhages extending to the ora serrata, as seen in two thirds of the victims with SBS (270). In the absence of a known major accidental injury involving severe intracranial trauma, such as a crush injury or high-force MVC, extensive retinal haemorrhages are highly indicative of occult, severe intentional injury (23). Although the rate of retinal haemorrhage after severe accidents such as motor vehicle accidents is higher, the medical literature continues to confirm the rarity (<3%) of haemorrhagic retinopathy after other forms of minor accidental trauma. When it does occur, the haemorrhages are usually few or at most modest in number and rarely extend beyond the posterior pole (271).

A prospective study that looked at the incidence of RH in 154 children younger than two years that had sustained a vertical fall. The prevalence of RH was found to be 1.95% (three patients). Of these, all were unilateral and associated with epidural haematomas and a midline shift. They concluded that accidental short distance falls could result in RH but these were unilateral, small and isolated as opposed to the diffuse, deep and bilateral RH seen in AHT (45).

A retrospective review of 287 children found that for falls less than four feet, none of the children in the accidental group had RH and 25% of those in the abused category did. They concluded, “RHs are virtually never seen in short falls“ (112) A prospective study that looked at 45 cases of confessed inflicted head injury and 39 cases of accidental trauma found RH in 56.8% and 15% in the two groups respectively. In the accidental trauma group, five of the six cases had mild, flame shaped haemorrhages while one case that sustained facial trauma and direct impact to the globe had a severe RH (28).

A case of an 11-month-old Asian infant who sustained RH and SDH following a witnessed fall backwards from a sitting position has been reported. However, the ophthalmic examination was carried out following surgical evaluation of the intracranial hematoma that may have affected the RH (39).

An update on SBS reported that extensive retinal haemorrhages are not caused by short falls (272).

A prospective study looked at 87 children hospitalised with head trauma over a two-year period and divided them into accidental and AHT groups. Retinal haemorrhages seen in children with accidental head trauma were most often unilateral, involved a single retinal layer and in 42% of cases were a single haemorrhage. In contrast, abusive head trauma is associated with multiple RHs, usually bilateral, involving the preretinal and intraretinal layers, covering the macula and extending to the periphery of the retina. Thus it is not the presence of RH but the location and number that is most helpful in distinguishing accidental from inflicted head injury (117).

Conclusions: Short distance falls are unlikely to cause retina haemorrhages if the injury is not severe. In rare cases accidental falls, especially those associated with SDH may be associated with RHs, but these tend to be unilateral, localised and superficial.

C, D

### References

- (11) Duhaime AC, Alario AJ, Lewander WJ, Schut L, Sutton LN, Seidl T, et al. Head injury in very young children: Mechanisms, injury types, and ophthalmologic findings in 100 hospitalized patients younger than 2 years of age. *Pediatrics* 1992;90(2):179-85.
- (18) Buys YM, Levin AV, Enzenauer RW, Elder JE, Letourneau MA, Humphreys RP, et al. Retinal findings after head trauma in infants and young children. *Ophthalmology* 1992;99(11):1718-23.
- (23) Kivlin J, Currie M, Greenbaum V, Simons K, Jentzen J. Retinal hemorrhages in children following fatal motor vehicle crashes: A case series. *Arch Ophthalmol* 2008;126(6):800-4.
- (28) Vinchon M, de Foort-Dhellemmes S, Desurmont M, Delestret I. Confessed abuse versus witnessed accidents in infants: Comparison of clinical, radiological, and ophthalmological data in corroborated cases. *Childs Nervous Syst* 2010;26(5):637-45.
- (31) Geddes JF, Hackshaw AK, Vowles GH, Nickols CD, Whitwell H. Neuropathology of inflicted head injury in children. I. Patterns of brain damage. *Brain* 2001;124(7):1290-8.
- (32) Geddes JF, Vowles GH, Hackshaw AK, Nickols CD, Scott IS, Whitwell HL. Neuropathology of inflicted head injury in children. II. Microscopic brain injury in infants. *Brain* 2001;124(7):1299-1306.
- (38) Plunkett J. Fatal pediatric head injuries caused by short-distance falls. *Am J Forensic Med Pathol* 2001;22(3):332-6.
- (39) Gardner HB. A witnessed short fall mimicking presumed shaken baby syndrome (inflicted childhood neurotrauma). *J Pediatr Neurosurg* 2007;43(5):433-5.
- (45) Trenchs V, Curcoy A, Morales M, Serra A, Navarro R, Pou J. Retinal haemorrhages in head trauma resulting from falls: Differential diagnosis with non-accidental trauma in patients younger than 2-years of age. *Childs Nervous Syst* 2008;24(7):815-20.
- (46) Christian CW, Taylor AA, Hertle RW, Duhaime AC. Retinal hemorrhages caused by accidental household trauma. *J Pediatr* 1999;135(1):125-7.
- (112) Togioka BM, Arnold MA, Bathurst MA, Ziegfeld SM, Nabaweesi R, Colombani PM, et al. Retinal hemorrhages and shaken baby syndrome: An evidence-based review. *J Emerg Med* 2009;37(1):98-106.
- (117) Bechtel K, Stoessel K, Leventhal JM, Ogle E, Teague B, Laviertes S, et al. Characteristics that distinguish accidental from abusive injury in hospitalized young children with head trauma. *Pediatrics* 2004;114(1):165-8.
- (169) Forbes BJ, Cox M, Christian CW. Retinal hemorrhages in patients with epidural hematomas. *J AAPOS* 2008;12(2):177-180.
- (270) Ganesh A, Stephens D, Kivlin JD, Levin AV. Retinal and subdural haemorrhages from minor falls. *Br J Ophthalmol* 2007;91(3):396-7.

(271) Morad Y, Wagnanski-Jaffe T, Levin AV. Retinal haemorrhage in abusive head trauma. *Clin Exp Ophthalmol* 2010;38(5):514-20.  
(272) Mungan NK. Update on shaken baby syndrome: *Ophthalmology*. *Curr Opin Ophthalmol* 2007;18(5):392-7.

### 3.3.8. Raised intracranial pressure

*Clinical question: Do retinal haemorrhages similar to AHT occur with raised intracranial pressure?*

#### **Evidence from review update 2012**

Animal studies have demonstrated that retinal haemorrhages can be induced by a rapid marked rise in intracranial pressure (ICP) to the point where consciousness is impaired (273).

In adults humans, retinal and optic nerve sheath haemorrhage occur when there is very marked increase in intracranial pressure (274), with emphasis on rapidity of onset (179);(275);(276).

A number of case reports provide additional evidence that retinal haemorrhages occur with acute extreme ICP rise.

In two adults studies inadvertent iatrogenic experiments of this phenomenon have been reported. A patient suffered brief acute ICP rise secondary to compression of a meningocele during a routine medical investigation, resulting in bilateral retinal haemorrhages (277). Another patient developed bilateral retinal haemorrhages when subject to accidental severe elevation in preoperative intraventricular pressure (278).

There have been two case reports demonstrating that infants develop extensive retinal and optic nerves sheath haemorrhages with severe ICP rise (141);(167). The retinal haemorrhages in the two infant cases were different to those reported in adults, with a wider distribution throughout the retina, and presence in different layers (141);(167). Both infants who were 7 months old had ruptured intracranial aneurysms with subarachnoid haemorrhages. In one infant (141) the ICP that was measured was high and this infant had extensive unilateral, multilayered retinal haemorrhages extending from the posterior pole to the periphery of the retina. In the second infant (167) who died, acute raised ICP was diagnosed on the postmortem findings of diffuse cerebral oedema and a subarachnoid haemorrhage. This child had bilateral multiple multilayered retinal haemorrhages which were distributed in the posterior pole and periphery.

The intracranial bleeding present in these cases does not seem to be the direct cause of retinal haemorrhages: only one child, aged 7 years, developed retinal haemorrhages in a series of 57 children with intracranial haemorrhage, and, whilst not explicitly stated in the article, this child had marked intracranial midline shift and/or large volume parenchymal cerebral haemorrhage that may have reflected marked intracranial pressure elevation (47).

As part of a wide-ranging study a series of children with apparent abusive head trauma, evaluation was made to see if there was a correlation between presumed signs that might suggest raised intracranial pressure and eye findings (29). No

relationship was identified however intracranial pressure was not measured. Instead, a correlation was found between severity of cranial injury and eye findings.

Conclusion: Experimental and clinical data demonstrate that an acute dramatic rise in intracranial pressure (ICP) may produce unilateral or bilateral retinal haemorrhages in infants that resemble those reportedly caused by abusive head trauma.

C, D
------

### References

- (29) Morad Y, Kim YM, Armstrong DC, Huyer D, Mian M, Levin AV. Correlation between retinal abnormalities and intracranial abnormalities in the shaken baby syndrome. *Am J Ophthalmology* 2002;134(3):354-9.
- (47) Schloff S, Mullaney PB, Armstrong DC, Simantirakis E, Humphreys RP, Myseros JS, et al. Retinal findings in children with intracranial hemorrhage. *Ophthalmology* 2002;109(8):1472-6.
- (141) Bhardwaj G, Jacobs M, Moran K, Tan K. Terson syndrome with ipsilateral severe hemorrhagic retinopathy in a 7-month-old child. *J AAPOS* 2010;14(5):441-443.
- (167) Mena OJ, Paul I, Reichard RR. Ocular findings in raised intracranial pressure: A case of Terson syndrome in a 7-month-old infant. *Am J Forensic Med Pathol* 2011;32(1):55-7.
- (179) Muller PJ, Deck JH. Intraocular and optic nerve sheath hemorrhage in cases of sudden intracranial hypertension. *J Neurosurg* 1974;41(2):160-6
- (273) Hedges T. A correlative study of orbital vascular and intracranial pressure in the Rhesus monkey. *Trans Am Ophthalmol Soci* 1963;61:589-637.
- (274) Walsh FB, Hedges TR. Optic nerve sheath hemorrhage. *Am J Ophthalmol* 1951;34(4):509-27.
- (275) Vanderlinden RG, Chisholm LD. Vitreous hemorrhages and sudden increased in intracranial pressure. *J Neurosurg* 1974;41(2):167-76.
- (276) Medele RJ, Stummer W, Mueller AJ, Steiger H-J, Reulen H-J. Terson's syndrome in subarachnoid hemorrhage and severe brain injury accompanied by acutely raised intracranial pressure. *J Neurosurg* 1998;88:851-4.
- (277) Bekavac I, Halloran JL. Meningocele-induced positional syncope and retinal hemorrhage. *Am J Neuroradiol* 2003;24:838-9.
- (278) Hoving EW, Rahmani M, Los LI, de Lavalette VWR. Bilateral retinal hemorrhage after endoscopic third ventriculostomy: iatrogenic Terson syndrome. *J Neurosurg* 2009;110(5):858-60.

### 3.3.9. Crush injury

*Clinical question: What are the ocular findings in crush injury?*

#### **Evidence from review update 2012**

A crush head injury occurs when the head is trapped between two objects or hard surfaces resulting in the application of bilateral, static, compressive forces on the head. The forces are applied more slowly and over a larger area compared to impact injury and result in deformation of the skull with cranial fractures (190).

There have been a small number of case reports and a retrospective review of the ocular findings in crush injury to the head in children. In the case reports all the children had sustained skull fractures.

Lantz et al (118) described a 14-month-old child who died after head trauma sustained by a TV set weighing 19.5 kg falling on top of him, which was determined as an accident after a forensic recreation of the scene. The child was found to have extensive bilateral retinal haemorrhages (dot and blot intra retinal and preretinal), which extended out to the ora with perimacular retinal folds. At autopsy optic nerve sheath haemorrhages were identified.

Lueder (193) reported a witnessed crush head injury in a four-month-old child sustained when a 12-year-old weighing 63 kg fell onto the infant's head. Ophthalmological examination revealed vitreous haemorrhage on the right side, and in the other eye retinoschisis with perimacular folds and diffuse, extensive, multi-layered retinal bleeding. Forensic examination determined that the injury was accidental.

Watts and Obi (49) reported the eye findings in a witnessed crush injury in 10 week-old infant and compared this with the ophthalmic examination in a 14 week-old infant with abusive head trauma and noted that similar ophthalmic findings could be seen in the two conditions. The ocular findings in the infant with crush injury were bilateral asymmetric retinal haemorrhages with a small number of posterior polar haemorrhages in one eye and in the other eye multi-layered, extensive retinal bleeding extending from the posterior pole to the ora, with retinoschisis and retinal folds. The child with abusive head trauma had one retinal haemorrhage in the right eye and in the left there were multi-layered, extensive retinal haemorrhages extending to the ora with a macular retinoschisis and retinal fold. Retinal photographs of the two cases show an almost identical fundal appearance.

Gnanaraj and colleagues (24) undertook a retrospective clinical and pathological review of paediatric crush head injuries. They reviewed two groups of patients, 16 children admitted to the hospital over a ten-year period 1992-2002 with head injuries caused by falling televisions (TV) and nine children who died from crush head injury between 1982-1989. In this time period 400 children had died and 169 were prospectively studied, and the nine children with crush head injury were identified from within this prospectively studied group. In the falling TV group 11/16 children had fundus examinations and one child had multiple preretinal and blot retinal haemorrhages extending from the posterior poles to the equator (it is not clearly stated whether this was unilateral or bilateral); this child had skull fractures. Four of the nine children dying of head injury had retinal haemorrhages, confined to the posterior pole in three patients and out to the ora in the other patient (who had been an unrestrained passenger involved in a road traffic accident). It is variably stated that all or 8/9 of these children had multiple skull fractures. The child with haemorrhages out to the ora also had optic nerve sheath haemorrhage. No child in either group had retinoschisis or retinal folds.

These cases indicate that extensive, multi-layered, bilateral retinal bleeding, or bilateral asymmetric bleeding, retinoschisis and perimacular folds can occur in isolated cases of accidental crush head trauma.

Conclusion: Few to widespread RHs have been reported in crush injuries to the infant head.

D

### References

- (24) Gnanaraj L, Gilliland MGF, Yahya RR, Rutka JT, Drake J, Dirks P, et al. Ocular manifestations of crush head injury in children. *Eye* 2007;21(1):5-10.
- (49) Watts P, Obi E. Retinal folds and retinoschisis in accidental and non-accidental head injury. *Eye* 2008;22(12):1514-6.
- (118) Lantz PE, Sinal SH, Stanton CA, Weaver RGJr. Perimacular retinal folds from childhood head trauma. *BMJ* 2004;328(7442):754-6.
- (190) Barnes PD, Krasnokutsky MV, Monson KL, Ophoven J. Traumatic spinal cord injury: Accidental versus nonaccidental injury. *Sem Pediatr Neurol* 2008;15(4):178-84.
- (193) Lueder GT, Turner JW, Paschall R. Perimacular retinal folds simulating nonaccidental injury in an infant. *Arch Ophthalmol* 2006;124(12):1782-3.

## 3.4. Guidance for the Ophthalmologist

### 3.4.1. Imaging of the retina in AHT

*Clinical question: Which methods are useful in imaging the retina in AHT?*

#### **Evidence from review update 2012**

Photography of retinal findings in abusive injury supplement detailed clinical descriptions while providing a permanent patient record. Hand held non-contact cameras have been used to capture high quality details of the posterior pole but do not lend themselves to imaging the retinal periphery. The RetCam (Clarity Medical Systems, Pleasanton, California) a contact digital fundus camera providing a 130° field of view of the retina allows documentation of findings in the posterior pole and periphery thus supporting the clinical notes on the patterns of retinal features in abusive head injury. In a pilot study the RetCam has been shown to provide high quality images at the bedside of retinal findings in abusive head trauma (279). When used as a telemedicine tool in abusive head trauma the RetCam 1200 had a 100% sensitivity and 85.7% specificity when compared to indirect ophthalmoscopy in detecting the presence or absence of retinal haemorrhages (110). Caution has been suggested when interpreting retinal haemorrhages seen after a previous examination with an indirect ophthalmoscope and scleral depression or imaging with the RetCam where the examination may induce retinal haemorrhages (231);(280). A prospective audit on pre and post RetCam imaging in 50 children screened for ROP failed to show any retinal haemorrhages (232).

The Retcam images of abusive trauma have been used to study inter and intra observer variability classifying the type (281), development of a new zonal classification (282) development of a retinal tool (283) and development of standardized reporting system (284) for describing retinal haemorrhages which may be used for clinical documentation and as evidence in legal proceedings.

Optical coherence tomography (OCT) has been applied to examination of infants subjected to abusive injury to define the relationship of the vitreoretinal interface

and the level of retinal pathology (78). The development of the hand held spectral domain OCT (Bioptigen Inc, North Carolina) allows imaging of a supine infant and has been successfully used to define both acute (285) and chronic (286) vitreoretinal findings in infants with abusive head trauma.

Conclusion: Imaging of the retina in abusive head trauma supports detailed documentation of retinal findings and provides a permanent record of retinal findings. The use of the OCT helps in elucidating the vitreoretinal relationships in AHT.

D, E
------

### References

- (78) Sturm V, Landau K, Menke MN. Optical coherence tomography findings in shaken baby syndrome. *Am J Ophthalmol* 2008;146(3):363-8.
- (110) Saleh M, Schoenlaub S, Desprez P, Bourcier T, Gaucher D, Astruc D, et al. Use of digital camera imaging of eye fundus for telemedicine in children suspected of abusive head injury. *Br J Ophthalmol* 2009;93(4):424-8.
- (231) Lim Z, Tehrani NN, Levin AV. Retinal haemorrhages in a preterm infant following screening examination for retinopathy of prematurity. *Br J Ophthalmol* 2006;90:799-800.
- (232) Azad RV, Chandra P, Pal N, Singh DV. Retinal haemorrhages following Retcam screening for retinopathy of prematurity. *Eye* 2005;19(11):1221-2.
- (279) Nakagawa TA, Skrinska R. Improved documentation of retinal hemorrhages using a wide-field digital ophthalmic camera in patients who experienced abusive head trauma. *Arch Pediatr Adolesc Med* 2001;155(10):1149-52.
- (280) Adams GGW, Clark BJ, Fang S, Hill M. Retinal haemorrhages in an infant following RetCam screening for retinopathy of prematurity. *Eye* 2004;18:652-3.
- (281) Mulvihill AO, Jones P, Tandon A, Fleck BW, Minns RA. An inter-observer and intra-observer study of a classification of RetCam images of retinal haemorrhages in children. *Br J Ophthalmol* 2011;95(1):99-104
- (282) Fleck BW, Tandon A, Jones PA, Mulvihill AO, Minns RA. An interrater reliability study of a new "zonal" classification for reporting the location of retinal haemorrhages in childhood for clinical, legal and research purposes. *Br J Ophthalmol* 2010;94(7):886-90.
- (283) Tandon A, McIntyre S, Yu A, Stephens D, Leiby B, Croker S, et al. Retinal haemorrhage description tool. *Br J Ophthalmol* 2011;95(12):1719-22.
- (284) Ng WS, Watts P, Lawson Z, Kemp A, Maguire S. Development and validation of a standardized tool for reporting retinal findings in abusive head trauma. *Am J Ophthalmol* 2012;154(2):333-9.
- (285) Scott AW, Farsiu S, Enyedi LB, Wallace DK, Toth CA. Imaging the infant retina with a hand-held spectral-domain optical coherence tomography device. *Am J Ophthalmol* 2009;147(2):364-73.
- (286) Muni RH, Kohly RP, Sohn EH, Lee TC. Hand-held spectral domain optical coherence tomography finding in shaken-baby syndrome. *Retina* 2010;30(4):S45-S50.

### 3.4.2. Procedures for the ophthalmologist and documentation

In the United Kingdom all hospitals that deal with children should have a Named Doctor (ND) and Named Nurse (NN) with particular expertise in child protection. They have responsibility for providing appropriate training and dissemination of local child protection guidelines. The ND is usually a consultant paediatrician but in an eye hospital the ND may be an Ophthalmologist who will need to have links with the Named Doctor (Paediatrician) in a neighbouring hospital.



Local guidelines should be readily available to all staff working with children: they identify key personnel together with relevant telephone numbers including those of the local Social Care and the Police Child Protection offices.

GPP

### **SUSPECTING CHILD MALTREATMENT (287)**

**All clinicians who are involved in the care of children should be familiar with the NICE guidance**

Many forms of child maltreatment may involve the eye. The Ophthalmologist mainly encounters physical abuse (indirect trauma, shaking, smothering and direct eye trauma) and occasionally induced or fabricated illness (Munchausen Syndrome by proxy), sexual abuse, neglect and emotional abuse.

### **WHAT TO DO IF YOU SUSPECT CHILD MALTREATMENT (288)**

Professionals should not intervene individually and all suspicions should be discussed with the safeguarding named nurse, social worker and ND. When child maltreatment is felt to be occurring there is a duty to inform the social care services verbally, and to follow up with a written referral.

1] If a trainee **suspects** maltreatment while conducting an ophthalmic examination local guidance should be followed with immediate discussion with a senior colleague, the senior nurse of the ward or department. The consultant ophthalmologist in charge of the case should confirm suspicions of maltreatment. Immediate involvement of a paediatrician is mandatory. There must be full **documentation** of the history including what is said by all parties and the physical findings must be noted with annotated drawings and photography where possible, noting the date and time of examination.

2] The Named Doctor or Nurse according to the hospital guidelines will provide advice. The responsibility for the further investigation and general medical management will be the paediatrician to whom the child has been referred. In hospitals where there is no designated child protection team and the assessment of a paediatrician is not immediately available the consultant ophthalmologist decides the lines of responsibility and discusses the case with the Designated Doctor.

3] In situations where eye hospitals are isolated from hospitals with a paediatric department and there are grave injuries or serious concerns about immediate risk to the child an escorted transfer of the case should be made to a neighbouring hospital where a paediatrician is available to examine the child. Statutory services (social care or police) must be involved in these cases.

4] If after consultation maltreatment is considered a possibility, a **referral** will be made to the Child protection Social Care Department. The responsibility for investigating suspected child abuse lies with the Local Authority Social Care department and the Police Child Protection team.

**LOCAL TELEPHONE CONTACTS**

Name Doctor \_\_\_\_\_

Named Nurse \_\_\_\_\_

Paediatrician \_\_\_\_\_

Designated Doctor \_\_\_\_\_

Local Social Care Services \_\_\_\_\_

Police Child Protection Team \_\_\_\_\_

**PRESENTATIONS, INJURIES OR BEHAVIOURAL STATES WHICH SHOULD ALERT THE CLINICIAN (289);(290)**

C, D

*Children at risk*

- Premature, disabled and excessively crying babies
- Siblings of abused children
- Children subject to a 'child protection plan' or 'children in need'
- Children of previously abusive parents

*Worrying factors in the presentation*

- The account of how the injuries occurred is inconsistent with their appearance, or the child's developmental level
- Changing history of how injuries occurred
- An inappropriate delay in presentation, or multiple other injuries present on examination
- Unexplained injuries
- Injuries in a pre-mobile infant
- Injuries blamed on siblings
- Multiple attendances at ED departments
- An unusual lack of parental concern at the severity or extent of injuries

*Eye signs suggestive of abuse (1);(2);(291)*

- Retinal haemorrhages
- Periocular bruising, lid lacerations
- Unexplained lens dislocation or cataract
- Unexplained conjunctival or corneal injuries especially in the lower half of the eye

*Other signs of abuse*

- Facial injuries in infants
- Injuries to non-mobile children
- Unexplained intracranial injury, including Subdural haemorrhages, hypoxic ischaemic injury,
- Human bite marks, require Forensic Odontologist to define if adult or not
- Bruising to non-mobile infants, or occurring over soft tissue areas such as cheeks, abdomen, inner thigh, upper arm. Likewise bruising to the neck, ear or hands in a young child
- Rib fractures in the absence of metabolic bone disease, or major trauma
- Long bone fractures in a child less than 18/12 of age without adequate accidental explanation, or multiple fractures of differing ages
- Contact burns on the back of the hand, back, shoulders or other unusual sites, including cigarette burns especially if multiple
- Immersion scalds, affecting the lower limbs +/- buttocks, perineum, or upper / lower limbs in 'glove and stocking' distribution
- Unusual injuries in inaccessible sited e.g. neck, armpit, groin etc.

*Neglect*

When a child presents dirty and unkempt, withdrawn, with poor social interaction or where there is a poor interaction between child and carer (disinterested, hostile, critical) this should be discussed with the hospital social worker/ paediatrician and consideration given to discussing this further with the GP or Health Visitor. Similar procedures should be observed when parents behave aggressively towards their children or show unusual behaviour towards hospital staff. This particularly applies if drug or alcohol abuse is suspected.

## **PRINCIPLES**

### *Informed Consent*

Medical examination consent should be obtained from an adult with parental responsibility for the child and from the child in a manner appropriate for age and level of understanding. Medical examination can be carried out with only the child's consent when in the opinion of the doctor the child has sufficient understanding.

### *Refusal to give consent*

If the carer or the child refuse to give consent or to co-operate with admission or treatment the doctor should inform the consultant in charge or the Named Doctor immediately: it may be necessary to consider emergency legal action initiated by the Social Care Services Department or the police.

### *Children's Rights*

Children have a right to know what is going on. They should not be made promises that cannot be kept and their views and wishes should be taken into consideration. They should be given the opportunity to explain what has happened to them but probing and confrontational "disclosure" interviews should not be carried out. Physical examinations should be few and carried out in a suitable environment by appropriately trained staff and in the presence of a trusted adult.

### *Parents or carers rights*

Carers are entitled to know what is going on and to be helped to understand the steps being taken but the child's welfare is paramount. If the child is under a Child Protection Order or accommodated by the Local Authority, arrangements for consent and contact with the family should be clarified with Social Care Services.

### *Evidence*

Therapeutic needs take precedence over evidential requirements. Accurate and unbiased records are essential for case conferences and legal proceedings, which may be the ophthalmologists duty to take part in.

**Standards of Ophthalmology Assessment** (78);(279);(281);(283);(285);(286);  
;(292);(293);(294)

**The ophthalmology assessment must be carried out by an ophthalmologist** (292). **External eye examination:** It is rarely possible to record the visual acuity in a very sick child and the reason should be recorded ( eg: sedated/ intubated ). The periocular area, eyelids, conjunctiva, anterior segments, pupillary reactions and ocular movements (or dolls head manoeuvre if necessary) of both eyes should be examined and the findings recorded.

Posterior segment examination: With agreement of the managing team the pupils should be dilated with short acting mydriatics (e.g. phenylephrine 2.5%, tropicamide 0.5%) and the fundus should be examined with an indirect ophthalmoscope and a condensing lens (20D ,28D, 30D or a 2.2 panfundoscopic lens).

The retinal findings should record whether retinal haemorrhages are present unilaterally or bilaterally and details of the layer of retinal involvement (preretinal, intraretinal and subretinal) the location in the retina (posterior pole /periphery), the

severity of the retinal haemorrhages in terms of number (few , many and too numerous to count) and size should be described. The presence or absence of additional features such as retinal folds, haemorrhagic retinoschisis and the presence of large macular or vitreous haemorrhages should be recorded. A standardised clinical proforma designed for documentation (example attached) should be used.

The use a hand held camera, the RetCam and a hand held OCT machine (Optical coherence tomography) help to record findings if available.

GPP
-----

Any report should include the following details written legibly (see proforma)

1. Name and signature and status (e.g. Consultant, Specialist trainee)
2. Date, time and location of examination
3. Reason for referral and referral physician
4. Level of consciousness of the child at the time of examination.
5. What drops were used to dilate the pupils and the time of instillation
6. Methods of examination
7. Photography details documented if done
8. Clear description of ocular findings with annotated diagrams.

### References

- (1) The Ophthalmology Child Abuse Working Party. Child abuse and the eye. Eye 1999;13(1):3-10.
- (2) Adams G, Ainsworth J, Butler L, Bonshek R, Clarke M, Doran R, et al. Update from the ophthalmology child abuse working party: Royal College of Ophthalmologists. Eye 2004;18(8):795-8.
- (29) Morad Y, Kim YM, Armstrong DC, Huyer D, Mian M, Levin AV. Correlation between retinal abnormalities and intracranial abnormalities in the shaken baby syndrome. Am J Ophthalmol 2002;134(3):354-9.
- (78) Sturm V, Landau K, Menke MN. Optical coherence tomography findings in shaken baby syndrome. Am J Ophthalmol 2008;146(3):363-8.
- (110) Saleh M, Schoenlaub S, Desprez P, Bourcier T, Gaucher D, Astruc D, et al. Use of digital camera imaging of eye fundus for telemedicine in children suspected of abusive head injury. Br J Ophthalmol 2009;93(4):424-8.
- (279) Nakagawa TAS, R. Improved Documentation of Retinal Hemorrhages Using a Wide-Field Digital Ophthalmic Camera in Patients Who Experienced Abusive Head Trauma. Arch Pediatr Adolesc Med 2001;155:1149-52.
- (281) Mulvihill AO, Jones P, Tandon A, Fleck BW, Minns RA. An inter-observer and intra-observer study of a classification of RetCam images of retinal haemorrhages in children. Br J Ophthalmol 2011;95(1):99-104.
- (282) Fleck BW, Tandon A, Jones PA, Mulvihill AO, Minns RA. An interrater reliability study of a new "zonal" classification for reporting the location of retinal haemorrhages in childhood for clinical, legal and research purposes. Br J Ophthalmol 2010;94(7):886-90.
- (283) Tandon A, McIntyre S, Yu A, Stephens D, Leiby B, Croker S, Levin AV. Retinal haemorrhage description tool. Br J Ophthalmol 2011;95:1719-1712.
- (285) Scott AW, Farsiu S, Enyedi LB, Wallace DK, Toth CA. Imaging the infant retina with a hand-held spectral-domain optical coherence tomography device. Am J Ophthalmol 2009;147(2):364-73.
- (286) Muni RH, Kohly RP, Sohn EH, Lee TC. Hand-held spectral domain optical coherence tomography finding in shaken-baby syndrome. Retina 2010;30(4):S45-S50.
- (287) Saperia J, Lakhanpaul M, Kemp A, Glaser D. When to suspect child maltreatment: Summary of NICE guidance. BMJ 2009;339(b2689).

- (288) H M Government. Working together to safeguard children  
<https://www.education.gov.uk/publications/eOrderingDownload/00305-2010DOM-EN.pdf> 2 2010(Chapter 1).
- (289) CDC Centre for disease control and prevention: Injury Prevention and control: violence prevention; child treatment.  
<http://www.cdc.gov/ViolencePrevention/childmaltreatment/definitions.html>. 2013.
- (290) Maguire S. Which injuries may indicate child abuse? Arch Dis Child Educ Pract Ed 2010;95:170-7.
- (291) Taylor D. Unnatural Injuries. Eye 2000;14:123-50.
- (293) Koozekanani DD, Weinberg DV, Dubis AM, Beringer J, Carroll J. Hemorrhagic retinoschisis in shaken baby syndrome imaged with spectral domain optical coherence tomography. Ophthalmic Surg Lasers Imaging 2010;9:1-13.
- (294) Kemp AM. Investigation subdural haemorrhage in infants. Arch Dis Child 2002;86(2):98-102.

## APPENDICES

### Appendix 1: Search Strategy

1. accidental injur\$.mp.
2. accidental traum\$.mp.
3. (accidental and injur\$).mp.
4. soft tissue injur\$.mp.
5. ((injur\* or trauma\*) adj3 abusive head).ti,ab.
6. non accidental head injury.mp.
7. physical abuse.mp.
8. or/1-7
9. exp child abuse/
10. child maltreatment.mp.
11. child protection.mp.
12. exp Battered Child Syndrome/
13. exp Shaken Baby Syndrome/
14. (battered child or shaken baby or battered baby).mp.
15. (battered infant or shaken infant).mp.
16. shak\$ baby syndrome.mp.
17. shak\$ impact syndrome.mp.
18. or/9-17
19. 8 or 18
20. exp Biomechanics/
21. biomechanic\*.ti,ab.
22. mechanism\*.ti,ab.
23. mechanic\*.ti,ab.
24. injury mechanism\*.ti,ab.
25. "mechanical model\*".ti,ab.
26. Movement/
27. or/20-26
28. Craniocerebral Trauma/
29. abusive head trauma\*.mp.
30. abusive head injur\*.mp.
31. \*Retina/
32. (ECMO adj5 retina\$).mp.
33. (Extracorporeal Membrane Oxygenation adj5 retina\$).mp.
34. (Flame shaped hemorrhage\$ or Flame shaped haemorrhage\$).mp.
35. (Flame hemorrhage\$ or Flame haemorrhage\$).mp.
36. Posterior pole.mp.
37. (Haemorrhagic retinopathy or Hemorrhagic retinopathy).mp.
38. ((Haemorrhag\$ or Hemorrhag\$) adj5 retin\$).mp.
39. Retinoschisis/
40. retinoschisis.mp.
41. ha?morrhagic retinoschisis.mp.
42. (Intracranial arterial aneurism or Intracranial arterial aneurysm).mp.
43. (Intraocular ha?morrhage\$ or Intraretinal ha?morrhage\$).mp.
44. epiretinal membrane.mp.
45. (low-density-lipoprotein-receptor-related protein 5 or LRP5-b).mp.
46. Ophthalmoplegia.mp.



47. (Papilledema or papilloedema).mp.
48. (Preretinal haemorrhage\$ or Preretinal hemorrhage\$).mp.
49. Purtscher retinopathy.mp.
50. (foveal haemorrhage\$ or foveal hemorrhage\$).mp.
51. Disc oedema.mp.
52. retinal Artery Occlusion.mp.
53. Retinal capillary network\$.mp.
54. (Retinal detachment adj5 (haemorrhag\$ or hemorrhag\$)).mp.
55. Retinal exudates.mp.
56. Retinal fold\$.mp.
57. Retinal hemorrhage/
58. retinal injur\$.mp.
59. Roth Spots.mp.
60. Spinal cord arteriovenous malformation.mp.
61. Terson Syndrome.mp.
62. (Unilateral retinal haemorrhage\$ or Unilateral retinal hemorrhage\$).mp.
63. (Valsalva maneuver adj5 (haemorrhag\$ or hemorrhag\$)).mp.
64. (Valsalva maneuver adj5 retina\$).mp.
65. (Valsalva retinopathy adj5 (haemorrhag\$ or hemorrhag\$)).mp.
66. (Valsalva retinopathy adj5 retina\$).mp.
67. (Vitreous haemorrhage\$ adj5 retina\$).mp.
68. (Vitreous hemorrhage\$ adj5 retina\$).mp.
69. Von Willebrand syndrome.mp.
70. (whiplash injur\$ adj5 (haemorrhag\$ or hemorrhag\$)).mp.
71. (whiplash injur\$ adj5 retina\$).mp.
72. (whiplash injur\$ and retina\$).mp.
73. (Ophthalmoplegia or Ophthalmoplegia).mp.
74. Nerve pals\$.mp.
75. Lid injur\$.mp.
76. Corneal laceration\$.mp.
77. palpebral fissure.mp.
78. (Ecchymosis eyelid or Ecchymosis eyelid).mp.
79. Bruis\$ eyelid.mp.
80. Lacerat\$ eyelid.mp.
81. blunt ocular trauma.mp.
82. exp Eye injuries/
83. Eye Injur\$.mp.
84. Orbital injur\$.mp.
85. (Ocular finding\$ or Ocular trauma\$).mp.
86. Ophthalmology/
87. Ophthalmological finding\$.mp.
88. Optic nerve
89. eyelid.mp.
90. exp Intracranial Hemorrhages/
91. Eye Hemorrhage/
92. ocular h?emorrhage.mp.
93. Conjunctival h?emorrhage\$.mp.
94. Subconjunctival h?emorrhage\$.mp.
95. Subhyaloid h?emorrhage\$.mp.
96. Subhyaloid macular h?emorrhage\$.mp.

97. retinal h?emorrhage\$.mp.
98. Subretinal h?emorrhage\$.mp.
99. splinter h?emorrhage\$.mp.
100. (blot retinal h?emorrhag\$ or bilateral retinal h?emorrhage\$).mp.
101. dot retinal h?emorrhag\$.mp.
102. eye h?emorrhag\$.mp.
103. or/28-102
104. 19 and 27 and 102
105. limit 104 to yr="2000 - 2010"

## Appendix 2: Critical appraisal form

CRITICAL APPRAISAL FORM- OCMWP (Ophthalmology Child Maltreatment Working Party)

Reviewers name:

Identifier		Citation	
------------	--	----------	--

<b>Key Questions:</b> please state which question/questions this study addresses
1.
2.
<b>Study Design</b>

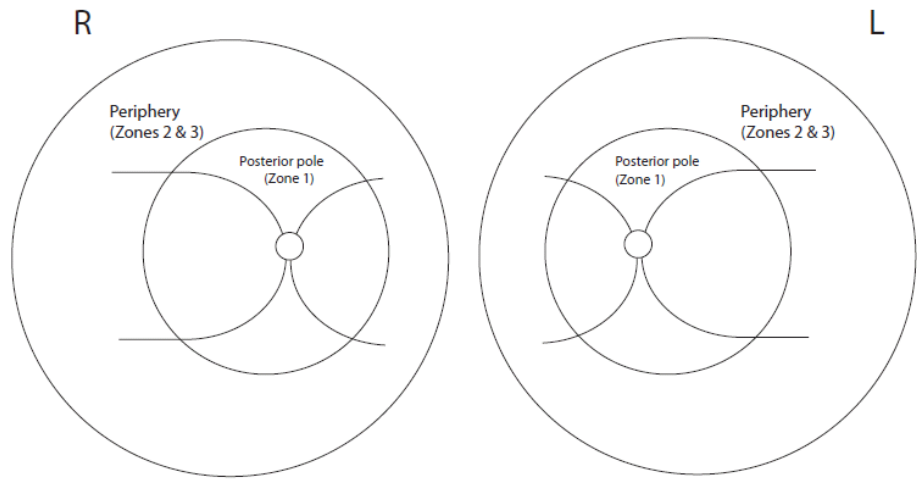
Quality Criteria Required- to include papers													
<p><b>1. IN STUDIES WITH ABUSE CASES HOW HAS ABUSE BEEN DEFINED.</b> Please state if they could be ranked either 1 to 4  <b>Rank 1:</b> Abuse confirmed at case conference, family, civil or criminal court proceedings, admitted by perpetrator or independently witnessed  <b>Rank 2:</b> Abuse confirmed by stated/ referenced criteria including multi-disciplinary assessment  <b>Rank 3:</b> Abuse defined by stated criteria  <b>Rank 4:</b> Abuse stated but no supporting detail given  <b>Rank 5:</b> Suspected abuse</p>	<table border="1" style="width: 100%; border-collapse: collapse;"> <tr><td><b>Rank 1</b></td><td></td></tr> <tr><td><b>Rank 2</b></td><td></td></tr> <tr><td><b>Rank 3</b></td><td></td></tr> <tr><td><b>Rank 4</b></td><td></td></tr> </table> <div style="text-align: right; margin-top: 10px;"> <table border="1" style="display: inline-table; border-collapse: collapse;"> <tr><td style="width: 50px;">N/A</td><td style="width: 50px;"></td></tr> </table> </div> <p>EXCLUDE RANK 5</p>	<b>Rank 1</b>		<b>Rank 2</b>		<b>Rank 3</b>		<b>Rank 4</b>		N/A			
<b>Rank 1</b>													
<b>Rank 2</b>													
<b>Rank 3</b>													
<b>Rank 4</b>													
N/A													
<p><b>2. IN STUDIES WITH ACCIDENTAL INJURY OR NON TRAUMATIC CAUSES OF RETINAL HAEMORRHAGE HAS ABUSE BEEN EXCLUDED</b></p> <p><b>A.</b> By multi-disciplinary assessment and child protection clinical investigation or forensic recreation of the scene  <b>B.</b> By checking either the child abuse register or records of previous abuse  <b>C</b> By confirmation of organic disease or witnessed accidental Causes or witnessed trauma</p> <p><b>D.</b> Consistent account of accident by either two (or more) individuals or the same individual over time  <b>E.</b> Accidental cause stated</p> <p><b>F.</b> Stated but no detail given  <b>G.</b> No attempt made</p>	<table border="1" style="width: 100%; border-collapse: collapse;"> <tr><td><b>A</b></td><td></td></tr> <tr><td><b>B</b></td><td></td></tr> <tr><td><b>C</b></td><td></td></tr> <tr><td><b>D</b></td><td></td></tr> <tr><td><b>E</b></td><td></td></tr> </table> <div style="text-align: right; margin-top: 10px;"> <table border="1" style="display: inline-table; border-collapse: collapse;"> <tr><td style="width: 50px;">N/A</td><td style="width: 50px;"></td></tr> </table> </div> <p>EXCLUDE F &amp; G</p>	<b>A</b>		<b>B</b>		<b>C</b>		<b>D</b>		<b>E</b>		N/A	
<b>A</b>													
<b>B</b>													
<b>C</b>													
<b>D</b>													
<b>E</b>													
N/A													
<p><b>3. STUDIES INVOLVING LIVE INFANTS HAS INVOLVED AN OPHTHALMOLOGIST</b></p> <p><b>A.</b> Ophthalmologist performs eye examination  <b>B.</b> Ophthalmologist first author  <b>C.</b> Ophthalmologist one of the authors  <b>D.</b> No ophthalmology input stated  <b>E.</b> Examination performed by non-ophthalmologist</p>	<table border="1" style="width: 100%; border-collapse: collapse;"> <tr><td><b>A</b></td><td></td></tr> <tr><td><b>B</b></td><td></td></tr> <tr><td><b>C</b></td><td></td></tr> </table> <div style="text-align: right; margin-top: 10px;"> <table border="1" style="display: inline-table; border-collapse: collapse;"> <tr><td style="width: 50px;">N/A</td><td style="width: 50px;"></td></tr> </table> </div> <p>EXCLUDE D &amp; E</p>	<b>A</b>		<b>B</b>		<b>C</b>		N/A					
<b>A</b>													
<b>B</b>													
<b>C</b>													
N/A													

<p><b>4. GRADE OF RECOMMENDATION *</b></p> <p><b>A.</b> Meta-analysis of SR, 1++ ,1+ directly related to pop  <b>B.</b> 2++ or extrapolated 1++, or 1+  <b>C.</b> 2+ or extrapolated 2++  <b>D.</b> (i) 2- or 3** or extrapolated 2+ D. (ii)4  <b>E.</b> Experimental study( note not part of SIGN)</p>	<table border="1" style="width: 100%; border-collapse: collapse;"> <tr><td><b>A</b></td><td></td></tr> <tr><td><b>B</b></td><td></td></tr> <tr><td><b>C</b></td><td></td></tr> <tr><td><b>D (i)</b></td><td></td></tr> <tr><td><b>E</b></td><td></td></tr> </table> <div style="text-align: right; margin-top: 10px;"> <p>EXCLUDE D (ii)</p> </div>	<b>A</b>		<b>B</b>		<b>C</b>		<b>D (i)</b>		<b>E</b>	
<b>A</b>											
<b>B</b>											
<b>C</b>											
<b>D (i)</b>											
<b>E</b>											
INCLUDE/EXCLUDE	Reason for exclusion										



History (cont.)

Other findings



Comments

Name
Signature

## Reference List

- (1) The Ophthalmology Child Abuse Working Party. Child abuse and the eye. *Eye* 1999;13(1):3-10.
- (2) Adams G, Ainsworth J, Butler L, Bonshek R, Clarke M, Doran R, et al. Update from the ophthalmology child abuse working party: Royal College of Ophthalmologists. *Eye* 2004;18(8):795-8.
- (3) <http://www.rcophth.ac.uk/documents.asp?section=39&sectionTitle=Publications> (accessed January 2013)
- (4) Scottish Intercollegiate Guidelines Network. SIGN 50 A guideline developer's handbook. Edinburgh: Scottish Intercollegiate Guidelines Network; 2011 (<http://www.sign.ac.uk/guidelines/fulltext/50/index.html>) accessed January 2013.
- (5) Green MA, Lieberman G, Milroy CM, Parsons MA. Ocular and cerebral trauma in non-accidental injury in infancy: Underlying mechanisms and implications for paediatric practice. *Br J Ophthalmol* 1996;80(4):282-7.
- (6) Lyle DJ, Stapp JP, Button RR. Ophthalmologic hydrostatic pressure syndrome. *Am J Ophthalmol* 1957;44(1):652-7.
- (7) Gilliland MG, Folberg R. Shaken babies: Some have no impact injuries. *J Forensic Sci* 1996;41(1):114-6.
- (8) David DB, Mears T, Quinlan MP. Ocular complications of bungee jumping. *Br J Ophthalmol* 1994;78(3):234-5.
- (9) Jain BK, Talbot EM. Bungee jumping and intraocular haemorrhage. *Br J Ophthalmol* 1994;78(3):236-7.
- (10) Chan J. Ophthalmic complications after bungee jumping. *Br J Ophthalmol* 1994;78(3):239.
- (11) Duhaime AC, Alario AJ, Lewander WJ, Schut L, Sutton LN, Seidl TS, et al. Head injury in very young children: Mechanisms, injury types, and ophthalmologic findings in 100 hospitalized patients younger than 2 years of age. *Pediatrics* 1992;90:179-85.
- (12) Budenz DL, Farger MG, Mirchandani HG, Park H, Rorke LB. Ocular and optic nerve hemorrhages in abused infants with intracranial injuries. *Ophthalmology* 1994;101:559-65.
- (13) Wilkinson WS, Han DP, Rappley MD, Owings CL. Retinal hemorrhage predicts neurologic injury in the shaken baby syndrome. *Arch Ophthalmol* 1989;107(10):1472-4.
- (14) Ommaya AK, Faas F, Yarnell P. Whiplash injury and brain damage: an experimental study. *JAMA* 1968;204(4):285-9.

- (15) Duhaime AC, Gennarelli TA, Thibault LE, Bruce DA, Margulies SS, Wisner R. The shaken baby syndrome: a clinical, pathological and biomechanical study. *J Neurosurg* 1987;66:409-15.
- (16) Hadley MN, Sonntag VK, Rekate HL, Murphy A. The infant whiplash-shake injury syndrome: a clinical and pathological study. *Neurosurgery* 1989;24:536-40.
- (17) Guthkelch AN. Infantile subdural haematoma and its relationship to whiplash injuries. *BMJ* 1971;2:430-1.
- (18) Buys YM, Levin AV, Enzenauer RW, Elder JE, Letourneau MA, Humphreys RP, et al. Retinal findings after head trauma in infants and young children. *Ophthalmology* 1992;99(11):1718-23.
- (19) Reiber GD. Fatal falls in childhood: How far must children fall to sustain fatal head injury? Report of cases and review of the literature. *Am J Forensic Med Pathol* 1993;14(3):201-7.
- (20) Elnor SG, Elnor VM, Arnall M, Albert DM. Ocular and associated systemic findings in suspected child abuse: A necropsy study. *Arch Ophthalmol* 1990;108(8):1094-101.
- (21) Frank Y, Zimmerman R, Leeds NMD. Neurological manifestations in abused children who have been shaken. *Dev Med Child Neurol* 1985;27(3):312-6.
- (22) Bandak FA. Shaken baby syndrome: A biomechanics analysis of injury mechanisms. *Forensic Sci Int* 2005;151(1):71-9.
- (23) Kivlin JD, Currie ML, Greenbaum VJ, Simons KB, Jentzen J. Retinal hemorrhages in children following fatal motor vehicle crashes: a case series. *Arch Ophthalmol* 2008;126(6):800-4.
- (24) Gnanaraj L, Gilliland MGF, Yahya RR, Rutka JT, Drake J, Dirks P, et al. Ocular manifestations of crush head injury in children. *Eye* 2007;21(1):5-10.
- (25) Adamsbaum C, Grabar S, Mejean N, Rey-Salmon C. Abusive head trauma: judicial admissions highlight violent and repetitive shaking. *Pediatrics* 2010;126(3):546-55.
- (26) Binenbaum G, Mirza-George N, Christian CW, Forbes BJ. Odds of abuse associated with retinal hemorrhages in children suspected of child abuse. *J AAPOS* 2009;13(3):268-72.
- (27) Pierre-Kahn V, Roche O, Dureau P, Uteza Y, Renier D, Pierre-Kahn A, et al. Ophthalmologic findings in suspected child abuse victims with subdural hematomas. *Ophthalmology* 2003;110(9):1718-23.
- (28) Vinchon M, de Foort-Dhellemmes S, Desurmont M, Delestret I. Confessed abuse versus witnessed accidents in infants: Comparison of clinical,

radiological, and ophthalmological data in corroborated cases. *Child Nerv Syst* 2010;26(5):637-45.

- (29) Morad Y, Kim YM, Armstrong DC, Huyer D, Mian M, Levin AV. Correlation between retinal abnormalities and intracranial abnormalities in the shaken baby syndrome. *Am J Ophthalmol* 2002;134(3):354-9.
- (30) Bhardwaj G, Chowdhury V, Jacobs MB, Moran KT, Martin FJ, Coroneo MT. A systematic review of the diagnostic accuracy of ocular signs in pediatric abusive head trauma. *Ophthalmology* 2010;117(5):983-92.
- (31) Geddes JF, Hackshaw AK, Vowles GH, Nickols CD, Whitwell H. Neuropathology of inflicted head injury in children. I. Patterns of brain damage. *Brain* 2001;124(7):1290-8.
- (32) Geddes JF, Vowles GH, Hackshaw AK, Nickols CD, Scott IS, Whitwell HL. Neuropathology of inflicted head injury in children. II. Microscopic brain injury in infants. *Brain* 2001;124(7):1299-306.
- (33) Coghlan A, Le Page M. Gently does it. *New Scientist* 2001;4-5.
- (34) Biousse V, Suh DY, Newman NJ, Davis PC, Mapstone T, Lambert SR. Diffusion-weighted magnetic resonance imaging in shaken baby syndrome. *Am J Ophthalmol* 2002;133(2):249-55.
- (35) Jaspan T, Griffiths PD, McConachie NS, Punt JAG, The Trent NAI group. Neuroimaging for non-accidental head injury in childhood: A proposed protocol. *Clin Radiol* 2003;58(1):44-53.
- (36) Ommaya AK, Goldsmith W, Thibault L. Biomechanics and neuropathology of adult and paediatric head injury. *Br J Neurosurg* 2002;16(3):220-42.
- (37) Duhaime AC, Christian CW. Child nervous systems. In: Choux M, Di Rocco C, Walker ML, editors. *Pediatric Neurosurgery*. 17 ed. London: Churchill Livingstone; 1999. p. 373-9.
- (38) Plunkett J. Fatal pediatric head injuries caused by short-distance falls. *Am J Forensic Med Pathol* 2001;22(3):322-36.
- (39) Gardner HB. A witnessed short fall mimicking presumed shaken baby syndrome (inflicted childhood neurotrauma). *Pediatr Neurosurg* 2007;43(5):433-5.
- (40) Lantz PE, Couture DE. Fatal acute intracranial injury, subdural hematoma, and retinal hemorrhages caused by stairway fall. *J Forensic Sci* 2011;56(6):1648-53.
- (41) Sauvageau A, Bourgault A, Racette S. Cerebral traumatism with a playground rocking toy mimicking shaken baby syndrome. *J Forensic Sci* 2008;53(2):479-82.



- (42) Wickham T, Abrahamson E. Head injuries in infants: The risks of bouncy chairs and car seats. *Arch Dis Child* 2002;86(3):168-9.
- (43) Jones MD, James DS, Cory CZ, Leadbeatter S, Nokes LDM. Subdural haemorrhage sustained in a baby-rocker?: A biomechanical approach to causation. *Forensic Sci Int* 2003;131(1):14-21.
- (44) Reece RM, Sege R. Childhood head injuries: Accidental or inflicted? *Arch Pediatr Adolesc Med* 2000;154(1):11-5.
- (45) Trenchs V, Curcoy A, Morales M, Serra A, Navarro R, Pou J. Retinal haemorrhages in head trauma resulting from falls: Differential diagnosis with non-accidental trauma in patients younger than 2-years of age. *Child Nerv Syst* 2008;24(7):815-20.
- (46) Christian CW, Taylor AA, Hertle RW, Duhaime AC. Retinal hemorrhages caused by accidental household trauma. *J Pediatr* 1999;135(1):125-7.
- (47) Schloff S, Mullaney PB, Armstrong DC, Simantirakis E, Humphreys RP, Myseros JS, et al. Retinal findings in children with intracranial hemorrhage. *Ophthalmology* 2002;109(8):1472-6.
- (48) Oehmichen M, Gerling I, Meissner C. Petechiae of the baby's skin as differentiation symptom of infanticide versus SIDS. *J Forensic Sci* 2000;45(3):602-7.
- (49) Watts P, Obi E. Retinal folds and retinoschisis in accidental and non-accidental head injury. *Eye* 2008;22(12):1514-6.
- (50) Biron D, Shelton D. Perpetrator accounts in infant abusive head trauma brought about by a shaking event. *Child Abuse Neglect* 2005;29(12):1347-58.
- (51) Starling SP, Patel S, Burke BL, Sirotnak AP, Stronk S. Analysis of perpetrator admissions to inflicted traumatic brain injury in children. *Arch Pediatr Adolesc Med* 2004;158(5):454-8.
- (52) Margolin EA, Dev L, Trobe JD. Prevalence of retinal hemorrhages in perpetrator-confessed cases of abusive head trauma. *Arch Ophthalmol* 2010;128(6):795.
- (53) Coats B, Binenbaum G, Peiffer RL, Forbes BJ, Margulies SS. Ocular hemorrhages in neonatal porcine eyes from single, rapid rotational events. *Invest Ophth Vis Sci* 2010;51(9):4792-7.
- (54) Bonnier C, Mesples B, Gressen P. Animal models of shaken baby syndrome: Revisiting the pathophysiology of this devastating injury. *Pediatr Rehabil* 2004;7(3):165-71.
- (55) Binenbaum G, Forbes BJ, Reghupathi R, Judkins A, Rorke L, Margulies SS. An animal model to study retinal hemorrhages in nonimpact brain injury. *J AAPOS* 2007;11(1):84-5.

- (56) Serbabescu I, Brown SM, Ramsay D, Levin AV. Natural animal shaking: A model for non-accidental head injury in children? *Eye* 2008;22(5):715-7.
- (57) de San Lazaro C, Harvey R, Ogden A. Shaking infant trauma induced by misuse of a baby chair. *Arch Dis Child* 2003;88(7):632-4.
- (58) Cirovic S, Bhola RM, Hose DR, Howard IC, Lawford PV, Parsons MA. A computational study of the passive mechanisms of eye restraint during head impact trauma. *Comput Methods Biomech Biomed Engin* 2005;8(1):1-6.
- (59) Hans SA, Bawab SY, Woodhouse ML. A finite element infant eye model to investigate retinal forces in shaken baby syndrome. *Graefes Arch Clin Exp Ophthalmol* 2009;247(4):561-71.
- (60) Rangarajan N, Kamalakkannan SB, Hasija V, Shams T, Jenny C, Serbanescu I, et al. Finite element model of ocular injury in abusive head trauma. *J AAPOS* 2009;13(4):364-9.
- (61) Prange MT, Coats B, Duhaime AC, Margulies SS. Anthropomorphic simulations of falls, shakes, and inflicted impacts in infants. *J Neurosurg* 2003;99(1):143-50.
- (62) Doorly MC, Gilchrist MD. The use of accident reconstruction for the analysis of traumatic brain injury due to head impacts arising from falls. *Comput Methods Biomech Biomed Engin* 2006;9(6):371-7.
- (63) Bertocci GE, Pierce MC, Deemer E, Aguel F, Janosky JE, Vogeley E. Using test dummy experiments to investigate pediatric injury risk in simulated short-distance falls. *Arch Pediatr Adolesc Med* 2003;157(5):480-6.
- (64) Cory CZ, Jones MD, James DS, Leadbeatter S, Nokes LDM. The potential and limitations of utilising head impact injury models to assess the likelihood of significant head injury in infants after a fall. *Forensic Sci Int* 2001;123(2):89-106.
- (65) Cory CZ, Jones MD. Development of a simulation system for performing in situ surface tests to assess the potential severity of head impacts from alleged childhood short falls. *Forensic Sci Int* 2006;163(1):102-14.
- (66) Mullner-Eidenbock A, Rainer G, Strenn K, Zidek T. High-altitude retinopathy and retinal vascular dysregulation. *Eye* 2000;14(5):724-9.
- (67) Geddes JF, Tasker RC, Hackshaw AK, Nickols CD, Adams GGW, Whitwell HL, et al. Dural haemorrhage in non-traumatic infant deaths: Does it explain the bleeding in 'shaken baby syndrome'? *Neuropath Appl Neuro* 2003;29(1):14-22.
- (68) Cohen M, Scheimberg I. Evidence of occurrence of intradural and subdural hemorrhage in the perinatal and neonatal period in the context of hypoxic

ischemic encephalopathy: An observational study from two referral institutions in the United Kingdom. *Pediatr Dev Pathol* 2009;12(3):169-76.

- (69) Barnes PD, Galaznik J, Gardner H, Shuman M. Infant acute life-threatening event–dysphagic choking versus nonaccidental injury. *Sem Pediatr Neurol* 2010;17(1):7-11.
- (70) Pitetti RD, Maffei F, Chang K, Hickey R, Berger R, Pierce MC. Prevalence of retinal hemorrhages and child abuse in children who present with an apparent life-threatening event. *Pediatrics* 2002;110(3):557-62.
- (71) Altman RL, Forman S, Brand DA. Ophthalmologic findings in infants after an apparent life-threatening event. *Eur J Ophthalmol* 2007;17:648-53.
- (72) Curcoy AI, Trenchs V, Morales M, Serra A, Pou J. Retinal hemorrhages and apparent life-threatening events. *Pediatr Emerg Care* 2010;26:118-20.
- (73) Davis NL, Wetli CV, Shakin JL. The retina in forensic medicine: Applications of ophthalmic endoscopy: The first 100 cases. *Am J Forensic Med Pathol* 2006;27:1-10.
- (74) Goldman M, Dagan Z, Yair M, Elbaz U, Lahat E, Yair M. Severe cough and retinal hemorrhage in infants and young children. *J Pediatr* 2006;148(6):835-6.
- (75) Herr S, Pierce MC, Berger RP, Ford H, Pitetti RD. Does valsalva retinopathy occur in infants? An initial investigation in infants with vomiting caused by pyloric stenosis. *Pediatrics* 2004;113(6):1658-61.
- (76) Goldenberg DT, Wu D, Capone A, Drenser KA, Trese MT. Nonaccidental trauma and peripheral retinal nonperfusion. *Ophthalmology* 2010;117(3):561-6.
- (77) Caputo G, de Haller R, Metge F, Dureau P. Ischemic retinopathy and neovascular proliferation secondary to shaken baby syndrome. *Retina* 2008;28(3):S42-S46.
- (78) Sturm V, Landau K, Menke MN. Optical coherence tomography findings in shaken baby syndrome. *Am J Ophthalmol* 2008;146(3):363-8.
- (79) Cory CZ, Jones MD. Can shaking alone cause fatal brain injury? *Med Sci Law* 2003;43(4):317-33.
- (80) Wolfson DR, McNally DS, Clifford MJ, Vloeberghs M. Rigid-body modelling of shaken baby syndrome. *J Engi Med* 2005;219(1):63-70.
- (81) Bhola RM, Cirovic S, Parson MA, Hose DR, Lawford PV, Howard IC. Modeling of the eye and orbit to simulate shaken baby syndrome. *Invest Ophth Vis Sci* 2005;46(5):4090.

- (82) Cheng J, Batterbee DC, Yoxall A, Sims ND, Rowson J, Howard IC. Shaken baby syndrome: A structural dynamics perspective. *Proceedings of ISMA 2008*:2003-14.
- (83) Fackler JC, Berkowitz ID, Green WR. Retinal hemorrhages in newborn piglets following cardiopulmonary resuscitation. *Am J Dis Child* 1992;146(11):1294-6.
- (84) Bottoli I, Beharry K, Modanlou HD, Norris K, Ling E, Noya F, et al. Effect of group B streptococcal meningitis on retinal and choroidal blood flow in newborn pigs. *Invest Ophth Vis Sci* 1995;36(7):1231-9.
- (85) Smith DC, Kearns TP, Sayre GP. Preretinal and optic nerve-sheath hemorrhage: Pathologic and experimental aspects in subarachnoid hemorrhage. *Trans Am Acad Ophthalmol Otolaryngol* 1957;61(2):201-11.
- (86) Wagnanski-Jaffe T, Murphy CJ, Smith C, Kubai M, Christopherson P, Ethier CR, et al. Protective ocular mechanisms in woodpeckers. *Eye* 2007;21(1):83-9.
- (87) Gilliland MG, Folberg R, Hayreh SS. Age of retinal hemorrhages by iron detection: An animal model. *Am J Forensic Med Pathol* 2005;26(1):1-4.
- (88) Riffenburgh RS, Sathyavagiswaran L. The eyes of child abuse victims: Autopsy findings. *J Forensic Sci* 1991;36(3):741-7.
- (89) Gilliland MG, Luckenbach MW, Chenier TC. Systemic and ocular findings in 169 prospectively studied child deaths: Retinal hemorrhages usually mean child abuse. *Forensic Sci Int* 1994;68(2):117-32.
- (90) Johnson DL, Braun D, Friendly D. Accidental head trauma and retinal hemorrhage. *Neurosurgery* 1993;33(2):231-4.
- (91) Conradi S, Brissie R. Battered child syndrome in a four year old with previous diagnosis of Reye's syndrome. *Forensic Sci Int* 1986;30(2-3):195-203.
- (92) Hosokawa T, Hayasaka S, Yabata K, Tateda H. Two Japanese cases of battered child syndrome with retinal hemorrhage. *Ophthalmologica* 1986;192:17-21.
- (93) Pounder DJ. Shaken adult syndrome. *Am J Forensic Med Pathol* 1997;18(4):321-4.
- (94) Carrigan TD, Walker E, Barnes S. Domestic violence: The shaken adult syndrome. *J Acci Emerg Med* 2000;17(2):138-9.
- (95) Kivlin JD, Simons KB, Lazowitz S, Ruttum MS. Shaken baby syndrome. *Ophthalmology* 2000;107(7):1246-54.

- (96) Meirisch RF, Frasier LD, Braddock SR, Giangiacomo J, Berkenbosch JW. Retinal hemorrhages in an 8-year-old child: An uncommon presentation of abusive injury. *Pediatr Emerg Care* 2004;20(2):118-20.
- (97) Salehi-Had H, Brandt JD, Rosas AJ, Rogers KK. Findings in older children with abusive head injury: Does shaken-child syndrome exist? *Pediatrics* 2006;117(5):e1039-e1044.
- (98) Munger CE, Peiffer RL, Bouldin TW, Kylstra JA, Thompson RL. Ocular and associated neuropathologic observations in suspected whiplash shaken infant syndrome. A retrospective study of 12 cases. *Am J Forensic Med Pathol* 1993;14(3):193-200.
- (99) Jensen AD, Smith RE, Olson MI. Ocular clues to child abuse. *J Pediatr Ophthalmol* 1971;8:270-2.
- (100) Mushin A, Morgan G. Ocular injury in the battered baby syndrome. *Br J Ophthalmol* 1971;55:343-7.
- (101) Rao N, Smith RE, Choi JH, Xu XH, Kornblum RN. Autopsy findings in the eyes of fourteen fatally abused children. *Forensic Sci Int* 1988;39(3):293-9.
- (102) Riffenburgh RS, Sathyavagiswaran L. Ocular findings at autopsy of child abuse victims. *Ophthalmology* 1991;98(10):1519-24.
- (103) Gaynon MW, Koh K, Marmor MF, Frankel LR. Retinal folds in the shaken baby syndrome. *Am J Ophthalmol* 1988;106(4):423-5.
- (104) Massicotte SJ, Folberg R, Torczynski E, Gilliland MG, Luckenbach MW. Vitreoretinal traction and perimacular retinal folds in the eyes of deliberately traumatized children. *Ophthalmology* 1991;98(7):1124-7.
- (105) Tyagi A, Willshaw HE, Ainsworth JR. Unilateral retinal haemorrhages in non-accidental injury. *Lancet* 1997;349(9060):1224.
- (106) Ludwig S, Warman M. Shaken baby syndrome: A review of 20 cases. *Ann Emerg Med* 1984;13(2):104-7.
- (107) Arlotti SA, Forbes BJ, Dias MS, Bonsall DJ. Unilateral retinal hemorrhages in shaken baby syndrome. *J AAPOS* 2007;11(2):175-8.
- (108) Kobayashi Y, Yamada K, Ohba S, Nishina S, Okuyama M, Azuma N. Ocular manifestations and prognosis of shaken baby syndrome in two Japanese children's hospitals. *Japan J Ophthalmol* 2009;53(4):384-8.
- (109) Levin AV. Retinal hemorrhage in abusive head trauma. *Pediatrics* 2010;126(5):961-70.
- (110) Saleh M, Schoenlaub S, Desprez P, Bourcier T, Gaucher D, Astruc D, et al. Use of digital camera imaging of eye fundus for telemedicine in children suspected of abusive head injury. *Br J Ophthalmol* 2009;93(4):424-8.

- (111) Shaw AD, Watts P, Maguire S, Holden S, Mann M, Kemp A. Are retinal findings in abused children different from those who suffer accidental head trauma? Results of a systematic review. *J AAPOS* 2010;14(1):e27.
- (112) Togioka BM, Arnold MA, Bathurst MA, Ziegfeld SM, Nabaweesi R, Colombani PM, et al. Retinal hemorrhages and shaken baby syndrome: An evidence-based review. *J Emerg Med* 2009;37(1):98-106.
- (113) Tongue A C. The ophthalmologist's role in diagnosing child abuse. *Ophthalmology* 1991;98(7):1009-10.
- (114) Keithahn MA, Bennett SR, Cameron D, Mieler WF. Retinal folds in Terson syndrome. *Ophthalmology* 1993;100(8):1187-90.
- (115) Greenwald MJ, Weiss A, Oesterle CS, Friendly DS. Traumatic retinoschisis in battered babies. *Ophthalmology* 1986;93(5):618-25.
- (116) Morris R, Kuhn F, Witherspoon CD. Hemorrhagic macular cysts. *Ophthalmology* 1994;101(1):1.
- (117) Bechtel K, Stoessel K, Leventhal JM, Ogle E, Teague B, Laviertes S, et al. Characteristics that distinguish accidental from abusive injury in hospitalized young children with head trauma. *Pediatrics* 2004;114(1):165-8.
- (118) Lantz PE, Sinal SH, Stanton CA, Weaver RGJr. Perimacular retinal folds from childhood head trauma. *BMJ* 2004;328(7442):754-6.
- (119) Marshall DH, Brownstein S, Dorey MW, Addison DJ, Carpenter B. The spectrum of postmortem ocular findings in victims of shaken baby syndrome. *Can J Ophthalmol* 2001;36(7):377-83.
- (120) Ho LY, Goldenberg DT, Capone AJ. Retinal pigment epithelial tear in shaken baby syndrome. *Arch Ophthalmol* 2009;127(11):1547-8.
- (121) Ells AL, Kherani A, Lee D. Epiretinal membrane formation is a late manifestation of shaken baby syndrome. *J AAPOS* 2003;7(3):223-5.
- (122) Lash SC, Williams CPR, Luff AJ, Hodgkins PR. 360 degree giant retinal tear as a result of presumed non-accidental injury. *Br J Ophthalmol* 2004;88(1):155.
- (123) Ou J, Moshfeghy DM, Tawansy K, Sears JE. Macular hole in the shaken baby syndrome. *Arch Ophthalmol* 2006;124(6):913-5.
- (124) Cackett P, Fleck B, Mulvihill AO. Bilateral fourth-nerve palsy occurring after shaking injury in infancy. *J AAPOS* 2004;8(3):280-1.
- (125) Mulvihill AO, Buncic JR. Vertical sensory nystagmus associated with intraocular haemorrhages in the shaken baby syndrome. *Eye* 2004;18(5):545-56.

- (126) Betz P, Puschel K, Miltner E, Lignitz E, Eisenmenger W. Morphometrical analysis of retinal hemorrhages in the shaken baby syndrome. *Forensic Sci Int* 1996;78(1):71-80.
- (127) Fraser SG, Horgan SE, Bardavio J. Retinal haemorrhage in meningitis. *Eye* 1995;9(5):659-60.
- (128) Sandramoulli S, Robinson R, Tsaloumas M, Willshaw HE. Retinal haemorrhages and convulsions. *Arch Dis Child* 1997;76(5):449-51.
- (129) Weissgold DJ, Budenz DL, Hood I, Rorke LB. Ruptured vascular malformation masquerading as battered/shaken baby syndrome: A nearly tragic mistake. *Surv Ophthalmol* 1995;39(6):509-12.
- (130) Burton TC. Unilateral Purtscher's retinopathy. *Ophthalmology* 1980;87(11):1096-105.
- (131) Sethi SK. Retinal hemorrhages after extra corporeal membranous oxygenation. *N C Med J* 1990;51(5):246.
- (132) Carney M, Wortham E, al-Mateen K. Vitreous hemorrhage and extracorporeal membrane oxygenation. *Am J Ophthalmol* 1993;15(115):391-3.
- (133) Goetting MG, Sowa B. Retinal hemorrhage after cardiopulmonary resuscitation in children: An etiologic reevaluation. *Pediatrics* 1990;85:585-8.
- (134) Kelley JS. Purtscher's retinopathy related to chest compression by safety belts. Fluoresceinangiographic findings. *Am J Ophthalmol* 1972;74(2):278-83.
- (135) Giles CL. Retinal haemorrhages in the newborn. *Am J Ophthalmol* 1960;49:1005-10.
- (136) Healey K, Schradling W. A case of shaken baby syndrome with unilateral retinal hemorrhage with no associated intracranial hemorrhage. *Am J Emerg Med* 2006;24(5):616-7.
- (137) Barry GPR. Pathologic brain and head findings associated feith retinal hemorrhages in young children with abusive or accidental head injuries. *J AAPOS* 2010;14(1):e11.
- (138) Shaikh S, Fishman ML, Gaynon M, Alcorn D. Diffuse unilateral hemorrhagic retinopathy associated with accidental perinatal strangulation: A Clinicopathologic Report. *Retina* 2001;21(3):252-5.
- (139) Arlotti SA, Forbes BJ, Dias MS, Bonsall DJ. Unilateral retinal hemorrhages in shaken baby syndrome. *J AAPOS* 2007;11(2):175-8.

- (140) Gilles EE, McGregor ML, Levy-Clarke G. Retinal hemorrhage asymmetry in inflicted head injury: A clue to pathogenesis? *J Pediatr* 2003;143(4):494-9.
- (141) Bhardwaj G, Jacobs MB, Moran KT, Tan K. Terson syndrome with ipsilateral severe hemorrhagic retinopathy in a 7-month-old child. *J AAPOS* 2010;14(5):441-3.
- (142) Fledelius HC. Retinal haemorrhages in premature infants: A pathogenetic alternative diagnosis to child abuse. *Acta Ophthalmol Scand* 2005;83(4):424-7.
- (143) Stephenson T. Ageing of bruising in children. *J Royal Soci Med* 1997;90(6):312-4.
- (144) Sezen F. Retinal haemorrhages in newborn infants. *Br J Ophthalmol* 1970;55(4):248-53.
- (145) Baum JD, Bulpitt CJ. Retinal and conjunctival haemorrhage in the newborn. *Arch Dis Child* 1970;45:344-9.
- (146) Giangiacomo J, Barkett KJ. Ophthalmoscopic findings in occult child abuse. *J AAPOS* 1985;22(6):234-7.
- (147) Mathews GP, Das A. Dense vitreous hemorrhages predict poor visual and neurological prognosis in infants with shaken baby syndrome. *J AAPOS* 1996;33:260-5.
- (148) Ferrone PJ, de Juan EJ. Vitreous hemorrhage in infants. *Arch Ophthalmol* 1994;112(9):1185-9.
- (149) Gilliland MG, Luckenbach MW, Massicotte SJ, Folberg R. The medicolegal implications of detecting hemosiderin in the eyes of children who are suspected of being abused. *Arch Ophthalmol* 1991;109(3):321-2.
- (150) Elner SG, Elner VM, Albert DM, Arnall M. The medicolegal implications of detecting hemosiderin in the eyes of children who are suspected of being abused (reply to letter from Gilliland et al). *Arch Ophthalmol* 1991;109:322.
- (151) McCabe CF, Donahue SP. Prognostic indicators for vision and mortality in shaken baby syndrome. *Arch Ophthalmol* 2000;118(3):373-7.
- (152) Hughes LA, May K, Talbot JF, Parson MA. Incidence, distribution and duration of birth-related retinal hemorrhages: A prospective study. *J AAPOS* 2006;10(2):102-6.
- (153) Emerson MV, Pieramici DJ, Stoessel KM, Berreen JP, Gariano RF. Incidence and rate of disappearance of retinal hemorrhage in newborns. *Ophthalmology* 2001;108(1):36-9.



- (154) Zimmerman RA, Bilaniuk LT, Bruce D, Schut L, Uzzell B, Goldberg HI. Interhemispheric acute subdural hematoma: a computed tomographic manifestation of child abuse by shaking. *Neuroradiology* 1978;16:39-40.
- (155) Giangiacomo J, Khan JA, Levine C, Thompson VM. Sequential cranial computed tomography in infants with retinal hemorrhages. *Ophthalmology* 1988;95(3):295-9.
- (156) Billmire ME, Myers PA. Serious head injury in infants: Accident or abuse? *Pediatrics* 1985;75(2):340-2.
- (157) Kanter RK. Retinal hemorrhage after cardiopulmonary resuscitation or child abuse. *J Pediatr* 1986;108(3):430-2.
- (158) Tomasi LG, Rosman NP. Purtscher retinopathy in the battered child syndrome. *Am J Dis Child* 1975;129(11):1335-7.
- (159) Carter J, McCormick AQ. Whiplash shaking syndrome: Retinal hemorrhages and computerised axial tomography of the brain. *Child Abuse Neglect* 1983;7:279-86.
- (160) Wahl NG, Woodall BN. Hypothermia in shaken infant syndrome. *Pediatr Emerg Care* 1995;11(4):223-4.
- (161) Morad Y, Avni I, Capra L, Case ME, Feldman K, Kodsí SR, et al. Shaken baby syndrome without intracranial hemorrhage on initial computed tomography. *J AAPOS* 2004;8(6):521-7.
- (162) Morad Y, Avni I, Benton SA, Berger RP, Byerley JS, Coffman K, et al. Normal computerized tomography of brain in children with shaken baby syndrome. *J AAPOS* 2004;8(5):445-50.
- (163) McLellan NJ, Prasad R, Punt J. Spontaneous subhyaloid and retinal haemorrhages in an infant. *Arch Dis Child* 1986;61(11):1130-2.
- (164) Terson A. Le syndrome du corps vitré et de l'hémorragie intracrânienne spontane. *Ann Oculist* 1926;163:666-73.
- (165) Garfinkle AM, Danys IR, Nicolle DA, Colohan AR, Brem S. Terson's syndrome: A reversible cause of blindness following subarachnoid hemorrhage. *J Neurosurg* 1992;76(5):766-71.
- (166) Pfausler B, Belcl R, Metzler R, Mohsenipour I, Schmutzhard E. Terson's syndrome in spontaneous subarachnoid hemorrhage: a prospective study in 60 consecutive patients. *J Neurosurg* 1996;85(3):392-4.
- (167) Mena OJ, Paul I, Reichard RR. Ocular findings in raised intracranial pressure: A case of Terson syndrome in a 7-month-old infant. *Am J Forensic Med Pathol* 2011;32(1):55-7.

- (168) Noel LP, Botash AS, DeSilva A. Maternal antiphospholipid antibodies and vitreous hemorrhages in the newborn: A case report. *Arch Ophthalmol* 2001;119(6):914-6.
- (169) Forbes BJ, Cox M, Christian CW. Retinal hemorrhages in patients with epidural hematomas. *J AAPOS* 2008;12(2):177-80.
- (170) Aryan H, Ghosheh FR, Jandial R, Levy ML. Retinal hemorrhage and pediatric brain injury: Etiology and review of the literature. *J Clin Neurosci* 2005;12(6):624-31.
- (171) Ghahreman A, Bhasin V, Chaseling R, Andrews B, Lang EW. Nonaccidental head injuries in children: A Sydney experience. *J Neurosurg* 2005;103(3):213-8.
- (172) Leestma JE. Case analysis of brain-injured admittedly shaken infants: 54 cases, 1969-2001. *Am J Forensic Med Pathol* 2005;26(3):199-212.
- (173) Lambert SR, Johnson TE, Hoyt CS. Optic nerve sheath and retinal hemorrhages associated with the shaken baby syndrome. *Arch Ophthalmol* 1986;104(10):1509-12.
- (174) Mills M. Fundusoscopic lesions associated with mortality in shaken baby syndrome. *J AAPOS* 1998;2(2):67-71.
- (175) Gilles EE, McGregor ML, Levy-Clarke G. Retinal hemorrhage in autopsies assymetry in inflicted head injury: A clue to pathogenesis. *J Pediatr* 2003;143:494-9.
- (176) Riffenburgh RS. Ocular hemorrhage in autopsies in child abuse victims. *Clin Surger Ophthamol* 2005;23:178-86.
- (177) Wagnanski-Jaffe T, Levin AV, Shafiq A, Smith C, Enzenauer RW, Elder JE, Morin JD, Stephens D, Atenafu. Postmortem orbital findings in shaken baby syndrome. *Am J Ophthalmol* 2006;142(2):233-40.
- (178) Emerson MV, Jakobs E, Green WR. Ocular autopsy and histopathologic features of child abuse. *Ophthalmology* 2007;114(7):1384-94.
- (179) Muller PJ, Deck JH. Intraocular and optic nerve sheath hemorrhage in cases of sudden intracranial hypertension. *J Neurosurg* 1974;41(2):160-6.
- (180) Eisenbrey AB. Retinal hemorrhage in the battered child. *Childs Brain* 1979;5(1):40-4.
- (181) Alario AJ, Lewander W, Tsiaras W, Wallach M, O'Shea JS. Do retinal hemorrhages occur with accidental head trauma in young children. *Am J Dis Child* 1990;144:445.
- (182) Elder JE, Taylor RG, Klug GL. Retinal haemorrhage in accidental head trauma in childhood. *J Pediatr Child Health* 1991;27(5):286-9.

- (183) Warrington SA, Wright CM. Accidents and resulting injuries in premobile infants: data from the ALSPAC study. *Arch Dis Child* 2001;85(2):104-7.
- (184) Maddocks GB, Sibert JR, Brown BM. A four week study of accidents to children in South Glamorgan. *Public Health* 1978;92(4):171-6.
- (185) Rivara FP, Kamitsuka MD, Quan L. Injuries to children younger than 1 year of age. *Pediatrics* 1988;81(1):93-7.
- (186) Jayawant S, Rawlinson A, Gibbon F, Price J, Schulte J, Sharples P, et al. Subdural haemorrhages in infants: population based study. *BMJ* 1998;317(7172):1558-61.
- (187) Feldman KW, Bethel R, Shugerman RP, Grossman DC, Grady MS, Ellenbogen RG. The cause of infant and toddler subdural hemorrhage: A prospective study. *Pediatrics* 2001;108(3):636-46.
- (188) Sturm V, Knecht PB, Landau K, Menke MN. Rare retinal haemorrhages in translational accidental head trauma in children. *Eye* 2009;23(7):1535-41.
- (189) Vinchon M, Noizet O, Defoort-Dhellemmes S, Soto-Ares G, Dhellemmes P. Infantile subdural hematomas due to traffic accidents. *Pediatr Neurosurg* 2002;37(5):245-53.
- (190) Barnes PD, Krasnokutsky MV, Monson KL, Ophoven J. Traumatic spinal cord injury: Accidental versus nonaccidental injury. *Sem Pediatr Neurol* 2008;15(4):178-84.
- (191) Reddie IC, Bhardwaj G, Dauber SL, Jacobs MB, Moran KT. Bilateral retinoschisis in a 2-year-old following a three-storey fall. *Eye* 2010;24(8):1426-7.
- (192) Keenan HT, Runyan DK, Marshall SW, Nocera MA, Merten DF. A population-based comparison of clinical and outcome characteristics of young children with serious inflicted and noninflicted traumatic brain injury. *Pediatrics* 2004;114(3):633-9.
- (193) Lueder GT, Turner JW, Paschall R. Perimacular retinal folds simulating nonaccidental injury in an infant. *Arch Ophthalmol* 2006;124(12):1782-3.
- (194) Gardner HB. A witnessed short fall mimicking presumed shaken baby syndrome (inflicted childhood neurotrauma). *Pediatr Neurosurg* 2007;43(5):433-5.
- (195) Guyer DR, Schachat AP, Vitale S, Markowitz JA, Braine H, Burke P, et al. Leukemic retinopathy. Relationship between fundus lesions and hematologic parameters at diagnosis. *Ophthalmology* 1989;96(6):860-4.
- (196) Robb RM, Ervin L, Sallan SE. A pathological study of eye involvement in acute leukemia of childhood. *Trans Am Acad Ophthalmol Otolaryngol* 1978;76:90-101.

- (197) Gagliano DA, Goldberg MF. The evolution of salmon-patch hemorrhages in sickle cell retinopathy. *Arch Ophthalmol* 1989;107(12):1814-5.
- (198) Young TL, Quinn GE, Baumgart S, Petersen RA, Schaffer DB. Extracorporeal membrane oxygenation causing asymmetric vasculopathy in neonatal infants. *J AAPOS* 1997;1(4):235-40.
- (199) Patrias MC, Rabinowicz IM, Klein MD. Ocular findings in infants treated with extracorporeal membrane oxygenator support. *Pediatrics* 1988;82(4):560-4.
- (200) Levy HL, Brown AE, Williams SE, de Juan EJr. Vitreous hemorrhage as an ophthalmic complication of galactosemia. *J Pediatr* 1996;129(6):922-5.
- (201) Petersen S, Taaning E, Söderström T, Pilgaard B, Tranebjaery L, Christensen T, et al. Immunoglobulin and complement studies in children with Schönlein-Henoch syndrome and other vasculitic diseases. *Acta Paediatr Scand* 1991;80(11):1037-43.
- (202) Raja SC, Fekrat S, Connor TB Jr. Bilateral macular vitelliform lesions in a thrombocytopenic patient. *Arch Ophthalmol* 1995;113(4):411-3.
- (203) Silva-Araujo AL, Tavares MA, Patacao MH, Carolino RM. Retinal hemorrhages associated with in utero exposure to cocaine: Experimental and clinical findings. *Retina* 1996;16(5):411-8.
- (204) Atkinson A, Sanders MD, Wong V. Vitreous haemorrhage in tuberous sclerosis. Report of two cases. *Br J Ophthalmol* 1973;57(10):773-9.
- (205) George ND, Yates JR, Bradshaw K, Moore A. Infantile presentation of X linked retinoschisis. *Br J Ophthalmol* 1995;79(7):653-7.
- (206) Christiansen SP, Muñoz M, Capó H. Retinal hemorrhage following lensectomy and anterior vitrectomy in children. *J AAPOS* 1993;30(1):24-7.
- (207) Mets MB, Del Monte M. Hemorrhagic retinopathy following uncomplicated pediatric cataract extraction. *Arch Ophthalmol* 1986;104(7):975-9.
- (208) Laumonier E, Labalette P, Morisot C, Mouriaux F, Dobbelaere D, Rouland JF. Vitreous hemorrhage in a neonate with galactosemia. A case report. *J French Ophthalmol* 2005;28(5):490-6.
- (209) Francis PJ, Calver DM, Barnfield P, Turner C, Dalton RN, Champion MP. An infant with methylmalonic aciduria and homocystinuria (cblC) presenting with retinal haemorrhages and subdural haematoma mimicking non-accidental injury. *Eur J Pediatr* 2004;163(7):420-1.
- (210) Hartley LM, Sonntag VK, ReKate HL, Murphy A. Glutaric aciduria type 1 and nonaccidental head injury. *Pediatrics* 2001;107(1):174-5.

- (211) Kafil-Hussain NA, Monavari A, Bowell R, Thornton P, Naughten E, O'Keefe M. Ocular findings in glutaric aciduria type 1. *J AAPOS* 2000;37(5):289-93.
- (212) Gago LC, Wegner RK, Capone AJ, Williams GA. Intraretinal hemorrhages and chronic subdural effusions: Glutaric aciduria type 1 can be mistaken for shaken baby syndrome. *Retina* 2003;23(5):724-6.
- (213) Ganesh A, Jenny C, Geyer J, Shouldice M, Levin AV. Retinal hemorrhages in type I osteogenesis imperfecta after minor trauma. *Ophthalmology* 2004;111(7):1428-31.
- (214) Ai M, Heeger S, Bartels CF, Schelling DK, Osteoporosis-Pseudoglioma Collaborative Group. Clinical and molecular findings in osteoporosis-pseudoglioma syndrome. *Am J Human Gen* 2005;77(5):741-53.
- (215) Chang JT, Chiu PC, Chen YY, Wang HP, Hsieh KS. Multiple clinical manifestations and diagnostic challenges of incontinentia pigmenti—12 years' experience in 1 medical center. *J Chin Med Assoc* 2008;71(9):455-60.
- (216) Lee JJ, Kim JH, Kim SY, Park SS, Yu YS. Infantile vitreous hemorrhage as the initial presentation of X-linked juvenile retinoschisis. *Korean J Ophthalmol* 2009;23(2):118-20.
- (217) Chen CY, Tsao PN, Young C, Peng SS, Tsou KI. Bilateral central retinal vein occlusion with multiple intracerebral hemorrhage in a neonate. *Pediatr Neurol* 2003;28(5):400-2.
- (218) Barampouti F, Rajan M, Aclimandos W. Should active CMV retinitis in non-immunocompromised newborn babies be treated? *Br J Ophthalmol* 2002;86(2):248-9.
- (219) Takizawa Y, Hayashi S, Fujimaki T, Mizota A, Yokoyama T, Tanaka M, et al. Central retinal vein occlusion caused by human herpesvirus 6. *J AAPOS* 2006;43(3):176-8.
- (220) Jalali S, Kolari RS, Pathengay A, Athmanathan S. Severe hemorrhagic retinopathy as initial manifestation of acute retinal necrosis caused by herpes simplex virus. *Indian J Ophthalmol* 2007;55(4):308-10.
- (221) Lewallen S, Bronzan RN, Beare NA, Harding SP, Molyneux ME, Taylor TE. Using malarial retinopathy to improve the classification of children with cerebral malaria. *Trans R Soc Trop Med Hyg* 2008;102(11):1089-94.
- (222) Beare NA, Southern C, Chalira C, Taylor TE, Molyneux ME, Harding SP. Prognostic significance and course of retinopathy in children with severe malaria. *Arch Ophthalmol* 2004;122(8):1141-7.
- (223) White VA, Lewallen S, Beare NA, Molyneux ME, Taylor TE. Retinal pathology of pediatric cerebral malaria in Malawi. *PLoS ONE* 2009;4(1):e4317.

- (224) Dinakaran S, Chan TK, Rogers NK, Brosnahan DM. Retinal hemorrhages in meningococcal septicemia. *J AAPOS* 2002;6(4):221-3.
- (225) Ong BB, Gole GA, Robertson T, McGill J, de Lore D, Crawford M. Retinal hemorrhages associated with meningitis in a child with a congenital disorder of glycosylation. *Forensic Sci Med Pathol* 2009;5(4):307-12.
- (226) Lopez JP, Roque J, Torres J, Levin AV. Severe retinal hemorrhages in infants with aggressive, fatal *Streptococcus pneumoniae* meningitis. *J AAPOS* 2010;14(1):97-8.
- (227) Vasconcelos-Santos DV, Machado Azevedo DO, Campos WR, Orefice F, Queiroz-Andrade GM, Carellos EV, et al. Congenital toxoplasmosis in Southeastern Brazil: Results of early ophthalmologic examination of a large cohort of neonates. *Ophthalmology* 2009;116(11):2199-205.
- (228) Currie AD, Bentley CR, Bloom PA. Retinal haemorrhage and fatal stroke in an infant with fibromuscular dysplasia. *Arch Dis Child* 2001;84:263-4.
- (229) Ko F, Knox DL. The ocular pathology of Terson's syndrome. *Ophthalmology* 2010;117:1423-9.
- (230) Gicquel J, Bouhamida J, Dighiero P. Ophthalmological complications of the asphyxiophilic "scarf game" in a 12-year-old child. *J Fr Ophtalmol* 2004;27(10):1153-5.
- (231) Lim Z, Tehrani NN, Levin AV. Retinal haemorrhages in a preterm infant following screening examination for retinopathy of prematurity. *Br J Ophthalmol* 2006;90(6):799-800.
- (232) Azad RV, Chandra P, Pal N, Singh DV. Retinal haemorrhages following Retcam screening for retinopathy of prematurity. *Eye* 2005;19(11):1221-2.
- (233) Von Barsewisch B. Perinatal retinal haemorrhages: morphology, aetiology and significance. Berlin: Springer-Verlag; 1979.
- (234) Bonamour G. Le pronostic éloigné des hémorragies rétinienne du nouveau-né. *Bull Soc Fr Ophthalmol* 1949;62:227-36.
- (235) Von Noorden GK, Khodahoust A. Retinal haemorrhage in newborns and organic amblyopia. *Ann Ophthalmol* 1973;89:91-3.
- (236) Zwaan J, Cardenas R, O'Connor PS. Long-term outcome of neonatal macular haemorrhage. *J AAPOS* 1997;(34):286-8.
- (237) Emerson MV, Pieramici DJ, Stoessel KM, Berreen JP, Gariano RF. Incidence and rate of disappearance of retinal hemorrhage in newborns. *Ophthalmology* 2001;108(1):36-9.

- (238) Gayle MO, Hered RW, Harwood-Nuss A, Kissoon N. Retinal haemorrhages in the young child: A review of etiology, predisposed conditions, and clinical implications. *J Emerg Med* 1995;13(233):239.
- (239) Shaw NJ, Eden OB. Juvenile chronic myelogenous leukemia and neurofibromatosis in infancy presenting as ocular hemorrhage. *Pediatr Hematol-Oncol* 1989;6:23-6.
- (240) Shiono T, Abe S, Watabe T, Noro M, Tamai M, Akutso Y. Vitreous, retinal and subretinal haemorrhages associated with von Willebrand's syndrome. *Graefe Arch Cli Exp Ophthalmol* 1992;230:496-7.
- (241) Pulido JS, Lingua RW, Cristol BS, Byrne SF. Protein C deficiency associated with vitreous hemorrhage in a neonate. *Am J Ophthalmol* 1987;104(546):547.
- (242) Cassels-Brown A, Minford AMB, Chatfield SL, Bradbury JA. Ophthalmic manifestations of neonatal protein C deficiency. *Br J Ophthalmol* 1994;78:486-7.
- (243) O'Hare AE, Eden OB. Bleeding disorders and non-accidental injury. *Arch Dis Child* 1984;9:860-4.
- (244) Hymel KP, Abshire TC, Luckey DW, Jenny C. Coagulopathy in pediatric abusive head trauma. *Pediatrics* 1997;99:371-5.
- (245) Stray-Pedersen A, Omland S, Nedregaard B, Klevberg S, Rognum TO. An infant with subdural hematoma and retina hemorrhages: Does von Willebrand disease explain the findings? *Forensic Sci Med Pathol* 2011;7(1):37-41.
- (246) Bhatagnar A, Wilkinson LB, Tyagi AK, Wilshaw HE. Subinternal limiting membrane hemorrhage with perimacular fold in leukemia. *Arch Ophthalmol* 2009;127(11):1548-50.
- (247) Russell-Eggitt IM, Thompson DA, Khair K, Liesner R, Hann IM. Hermansky-Pudlak syndrome presenting with subdural haematoma and retinal haemorrhages in infancy. *J Royal Soci Medi* 2000;93:591-2.
- (248) Rooms L, Fitzgerald N, McClain KL. Hemophagocytic lymphohistiocytosis masquerading as child abuse: Presentation of three cases and review of central nervous system findings in hemophagocytic lymphohistiocytosis. *Pediatrics* 2003;111(5):636-40.
- (249) Marshman WE, Adams GG, Ohri R. Bilateral vitreous hemorrhages in an infant with low fibrinogen levels. *J AAPOS* 1999;3:255-6.
- (250) Naithani P, Venkatesh P, Sankaran P, Vashisht N, Garg S. Early-onset atypical ischemic maculopathy after bone marrow transplantation. *J AAPOS* 2010;14(2):187-9.

- (251) Kirby S, Sadler RM. Injury and death as a result of seizures. *Epilepsia* 1995;36(1):25-8.
- (252) Tyagi AK, Scotcher S, Kozeis N, Willshaw HE. Can convulsions alone cause retinal haemorrhages in infants? *Br J Ophthalmol* 1998;82:659-60.
- (253) Feyi-Waboso AC, Beck L. Minerva column. *BMJ* 1997;314:688.
- (254) Mei-Zahav M, Uziel Y, Raz J, Ginot N, Wolach B, Fainmesser P. Convulsions and retinal haemorrhage: Should we look further? *Arch Dis Child* 2002;86:334-5.
- (255) Aghadoost D, Talebian A. Convulsions and retinal hemorrhages. *Indian Pediatr* 2004;41:1271-2.
- (256) Curcoy AI, Trenchs V, Morales M, Serra A, Pineda M, Pou J. Do retinal haemorrhages occur in infants with convulsions? *Arch Dis Child* 2009;94:873-5.
- (257) Rogers MC, Nugent SK, Stidham GL. Effects of closed chest massage on intracranial pressure. *Crit Care Med* 1979;7:454-6.
- (258) Bacon CJ, Sayer GC, Howe J. Extensive retinal haemorrhages in infancy: An innocent cause. *BMJ* 1978;1:281.
- (259) Weedn VW, Mansour AM, Nichols MM. Retinal hemorrhage in an infant after cardiopulmonary resuscitation. *Am J Forensic Med Pathol* 1990;11:79-82.
- (260) Gilliland MG, Luckenbach MW. Are retinal hemorrhages found after resuscitation attempts? *Am J Forensic Med Pathol* 1993;14:187-92.
- (261) Polito A, Au Eong K-G, Repka MX, Pieramici DJ. Bilateral retinal hemorrhages in a preterm infant with retinopathy of prematurity immediately following cardiopulmonary resuscitation. *Arch Ophthalmol* 2001;119(6):913-4.
- (262) Duane TD. Valsalva hemorrhagic retinopathy. *Trans Am Acad Ophthalmol Otolaryngol* 1972;70:298-313.
- (263) Geddes JF, Talbert DG. Paroxysmal coughing, subdural and retinal bleeding: a computer modelling approach. *Neuropath Appl Neuro* 2006;32(6):625-34.
- (264) Clemetson CAB. Elevated blood histamine caused by vaccinations and vitamin C deficiency may mimic the shaken baby syndrome. *Med Hypotheses* 2003;62(4):533-6.
- (265) Gardner HB. Immunisations, retinal and subdural hemorrhages: Are they related? *Med Hypotheses* 2005;64(3):663.



- (266) Devin F, Roques G, Disdier P, Rodor F, Weiller PJ. Occlusion of central retinal vein after hepatitis B vaccination. *Lancet* 1996;347(9015):1626.
- (267) Granel B, Disdier P, Devin F, Swiader L, Riss JM, Coupier L, et al. Occlusion of the central retinal vein after vaccination against viral hepatitis B with recombinant vaccines. 4 cases. *Presse Med* 1997;26(2):62-5.
- (268) Koch LE, Bierdermann H, Saternus K-S. High cervical stress and apnoea. *Forensic Sci Int* 1998;97(1):1-9.
- (269) Bohn D, Armstrong DC, Becker L, Humphreys RP. Cervical spine injuries in children. *J Trauma* 1990;30(4):463-9.
- (270) Ganesh A, Stephens D, Kivlin JD, Levin AV. Retinal and subdural haemorrhages from minor falls. *Br J Ophthalmol* 2007;91(3):396-7.
- (271) Morad Y, Wygnanski-Jaffe T, Levin AV. Retinal haemorrhage in abusive head trauma. *Clin Exp Ophthalmol* 2010;38(5):514-20.
- (272) Mungan NK. Update on shaken baby syndrome: Ophthalmology. *Curr Opin Ophthalmol* 2007;18(5):392-7.
- (273) Hedges T. A correlative study of orbital vascular and intracranial pressure in the Rhesus monkey. *Trans Am Ophthalmol Soci* 1963;61:589-637.
- (274) Walsh FB, Hedges TR. Optic nerve sheath hemorrhage. *Am J Ophthalmol* 1951;34(4):509-27.
- (275) Vanderlinden RG, Chisholm LD. Vitreous hemorrhages and sudden increased in intracranial pressure. *J Neurosurg* 1974;41(2):167-76.
- (276) Medele RJ, Stummer W, Mueller AJ, Steiger H-J, Reulen H-J. Terson's syndrome in subarachnoid hemorrhage and severe brain injury accompanied by acutely raised intracranial pressure. *J Neurosurg* 1998;88:851-4.
- (277) Bekavac I, Halloran JJ. Meningocele-induced positional syncope and retinal hemorrhage. *Am J Neuroradiol* 2003;24:838-9.
- (278) Hoving EW, Rahmani M, Los LI, de Lavalette VWR. Bilateral retinal hemorrhage after endoscopic third ventriculostomy: iatrogenic Terson syndrome. *J Neurosurg* 2009;110(5):858-60.
- (279) Nakagawa TA, Skrinska R. Improved documentation of retinal hemorrhages using a wide-field digital ophthalmic camera in patients who experienced abusive head trauma. *Arch Pediatr Adolesc Med* 2001;155(10):1149-52.
- (280) Adams GGW, Clark BJ, Fang S, Hill M. Retinal haemorrhages in an infant following RetCam screening for retinopathy of prematurity. *Eye* 2004;18:652-3.

- (281) Mulvihill AO, Jones P, Tandon A, Fleck BW, Minns RA. An inter-observer and intra-observer study of a classification of RetCam images of retinal haemorrhages in children. *Br J Ophthalmol* 2011;95(1):99-104.
- (282) Fleck BW, Tandon A, Jones PA, Mulvihill AO, Minns RA. An interrater reliability study of a new "zonal" classification for reporting the location of retinal haemorrhages in childhood for clinical, legal and research purposes. *Br J Ophthalmol* 2010;94(7):886-90.
- (283) Tandon A, McIntyre S, Yu A, Stephens D, Leiby B, Croker S, et al. Retinal haemorrhage description tool. *Br J Ophthalmol* 2011;95:1719-22.
- (284) Ng WS, Watts P, Lawson Z, Kemp A, Maguire S. Development and validation of a standardized tool for reporting retinal findings in abusive head trauma. *Am J Ophthalmol* 2012;154(2):333-9.
- (285) Scott AW, Farsiu S, Enyedi LB, Wallace DK, Toth CA. Imaging the infant retina with a hand-held spectral-domain optical coherence tomography device. *Am J Ophthalmol* 2009;147(2):364-73.
- (286) Muni RH, Kohly RP, Sohn EH, Lee TC. Hand-held spectral domain optical coherence tomography finding in shaken-baby syndrome. *Retina* 2010;30(4):S45-S50.
- (287) Saperia J, Lakhanpaul M, Kemp A, Glaser D. When to suspect child maltreatment: Summary of NICE guidance. *BMJ* 2009;339(b.2689).
- (288) H M Government. Working together to safeguard children. <http://www.education.gov.uk/publications/eOrderingDownload/00305-2010DOM-EN.pdf> 2 2010(Chapter 1)
- (289) CDC Centre for disease control and preventio. Injury prevention and control: violence prevention: child treatment. <http://www.cdc.gov/ViolencePrevention/childmaltreatment/definitions.html> 2013
- (290) Maguire S. Which injuries may indicate child abuse? *Arch Dis Child Educ Pract Ed* 2010;95:170-7.
- (291) Taylor D. Unnatural Injuries. *Eye* 2000;14:123-50.
- (292) Morad Y, Kim YM, Mian M, Huyer D, Capra L, Levin AV. Nonophthalmologist accuracy in diagnosing retinal hemorrhage in the shaken baby syndrome. *J Pediatr* 2003;142(4):431-4.
- (293) Koozekanani DD, Weinberg DV, Dubis AM, Beringer J, Carroll J. Hemorrhagic retinoschisis in shaken baby syndrome imaged with spectral domain optical coherence tomography. *Ophthalmic Surg Lasers Imaging* 2010;9:1-13.
- (294) Kemp AM. Investigation subdural haemorrhage in infants. *Arch Dis Child* 2002;86(2):98-102.