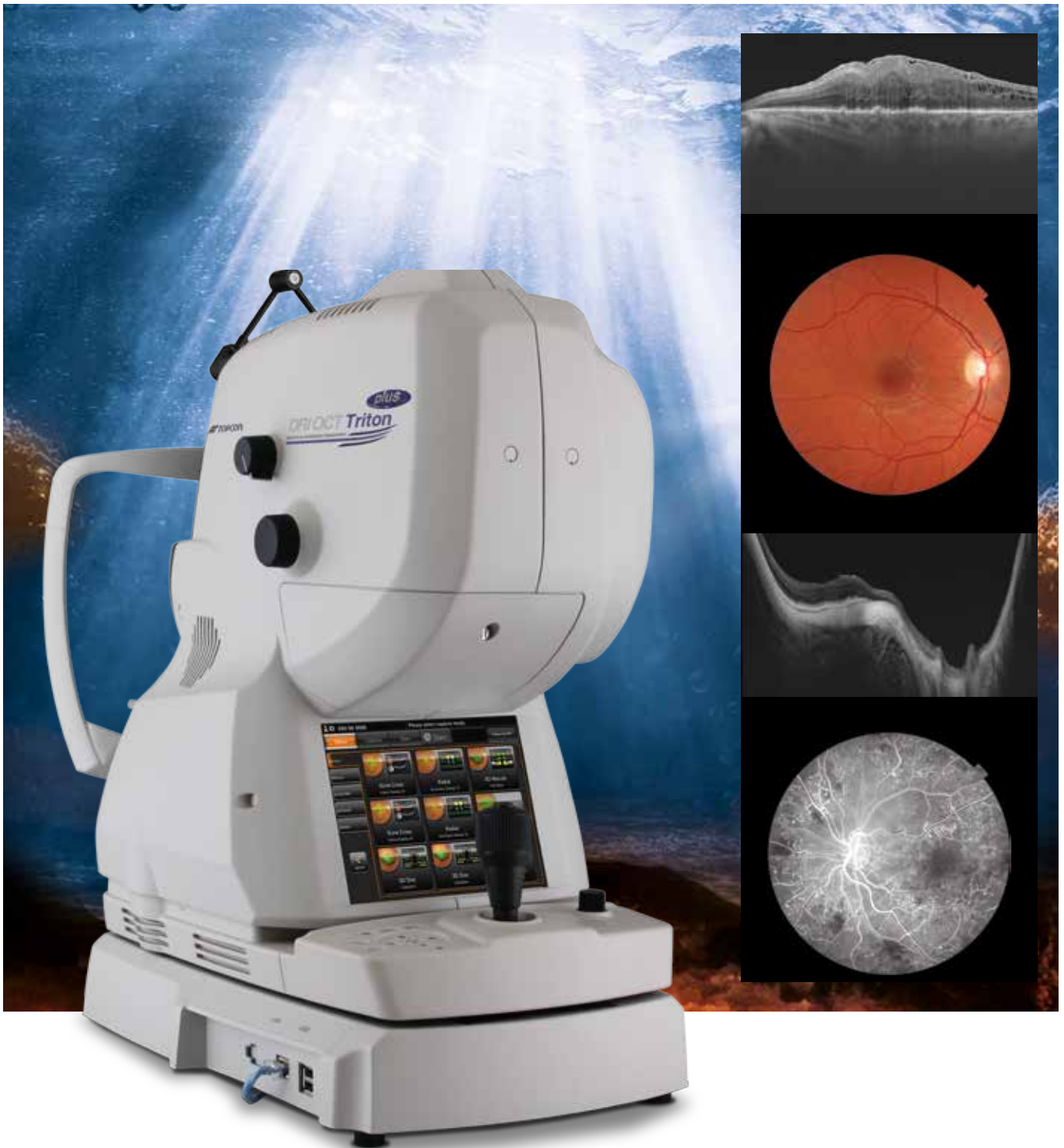

DRI OCT Triton Series

Swept Source Optical Coherence Tomography



An underwater photograph showing sunlight rays filtering through the water, illuminating a coral reef at the bottom. The scene is deep blue with bright, ethereal light beams creating a dramatic atmosphere.

The best just became better: TOPCON's new dimension of OCT technology.

See, Discover, Explore
TOPCON Swept Source
OCT with multi-modal
fundus imaging.

Swept Source OCT with multi-modal fundus imaging



New Dimension of OCT Imaging: DRI OCT Triton

Swept Source OCT

- » **More confident initial diagnosis and ability to track change over time**
 - Deep scanning and high-resolution TOPCON swept source technology, penetrates cataract and hemorrhage, providing more information for better patient care.
- » **Greater clinical efficiency**
 - Next generation SMARTTrack™ eye tracking combined with ultra-fast swept source technology maximizes data quantity to give a truer record of your patient's eye while minimizing image acquisition time.
- » **Greater patient comfort**
 - Rapid, invisible scan, and SMARTTrack™ minimize the impact of eye movements for patients who struggle to maintain fixation.
- » **Single scan capture of comprehensive data**
 - New, deep-range swept source OCT and TOPCON's color fundus photography, captures retinal and choroidal data in a single action for a scan that is fast, simple and comfortable for operators and patients.

DRI OCT Triton from TOPCON delivers the future of OCT today! The first commercially available swept source imaging combined with color fundus photography. Next generation technologies provide unprecedented scan and the most comprehensive images for fast, simple, and superior diagnosis and monitoring of anterior segment and retinal abnormalities.



PERFORMANCE
YOU CAN COUNT ON



Our third generation OCT technology

TOPCON OCT legacy

In **2006** TOPCON was the first company to introduce the commercial Spectral Domain (SD) OCT.

Spectral Domain had many advantages over Time Domain OCT. The first SD OCT of the TOPCON line was the TOPCON 3D OCT-1000, which was the world's first instrument to incorporate a true color fundus camera, which proved to be a valuable tool alongside OCT analysis.

In **2009** TOPCON introduced the next model, the 3D OCT-2000 and the 3D OCT-2000 FA / FAplus which converted the OCT into a unique multi-modal tool for OCT imaging, color fundus images, FA and FAF images.

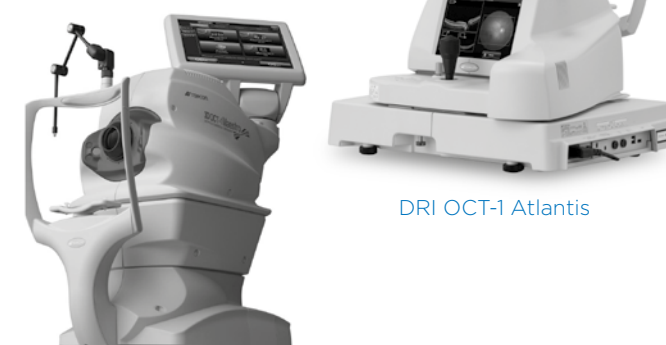In **2012** TOPCON introduced the first commercial retinal Swept Source OCT, the DRI OCT-1 Atlantis. The Atlantis produces stunning images of the vitreous body and choroidal structures.

In **2013** TOPCON introduced the world's first fully automated SD OCT with integrated color fundus camera, the 3D OCT-1 Maestro. The 3D OCT-1 is operated by 1 touch of your finger tip, which is unique in the world.



3D OCT-1000

3D OCT-2000 Series



DRI OCT-1 Atlantis

3D OCT-1 Maestro



DRI OCT Triton, Swept Source, 3rd generation OCT technology

TOPCON continues its philosophy of developing innovative technologies with the introduction of a new dimension of OCT technology using Swept Source.

TOPCON is the first in the world to introduce a combined anterior & posterior Swept Source OCT, the DRI OCT Triton. The DRI OCT Triton incorporates full color high resolution fundus photography and FA & FAF imaging¹.

¹FA photography and FAF photography can be performed in only DRI OCT Triton plus.

Swept Source OCT Deep range imaging

Swept Source OCT deep range imaging

Swept Source technology & 1,050nm wave length

Swept source OCT provides a significant improvement over conventional OCT. Due to the optimized long wavelength scanning light (1,050nm), there is better penetration of the deeper layers of the eye. Furthermore, this scanning light also penetrates better through cataracts, hemorrhages, blood vessels and sclera.

The world's fastest² scanning speed 100,000 A-Scans/second

Approximately twice higher scan speed³ will bring more scans for a single B scan image, and more informative image supports efficiency and quality of diagnosis.

² According to TOPCON survey -Feb. 2015. ³ Compared with TOPCON SD OCT.

Better Penetration

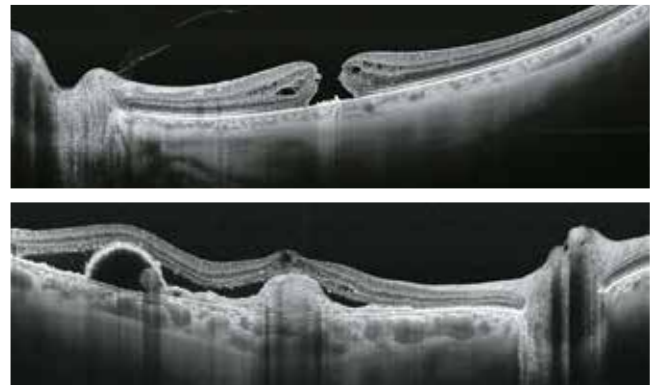
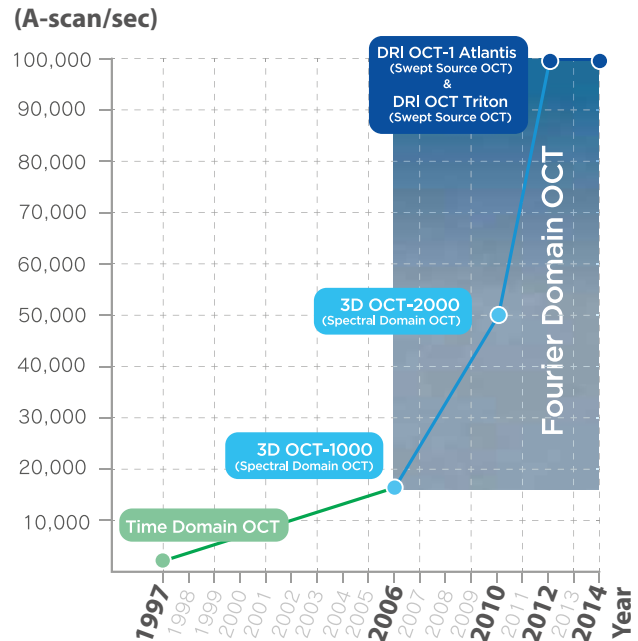
The high penetration of the swept source light can easily and clearly visualize deep layers in the eye, such as choroid and sclera. A further benefit of Swept Source is that it can clearly visualize both the vitreous and choroid in a single scan, that are uniformly clear and noise-free. This eliminates the need for time consuming vitreous/choroidal combination scans.

Wide and deep scans

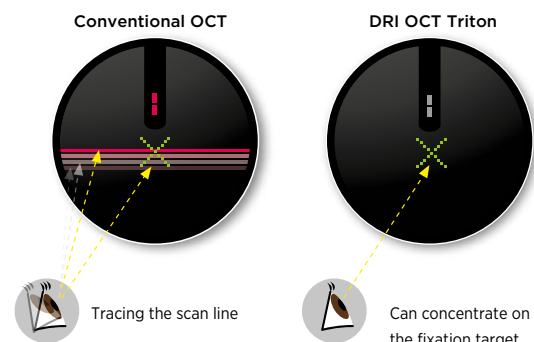
In one single image the vitreous & choroid are revealed in a crystal clear way. The DRI OCT Triton enhances visualization of outer retinal structures and deep pathologies. The DRI OCT Triton automatically detects 7 boundaries including the chorio-scleral interface. The 12mm B-scan covers both the macular area and the optic disc.

Invisible scan lines

The invisible 1,050nm wavelength does not distract patients. Patients do not see the scanning line, which is an advantage with elderly patients and children. Reduction in movement artifacts and increased repeatability.



OCT image courtesy: Professor Jose Maria Ruiz Moreno, University of Albacete, Spain.



Swept Source OCT Explore & analyze

See, Discover, Explore

DRI OCT Triton offers a unique combination of anterior & posterior OCT imaging. In both cases detailed structures are revealed. With DRI OCT Triton you can scan a large area of the eye with wide-field OCT patterns such as the 12 X 9mm scan or the 16mm anterior scan.

Time efficiency - create one single overview

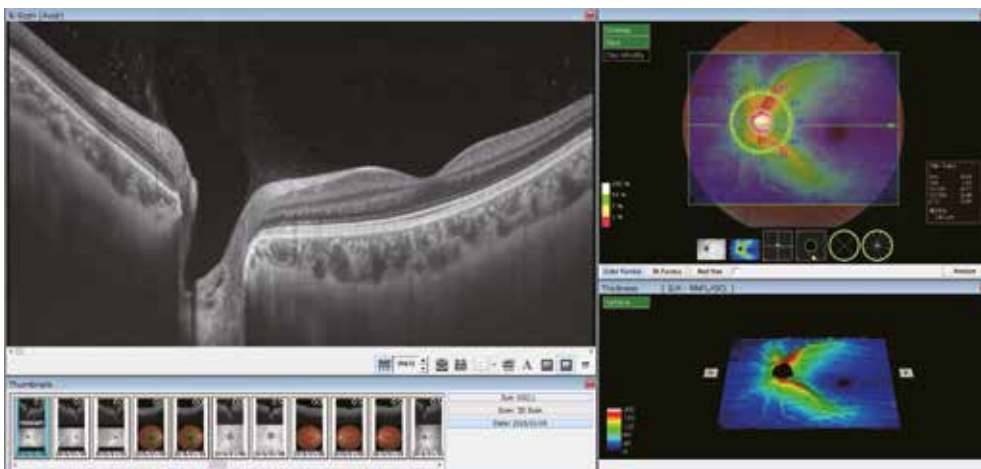
Combination scans cover the macular and disc areas in a single shot, and offer both macular and Retinal Nerve Fiber Layer (RNFL) analysis. Combination scans are time efficient for the operator and convenient for the patient. Combination scans allow both macular and disc analysis in one overview.

Accurate choroidal thickness maps

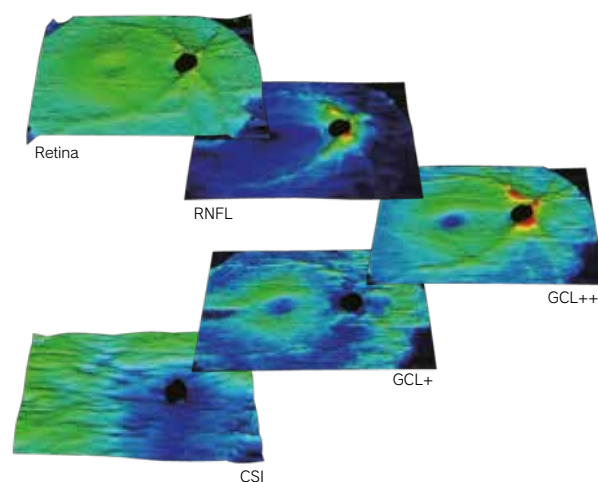
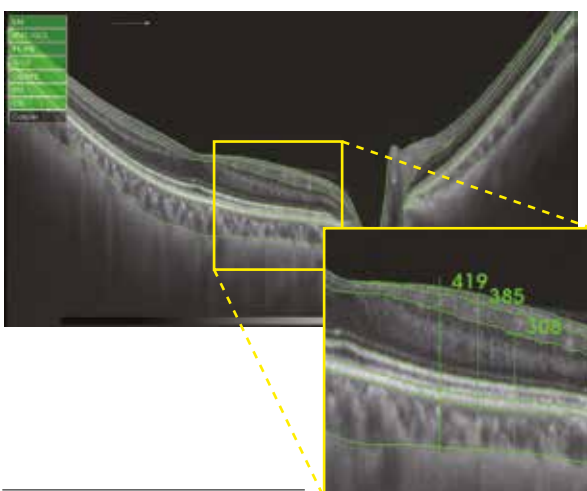
For the first time, accurate high speed choroidal thickness maps can be produced; which is crucial, not only for early disease recognition, but also for the monitoring of inflammatory abnormalities. The choroid reveals valuable information about the health of an eye. A thin choroid can be an indication of myopic or choroidal atrophy for example. A thick choroid may indicate the presence of choroiditis, Central Serous Chorioretinopathy (CSCR) or hyperopia. Tumor visualization and classification is enhanced due to the penetration of the Swept Source*.

* Retinal Physician, Volume: 10 , Issue: March 2013, page(s): 42 - 48

Combination scan



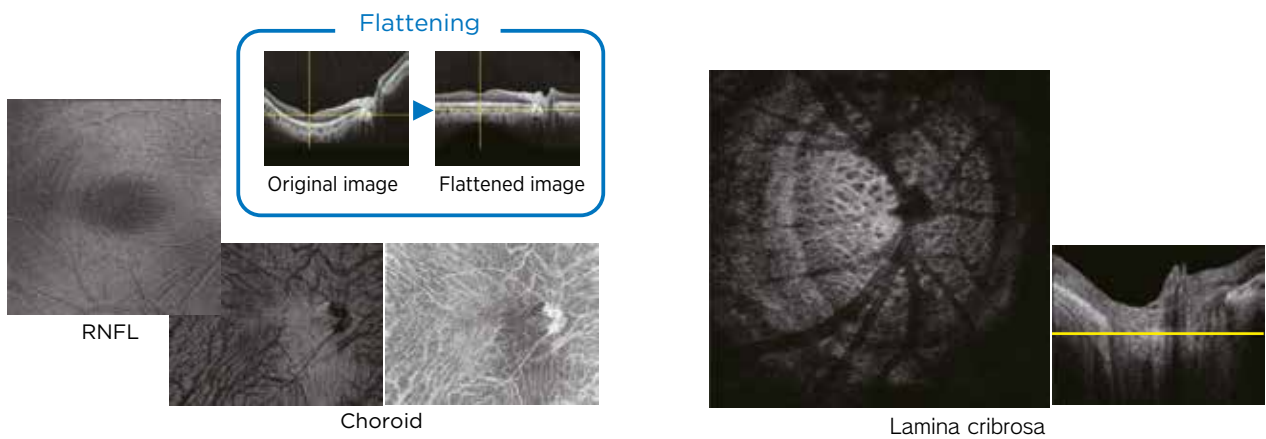
7 boundaries segmentation / 5 layers thickness map / caliper function



En Face OCT imaging*

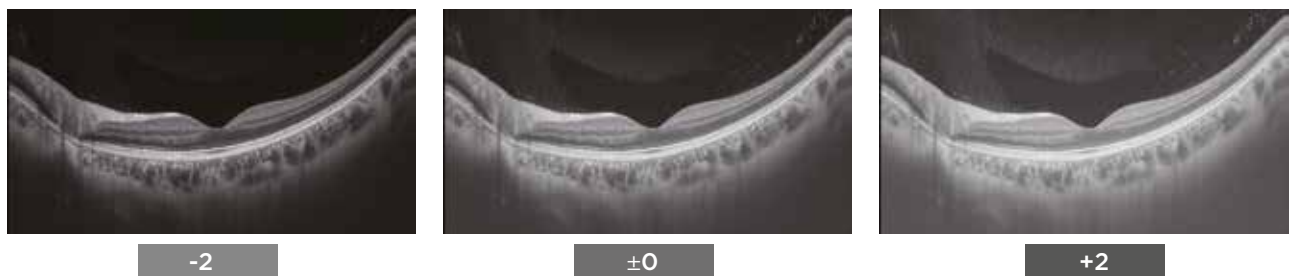
En Face imaging allows for independent dissection of the vitreoretinal interface, retina, Retinal Pigment Epithelium (RPE), and choroid, and uniquely projects these layers so that macular pathology throughout the posterior pole can be studied and correlated with a patient's symptoms, their abnormality, and its progression.

* optional software



EVV (Enhanced Vitreous Visualization™)

Enhanced vitreous visualization with DRI OCT Triton helps assess the natural history and treatment response in vitreoretinal interface abnormalities. Contrast can be quickly adapted to the needs of the physician, depending on the area of interest. This time- saving function avoids the need for elaborate tools in photographic software.



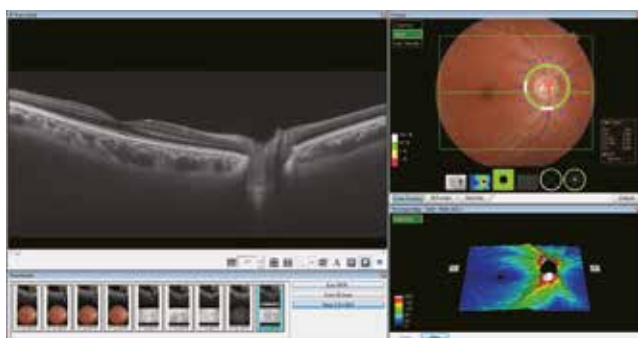
5 in 1 diagnostic tool

See, Discover, Explore the ultimate 5-in-1 instrument

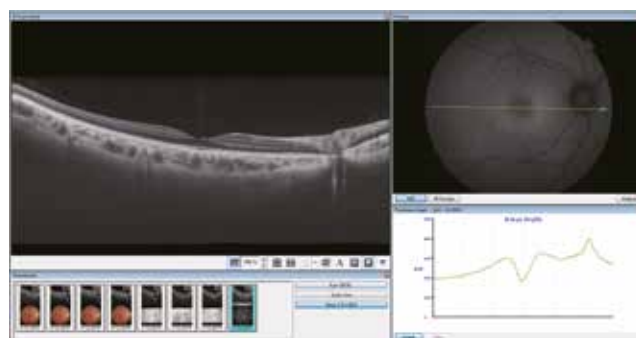
Multi modal fundus imaging

The DRI OCT Triton offers a true color, non mydriatic fundus image while using a very low intensity flash.

This unique feature is a perfect tool for identifying the location of scans in the eye utilizing TOPCON's patented Pinpoint Registration™. The DRI OCT Triton Plus offers a wide range of diagnostic options with multi-modal color fundus imaging, Fluorescein Angiography (FA) and Fundus Autofluorescence (FAF) for even more diagnostic possibilities¹. For the first time Pinpoint registration™ will be available with fundus auto fluorescence and Swept Source OCT.



OCT + Color fundus

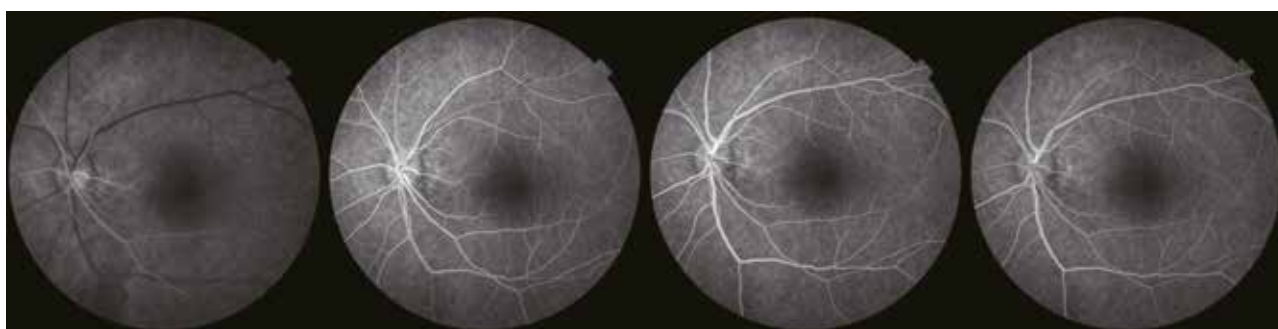

OCT + FAF

FA imaging

FA imaging is incorporated in the DRI OCT Triton Plus.

FAF imaging is also available with the DRI OCT Triton Plus.



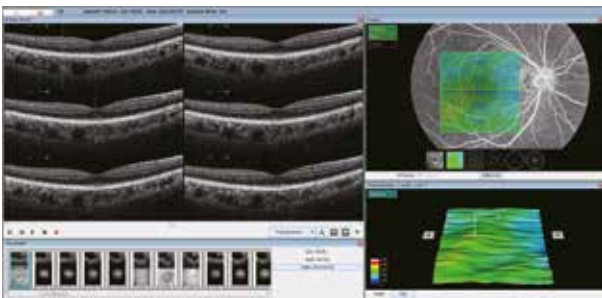
Timeline

¹ FA photography and FAF photography can be performed using only DRI OCT Triton plus.

High quality imaging

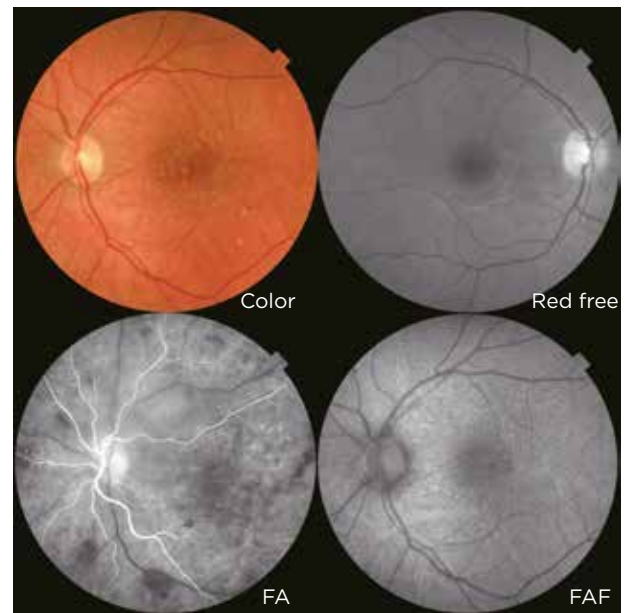
Import function

Color / FA / FAF / Indocyanine Green Angiography (IA) images can be imported with an OCT scan captured at a selected location on the image. By double-clicking a specific point on the OCT image or the imported photograph, the location will be indicated on both images with a green cross. Comparison across a range of imaging modalities may better enhance understanding of disease pathophysiology.



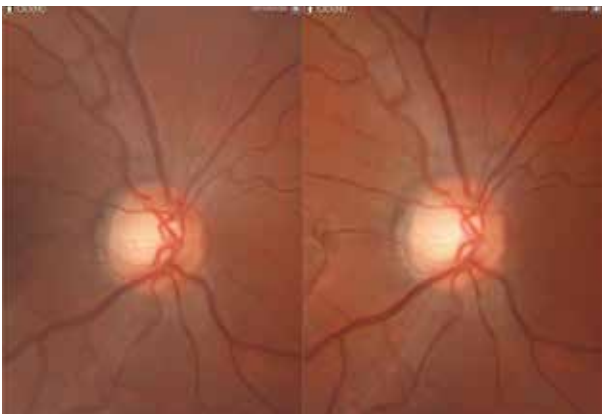
High quality true fundus images

The resolution and contrast of the retinal images has been specifically tuned to give a natural appearance.



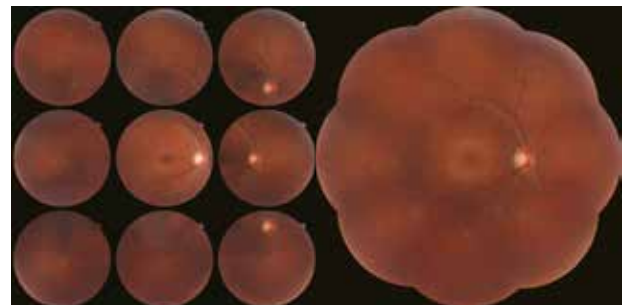
Stereo photography²

Images taken in the stereo photography mode show the true color fundus photo in 3D, revealing details about depth. In the stereo photography mode, software assists acquisition of the stereo pair. Following the prompts on the screen, a stereo pair for stereo viewing can be quickly and easily acquired.



Auto Mosaic²

The panorama function provides wide coverage of the retina from the central macular area out to the periphery; almost the complete fundus.



² Optional software

Best solution for your workflow

New tracking system - SMARTTrack™

SMARTTrack™ is a very useful tool to compensate for the ever present involuntary eye movements (microsaccades).

SMARTTrack™ allows the automatic acquisition of a follow-up scan in precisely the same anatomical location.

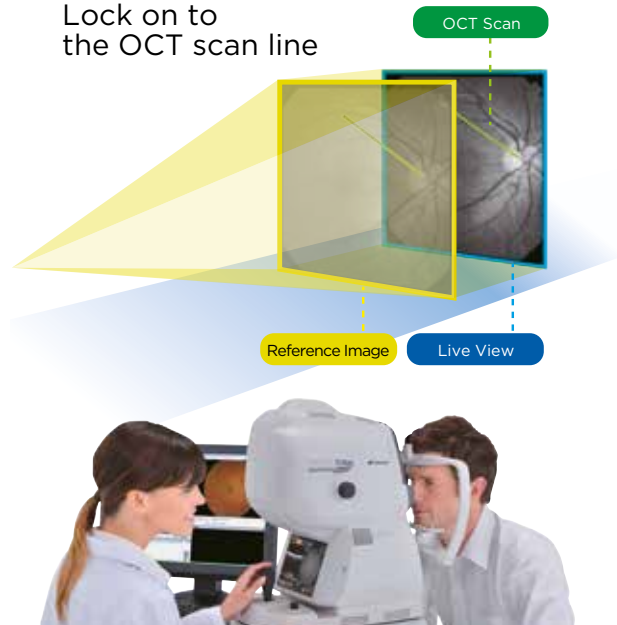
SMARTTrack™ enhances the user-friendliness of the machine.

- » Fundus Guided Acquisition (FGA)
- » Follow up
- » Tracking



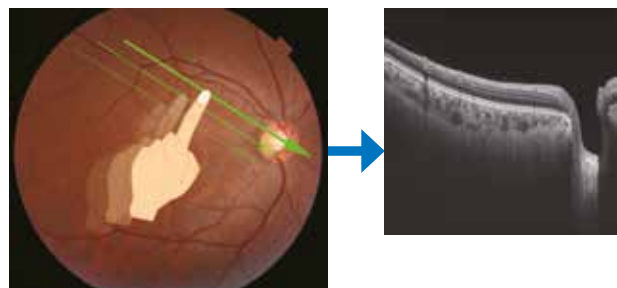
NEW [SMARTTrack™]

Lock on to the OCT scan line



Fundus Guided Acquisition (FGA)

The DRI OCT Triton simultaneously acquires an OCT and fundus image. With FGA the operator can choose to take a fundus image (or import an image), select scan area and DRI OCT Triton will automatically produce a B scan of the selected area.



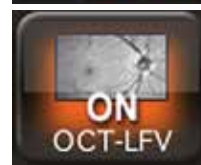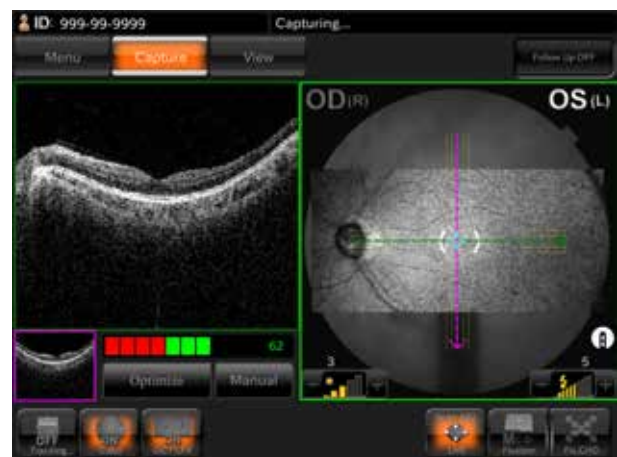Live Fundus View (LFV)

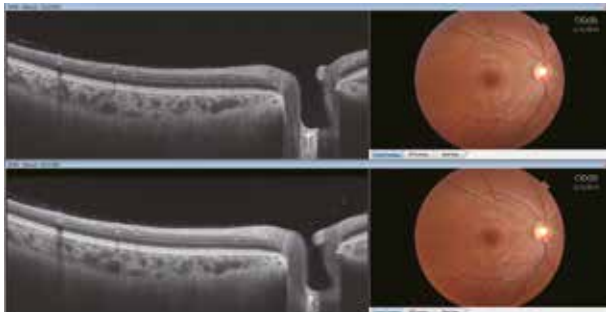
Due to the fast scanning speed, a live En Face fundus image can be generated. The live fundus view is an ideal tool for precisely locating the scan position.

Ease of use through small pupil

OCT-LFV image will show the live fundus image clearly even in an eye with a small pupil*. The disc, retinal vessels and scanning position will be very easy to see.

* 3.3mm to 4.0mm Diameter pupil



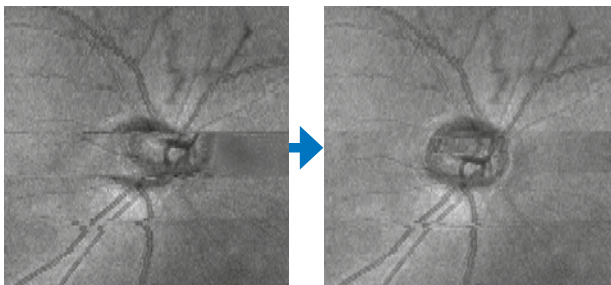


Follow-up function

For accurate diagnosis and time savings at subsequent visits, the follow-up function is a vital tool for retrieving and re-analyzing the same anatomical location.



Follow-up icon (sample)

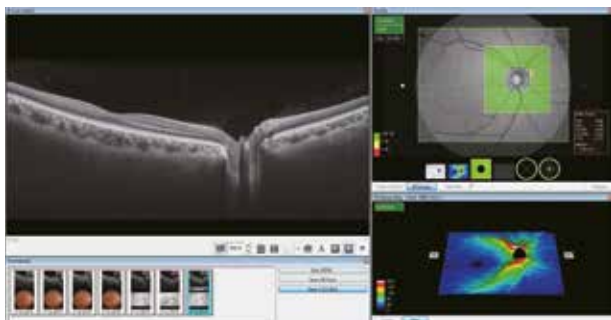


Before compensation

After compensation

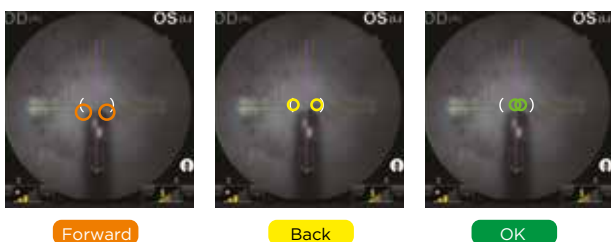
Motion correction

DRI OCT Triton is equipped with an advanced motion correction tool that can compensate for eye movement in all 3 dimensions. In part, this motion is corrected with an automatic rescanning function, saving time for the operator.



OCT capture mode without retinal photography

DRI OCT Triton has the option of capturing a 3D scan with, or without, color fundus photography in order to avoid a miotic response, and to facilitate capturing a scan for small pupil patients.



Forward

Back

OK

Alignment Guidance

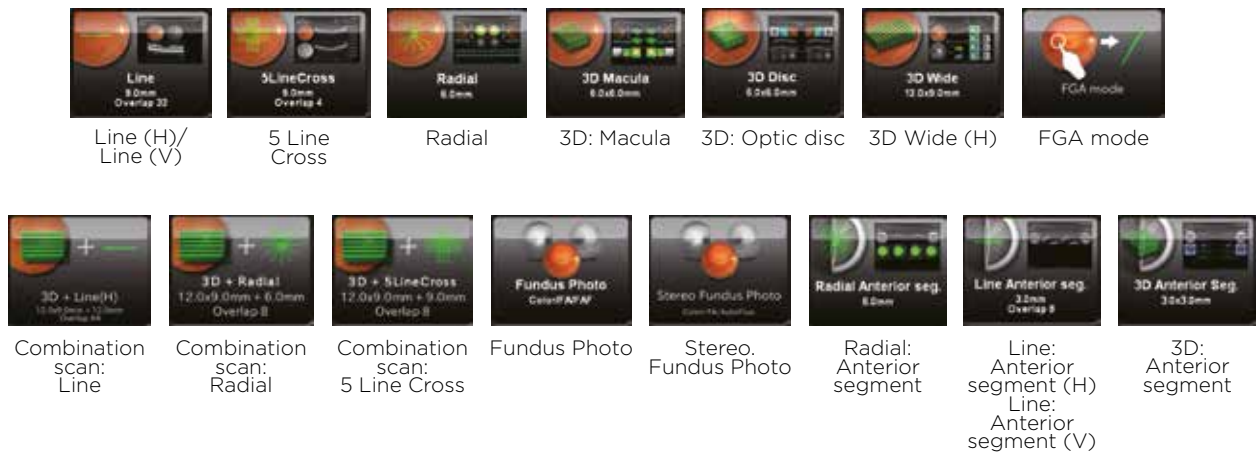
Different color dots on the monitor help the operator capture more easily. Many automatic functions are incorporated into the DRI OCT Triton to help save time, and support operation efficiency.

- When you take Color/ FAF images: Auto focus function/ Auto shoot function
- When you take OCT images: Auto focus function/ Auto Z & Z-lock function

Detailed Comprehensive Reports

Rich scan protocols

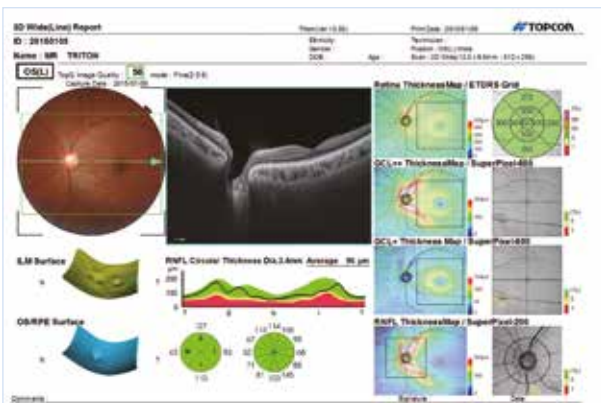
A wide range of scan patterns is clearly laid out, allowing the operator to quickly select the correct pattern.



Unique scan modes

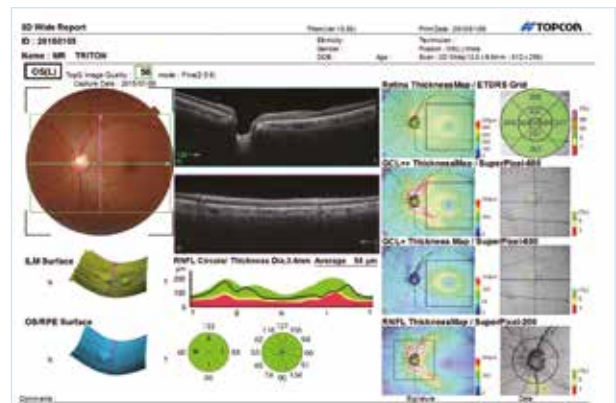
The Combination scan and 12mm x 9mm 3D Wide scan offers information on both macular and RNFL analysis. This is time efficient for the operator as one single shot will provide the necessary data analysis.

Glaucoma and macular imaging and analysis



» Combination scan

This new scan pattern provides both 3D wide scan (12mm x 9mm) and Line / 5 line cross / radial scan. Previous OCT models do not offer the option to capture B scan and 3D images at the same time. The new combination scan provides a thickness map and a clear B scan image / images from the 3D data.

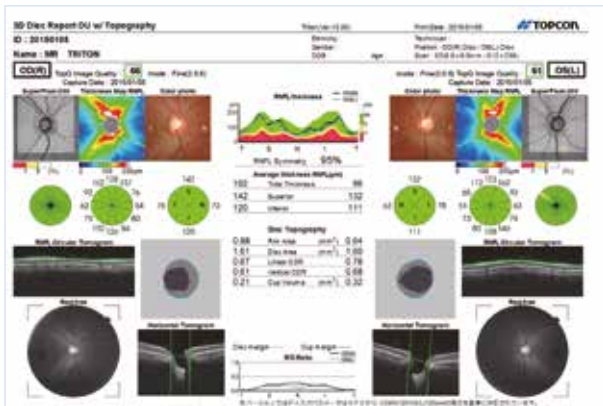


» 12mm x 9mm 3D Wide scan

One rapid scan can cover both the macular and disc areas providing more information for efficient diagnosis. This mode provides macular analysis, thickness map of RNFL, GCL+IPL, RNFL+GCL+IPL and a significance map; all data supporting the diagnosis of macular abnormality and glaucoma.

Complete OCT functionality Fully comprehensive analyzed data

Glaucoma analysis

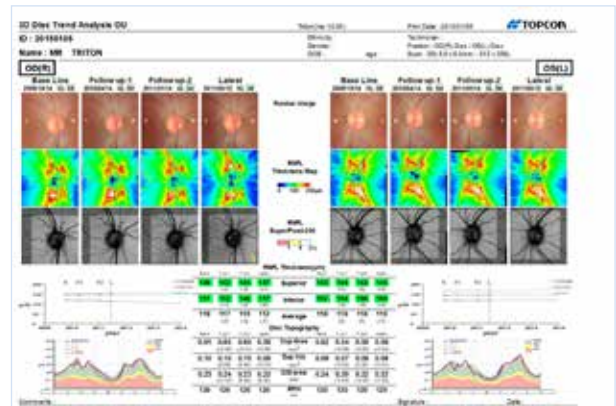


» 3D disc analysis

Disc topography combining fundus photography, various peripapillary parameters, and RNFL thickness is available. A normative RNFL database is also incorporated.

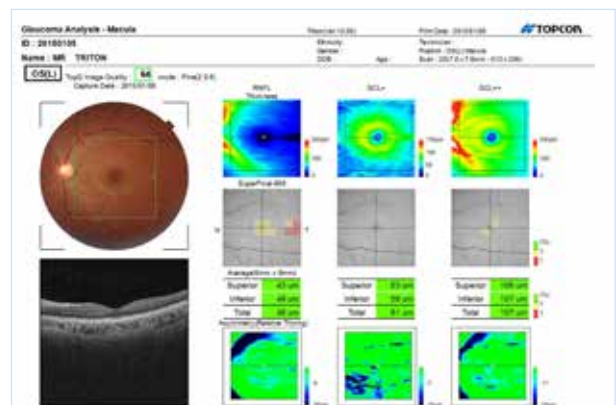
» 3D Macula glaucoma analysis

With vertical box scan of the macular area, Ganglion Cell Complex (GCC) analysis is available and a normative database for Retinal Nerve Fibre Layer (RNFL), GCC and retina thickness is incorporated.



» Trend analysis (RNFL)


3D disc scans can be compared and analysed over time, which is useful for glaucoma follow-up.



Analysis of 3D Macula

» Trend Analysis (3D Macula Analysis)

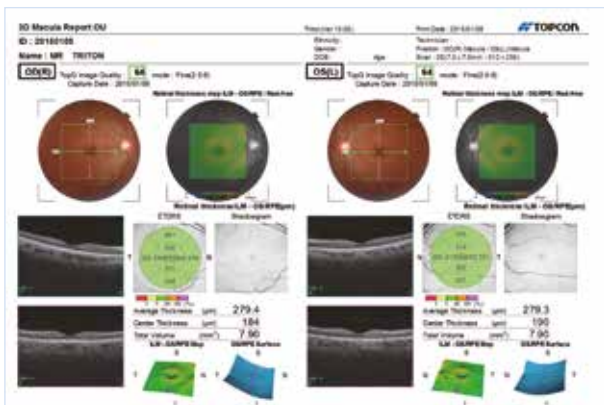
Macular Analysis of up to 4 sets of macular data (8 results for both eyes), is shown in a report, enabling you to compare old and new patient data.



Complete OCT functionality

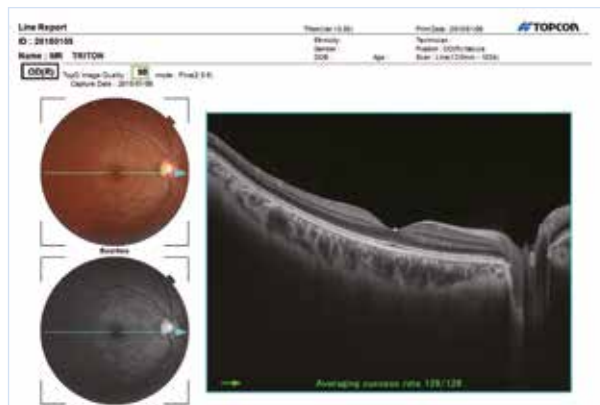Full comprehensive data analysis

Macular analysis



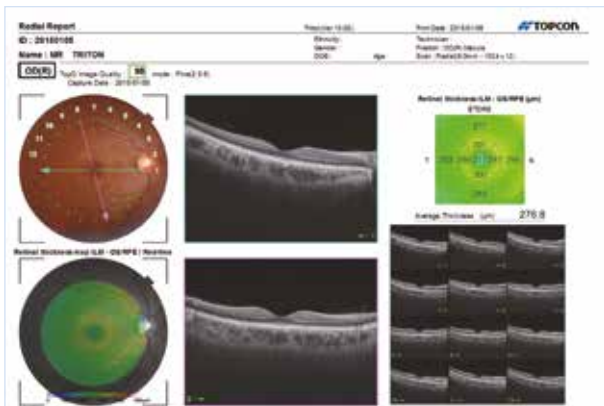
» Analysis of 3D Macula

A horizontal box scan can be captured in the macular area, allowing a 3D image to be created; useful for fully understanding the form of the macular area. A thickness map and normative database for retinal thickness are available.



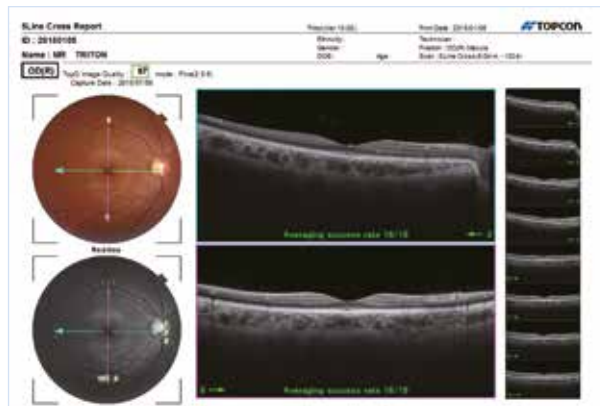
» Line scan

This captures a high resolution B-scan with a maximum of 50 overlapping slices.



» Radial scan

This rapidly captures 12 radial scans of the target area, allowing detailed understanding of a particular area.



» 5 Line Cross Scan

This instantaneously captures 5 line scans horizontally and 5 lines scans vertically. This is useful for screening and follow-up as it will not miss the target position during quick scanning.

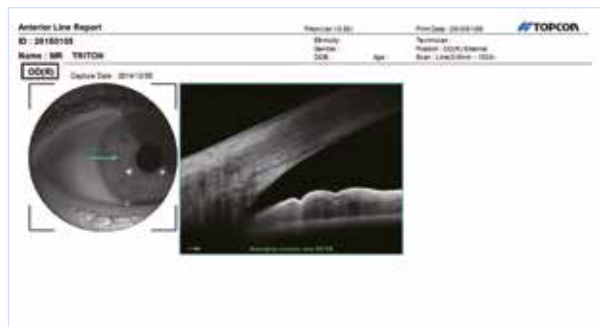
Anterior

» Anterior radial scan

This captures 12 radial scans of the cornea to comprehensively examine the condition of the central cornea. Corneal curvature and corneal thickness maps are also available.

» Anterior line Scan

This allows the angle area to be observed.

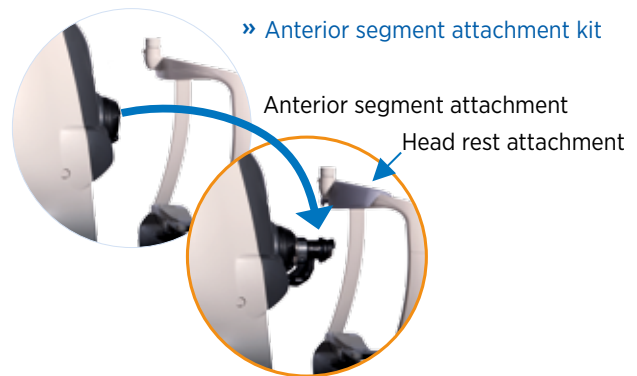
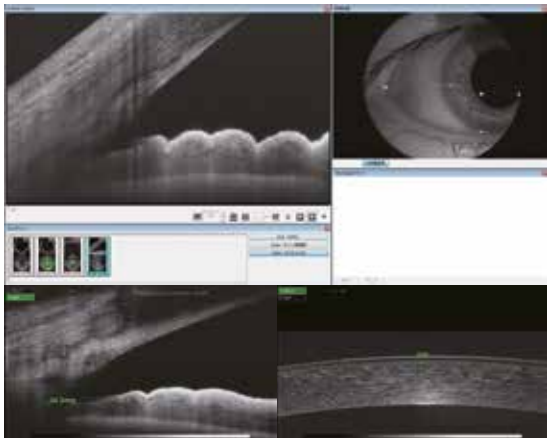


Optional anterior segment analysis

Anterior segment analysis*

The DRI OCT Triton can be extended to include anterior imaging, making the Swept Source a versatile diagnosis tool for both anterior and posterior imaging.

The anterior attachment ensures sharp images, even in the periphery of the cornea and in depth images of the anterior chamber.

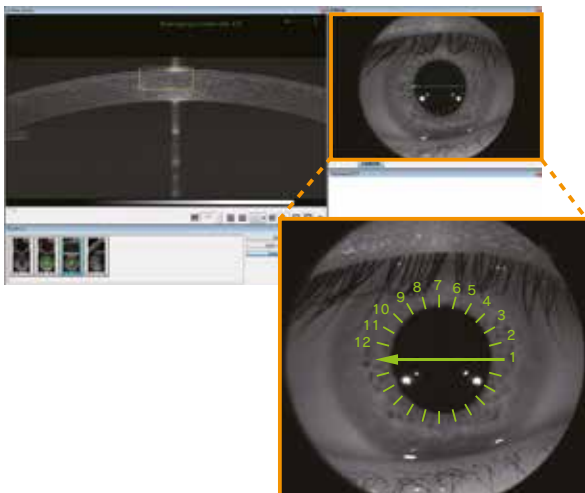


*Observation & photography of anterior segment can be performed only when the optional anterior segment attachment kit is used.

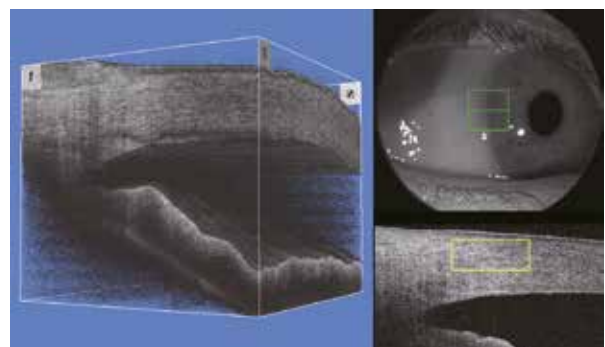
» OCT image C scan length 16mm



» Radial anterior segment



» 3D anterior segment

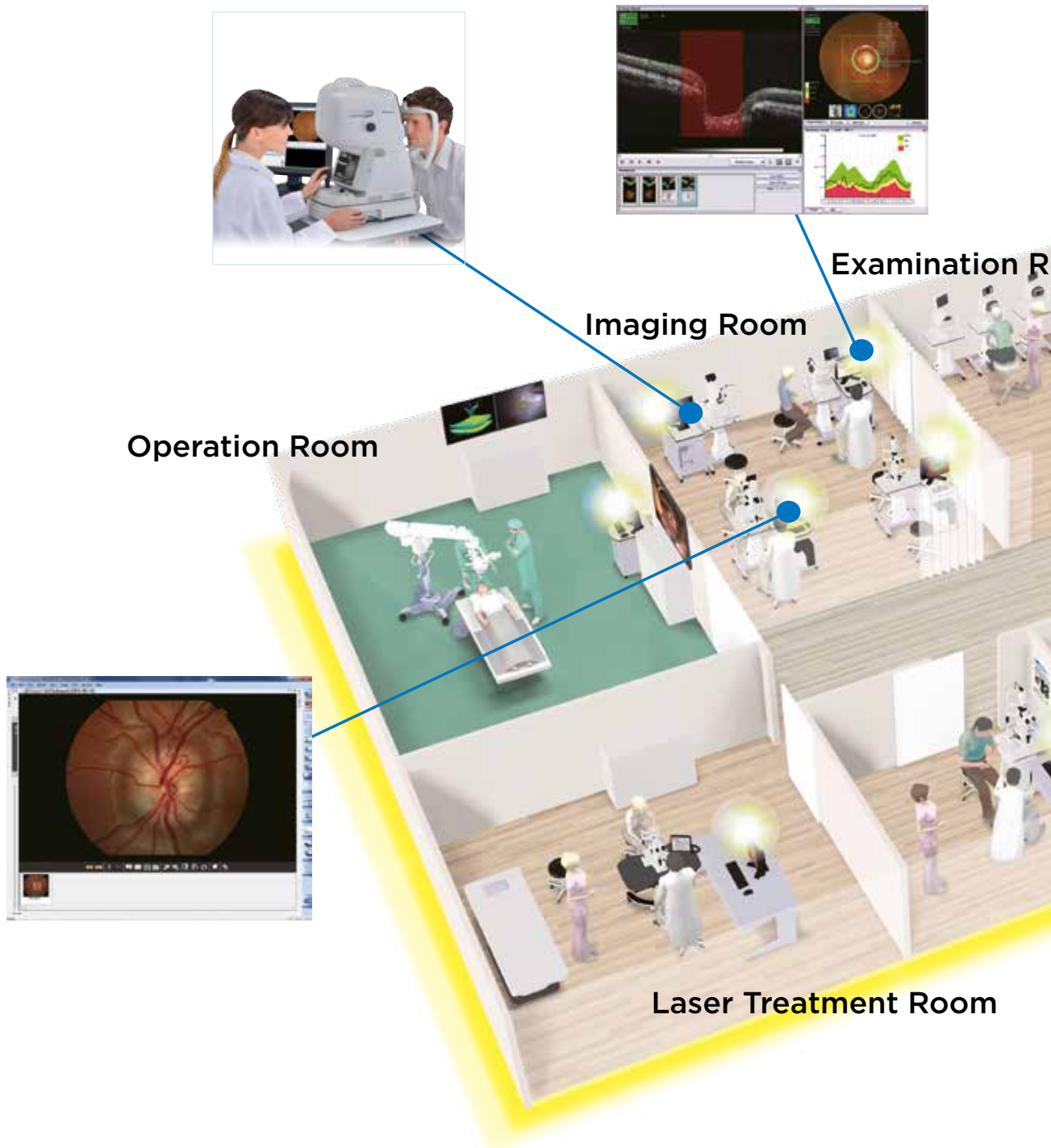


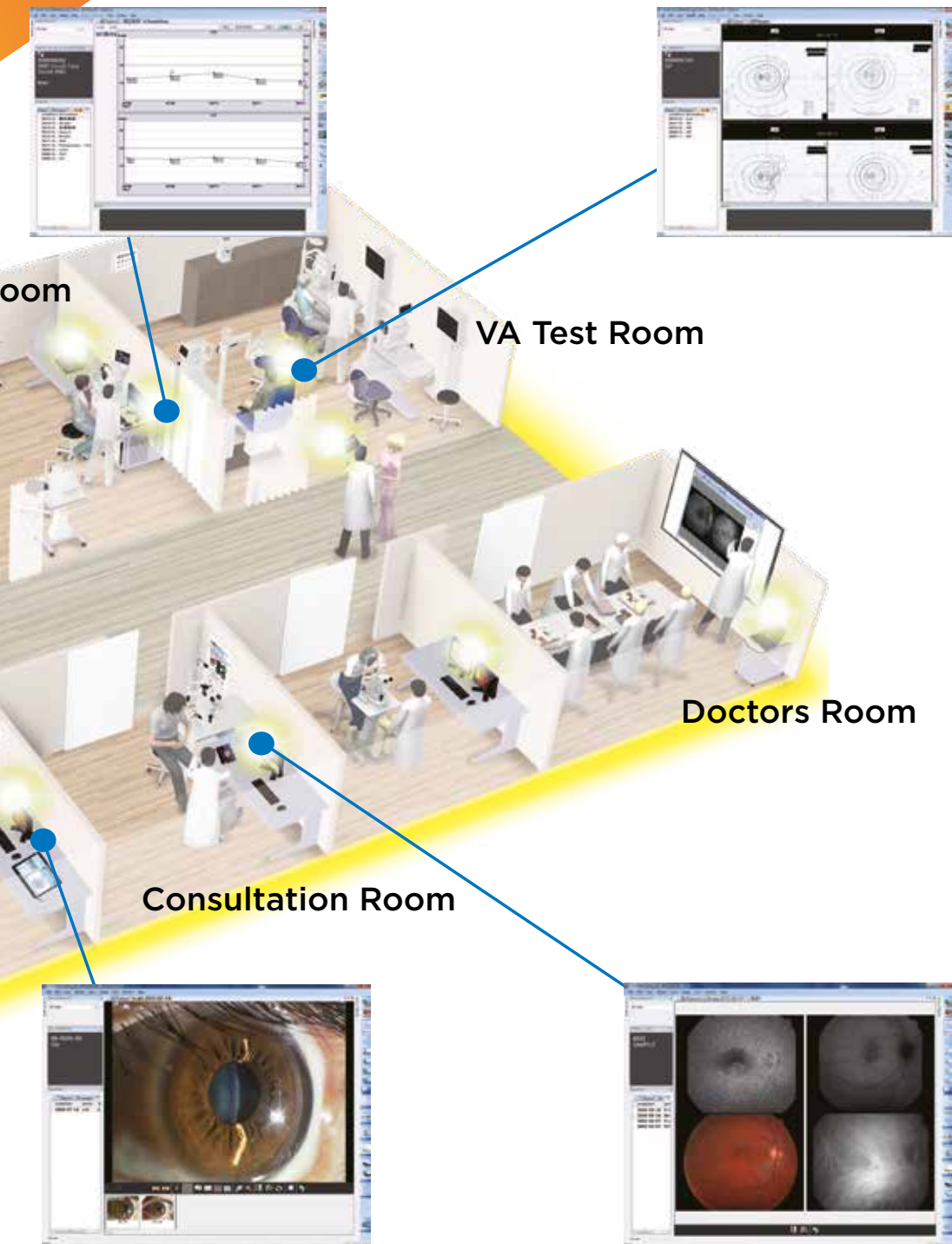
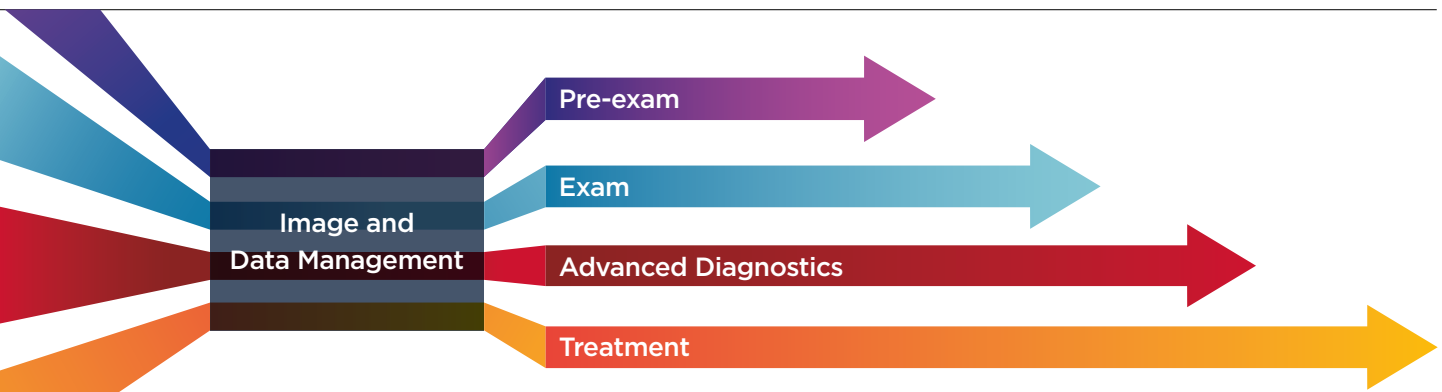
Connectivity

Connectivity

All images that are generated with the DRI OCT Triton can be examined in viewing software. OCT scans from other TOPCON OCT devices can also be viewed.

The Viewer software can be integrated in a network enabled hospital set up for an improved workflow.

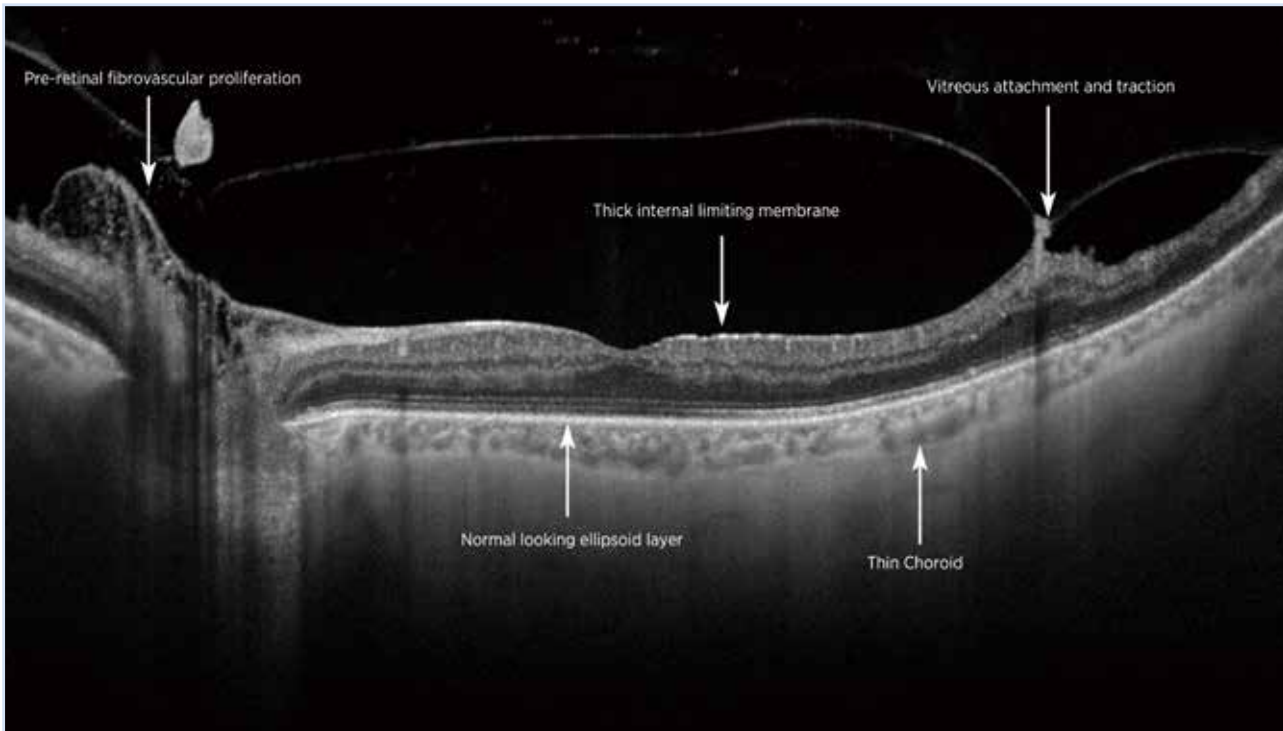




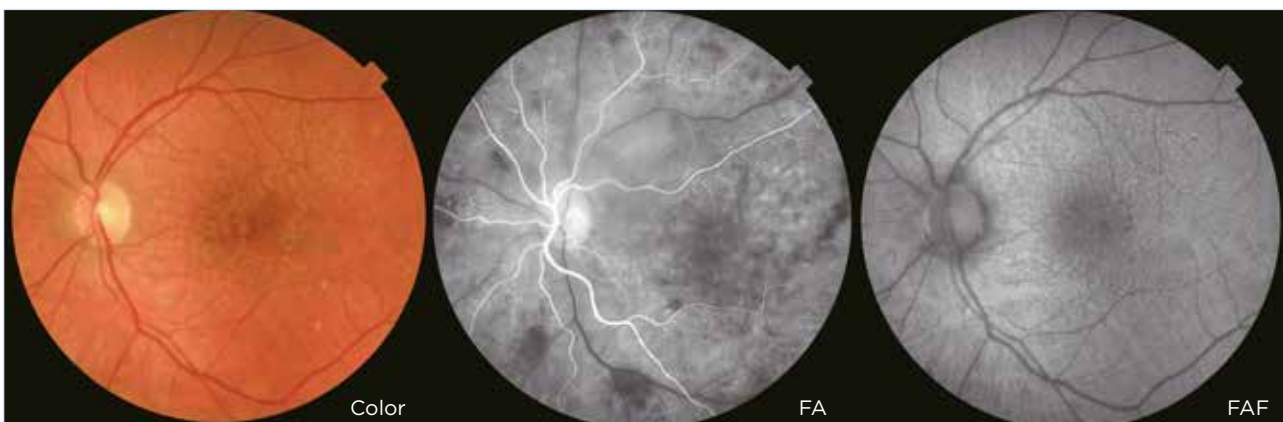
See, Discover, Explore

Swept source OCT with multimodal true fundus imaging

Proliferative Diabetic Retinopathy



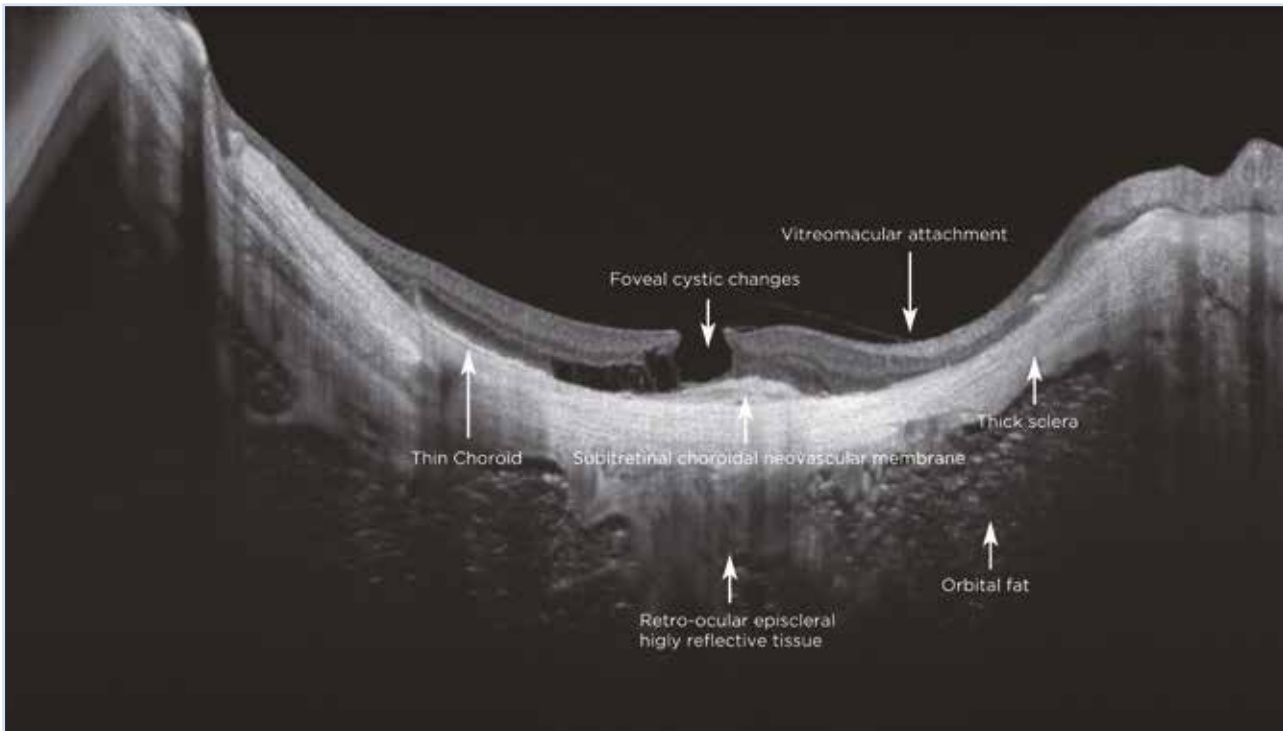
Prof. P. E. Stanga, Manchester Royal Eye Hospital, Manchester Vision Regeneration (MVR) Lab at NIHR/ Wellcome Trust Manchester CRF & University of Manchester



Prof. P. E. Stanga, Manchester Royal Eye Hospital, Manchester Vision Regeneration (MVR) Lab at NIHR/ Wellcome Trust Manchester CRF & University of Manchester

* FA photography and FAF photography can be performed using only DRI OCT Triton plus.

Pathological Myopia



Prof. P. E. Stanga, Manchester Royal Eye Hospital, Manchester Vision Regeneration (MVR) Lab at NIHR/ Wellcome Trust Manchester CRF & University of Manchester

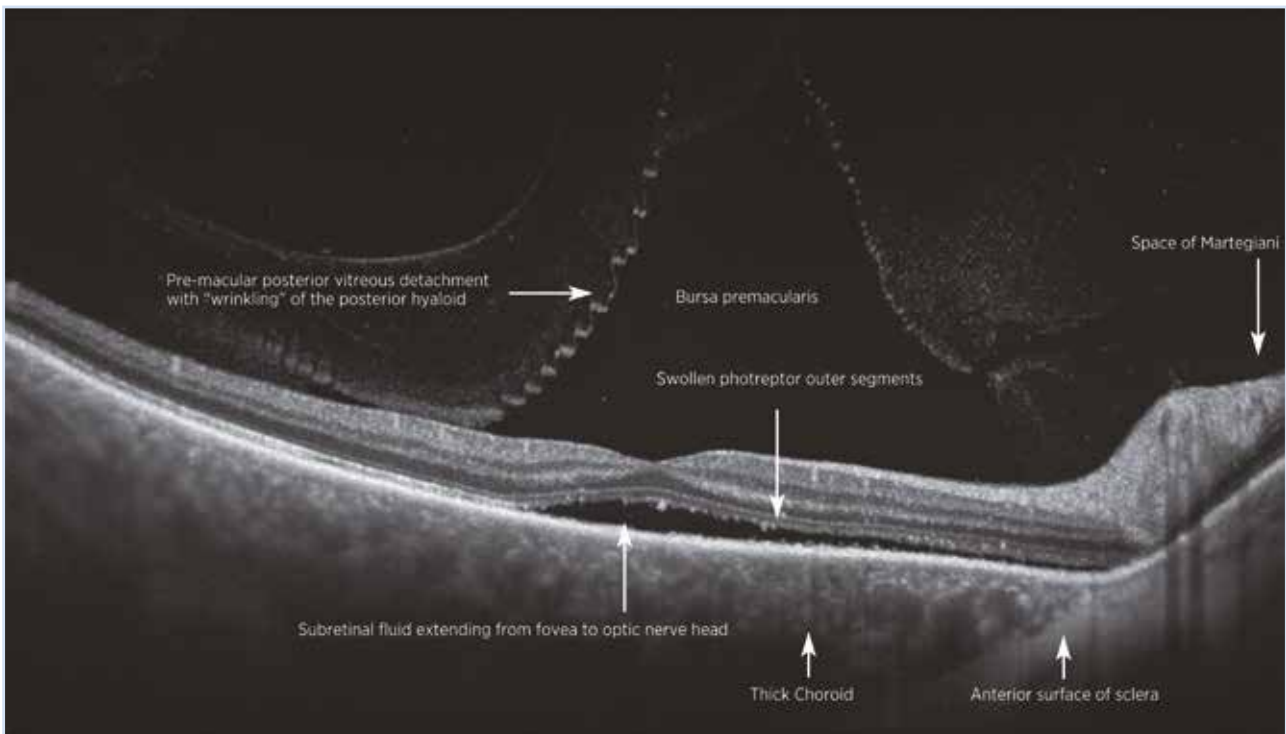
“ Swept source adds a new dimension to OCT. The TOPCON DRI swept source OCT is easy to use, provides unique clinical information, and has improved my practice. For the first time we can in-vivo visualize not only the vitreo-retinal interface but also the cortical vitreous which is important at the time when more and more therapies are delivered via intra-vitreous injections. Deeper imaging brings choroidal assessment into the picture and shows the role and value of measuring choroidal thickness, helping guide my clinical decisions. Seeing more helps guide my therapy and allows me to treat more effectively. I find Swept Source OCT an essential tool to look for biomarkers of disease regression or progression ”

Prof. P. E. Stanga, Manchester Royal Eye Hospital, Manchester Vision Regeneration (MVR) Lab at NIHR/ Wellcome Trust Manchester CRF & University of Manchester

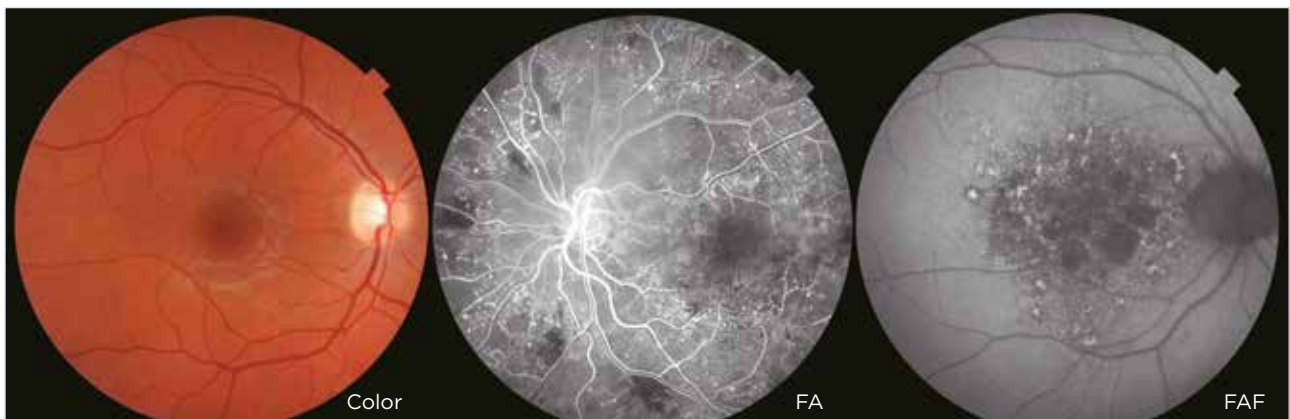
See, Discover, Explore

Swept source OCT with multimodal true fundus imaging

Central Serous Retinopathy



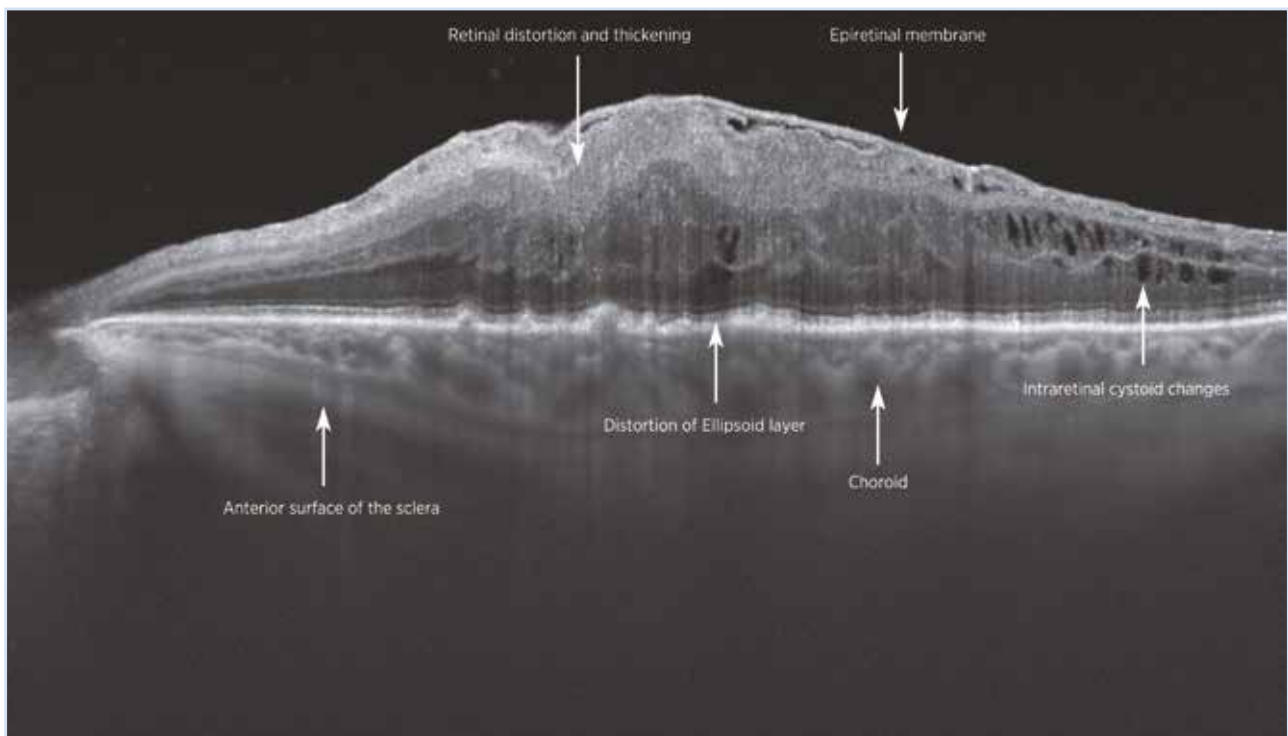
Prof. P. E. Stanga, Manchester Royal Eye Hospital, Manchester Vision Regeneration (MVR) Lab at NIHR/ Wellcome Trust Manchester CRF & University of Manchester



Prof. P. E. Stanga, Manchester Royal Eye Hospital, Manchester Vision Regeneration (MVR) Lab at NIHR/ Wellcome Trust Manchester CRF & University of Manchester

* FA photography and FAF photography can be performed using only DRI OCT Triton plus.

Macular Pucker



Prof. P. E. Stanga, Manchester Royal Eye Hospital, Manchester Vision Regeneration (MVR) Lab at N IHR/ Wellcome Trust Manchester CRF & University of Manchester

Case studies

- » Ikuno Y, Kawaguchi K, Nouchi T, Yasuno Y., "Choroidal thickness in healthy Japanese subjects.", *Invest Ophthalmol Vis Sci.* 2010 Apr;51(4):2173-6.
 - » Hirata M, Tsujikawa A, Matsumoto A, Hangai M, Ooto S, Yamashiro K, Akiba M, Yoshimura N., "Macular choroidal thickness and volume in normal subjects measured by swept-source optical coherence tomography.", *Invest Ophthalmol Vis Sci.* 2011 Jul 1;52(8):4971-8.
 - » Ikuno Y, Maruko I, Yasuno Y, Miura M, Sekiryu T, Nishida K, Iida T., "Reproducibility of retinal and choroidal thickness measurements in enhanced depth imaging and high-penetration optical coherence tomography.", *Invest Ophthalmol Vis Sci.* 2011 Jul 25;52(8):5536-40.
 - » Maruko I, Iida T, Sugano Y, Oyamada H, Sekiryu T., "Morphologic choroidal and scleral changes at the macula in tilted disc syndrome with staphyloma using optical coherence tomography.", *Invest Ophthalmol Vis Sci.* 2011 Nov 11;52(12):8763-8.
 - » Ohno-Matsui K, Akiba M, Moriyama M, Ishibashi T, Tokoro T, Spaide RF., "Imaging retrolbulbar subarachnoid space around optic nerve by swept-source optical coherence tomography in eyes with pathologic myopia.", *Invest Ophthalmol Vis Sci.* 2011 Dec 28;52(13):9644-50.
 - » Usui S, Ikuno Y, Miki A, Matsushita K, Yasuno Y, Nishida K., "Evaluation of the choroidal thickness using high-penetration optical coherence tomography with long wavelength in highly myopic normal-tension glaucoma.", *Am J Ophthalmol.* 2012 Jan;153(1):10-6.e1.
 - » Tsuchiya K, Moriyama M, Akiba M, Tamura Y, Ohno-Matsui K., "Development of peripapillary venous loop in an eye with a small optic disc.", *Int Ophthalmol.* 2012 Apr;32(2):171-5. Epub 2012 Feb 10.
 - » Spaide RF, Akiba M, Ohno-Matsui K., "Evaluation of peripapillary intrachoroidal cavitation with swept source and enhanced depth imaging optical coherence tomography.", *Retina.* 2012 Jun;32(6):1037-44.
 - » Ohno-Matsui K, Akiba M, Moriyama M, Shimada N, Ishibashi T, Tokoro T, Spaide RF., "Acquired Optic Nerve and Peripapillary Pits in Pathologic Myopia.", *Ophthalmology* 2012; 119: 1685-1692
 - » Jirattanasopa P, Ooto S, Tsujikawa A, Yamashiro K, Hangai M, Hirata M, Matsumoto A, Yoshimura N., "Assessment of Macular Choroidal Thickness by Optical Coherence Tomography and Angiographic Changes in Central Serous Chorioretinopathy.", *Ophthalmology* 2012; 119: 1685-1692
 - » Usui S, Ikuno Y, Akiba M, Maruko I, Sekiryu T, Nishida K, Iida T., "Circadian changes in subfoveal choroidal thickness and the relationship with circulatory factors in healthy subjects.", *Invest Ophthalmol Vis Sci.* 2012 Apr 24;53(4):2300-7.
 - » Ohno-Matsui K, Akiba M, Moriyama M, Ishibashi T, Hirakata A, Tokoro T., "Intrachoroidal Cavitation in Macular Area of Eyes With Pathologic Myopia.", *Am J Ophthalmology* 2012; 154:382-393
 - » Ellabban AA, Tsujikawa A, Matsumoto A, Ogino K, Hangai M, Ooto S, Yamashiro K, Akiba M, Yoshimura N., "Macular choroidal thickness and volume in eyes with angioid streaks measured by swept source optical coherence tomography.", *Am J Ophthalmol.* 2012 Jun;153(6):1133-1143.e1.
 - » Maruko I, Iida T, Sugano Y, Oyamada H, Akiba M, Sekiryu T., "Morphologic analysis in pathologic myopia using high-penetration optical coherence tomography.", *Invest Ophthalmol Vis Sci.* 2012 Jun 20;53(7):3834-8
 - » Ohno-Matsui K, Akiba M, Modegi T, Tomita M, Ishibashi T, Tokoro T, Moriyama M., "Association between Shape of Sclera and Myopic Retinochoroidal Lesions in Patients with Pathologic Myopia.", *Invest Ophthalmol Vis Sci.* 2012 Sep 7;53(10):6046-61
 - » Ohno-Matsui K, Akiba M, Ishibashi T, Moriyama M., "Observations of Vascular Structures within and Posterior to Sclera in Eyes with Pathologic Myopia by Swept-Source Optical Coherence Tomography.", *Invest Ophthalmol Vis Sci.* 2012 Oct 19;53(11):7290-8
 - » Ellabban AA, Tsujikawa A, Matsumoto A, Yamashiro K, Oishi A, Ooto S, Nakata I, Akagi-Kurashige Y, Miyake M, Yoshimura N, "Macular Choroidal Thickness Measured by Swept Source Optical Coherence Tomography in Eyes with Inferior Posterior Staphyloma.", *Invest Ophthalmol Vis Sci.* 2012 Oct 25. pii: iovs.12-9952v1.
 - » Ellabban AA, Tsujikawa A, Matsumoto A, Yamashiro K, Oishi A, Ooto S, Nakata I, Akagi-Kurashige Y, Miyake M, Elnahas HS, Radwan TM, Zaky KA, Yoshimura N., "Three-Dimensional Tomographic Features of Dome-Shaped Macula by Swept-Source Optical Coherence Tomography." *Am J Ophthalmol.* 2012 Nov 3.
 - » Ruiz-Moreno JM, Flores-Moreno I, Lugo F, Ruiz-Medrano J, Montero JA, Akiba M., "Macular choroidal thickness in normal pediatric population measured by Swept-Source Optical Coherence Tomography.", *Invest Ophthalmol Vis Sci.* 2012 Dec 18.
 - » Ruiz Moreno JM, "Choroidal Imaging With Swept-source Optical Coherence Tomography", *Retina Today*, November/December 2012
 - » Kyoko Ohno-Matsui, "The Shape of the Sclera Using Swept-source OCT in Eyes With Pathologic Myopia", *Retinal Physician*, Jan 2013
 - » Dr Florence Coscas, Dr Eric Souied et. al., "Swept Source OCT versus Spectral Domain-EDI-OCT dans les DMLA *Revue des outils de suivi*", *Pratiques en Ophtalmologie* • Février 2013 • vol. 7 • numéro 61 [French]
 - » Itakura H, Kishi S, Li D, Akiyama H., "Observation of posterior precortical vitreous pocket using swept-source optical coherence tomography.", *Invest Ophthalmol Vis Sci.* 2013 May 3;54(5):3102-7
 - » Kaweh Mansouri, Robert N. Weinreb, "Evaluation of retinal and choroidal thickness by swept source optical coherence tomography: repeatability and assessment of artifacts.", *AJ Ophthalmol* 2014;157:1022-1032. 2014 by Elsevier
 - » Naoko ueda-arakawa, sataro ooto, nagahisa yoshimura, "Macular Choroidal Thickness and Volume of Eyes With Reticular Pseudodrusen Using Swept-Source Optical Coherence tomography", *AJ Ophthalmol* 2014;157:994-1004.
 - » Sergio Copete, José M Ruiz-Moreno, "Direct comparison of spectral-domain and swept-source OCT in the measurement of choroidal thickness in normal eyes", *Br J Ophthalmol* 2014;98:334-338
-

- » Kaweh Mansouri, Robert N. Weinreb, "Improved visualization of deep ocular structures in glaucoma using high penetration optical coherence tomography", *Expert Rev. Med. Devices* 10(5), 621-628 (2013)
- » Young Min Lee & Se Joon Woo & Jeong-Min Hwang, "Evaluation of congenital excavated optic disc anomalies with spectral-domain and swept-source optical coherence tomography", *Graefes Arch Clin Exp Ophthalmol* DOI 10.1007/s00417-014-2680-9
- » Munemitsu Yoshikawa, Tadamichi Akagi, Nagahisa Yoshimura, "Alterations in the Neural and Connective Tissue Components of Glaucomatous Cupping After Glaucoma Surgery Using Swept-Source Optical Coherence Tomography", *Invest Ophthalmol Vis Sci.* 2014;55:477-484.
- » Alexandre Pedinielli, Eric H. Souied, Giuseppe Querques, "In Vivo Visualization of Perforating Vessels and Focal Scleral Ectasia in Pathological Myopia", *Invest Ophthalmol Vis Sci.* 2013;54:7637-7643.
- » Toshihiko Nagasawa, Yoshinori Mitamura, Hitoshi Tabuchi, "Macular Choroidal Thickness and Volume in Healthy Pediatric Individuals Measured by Swept-Source Optical Coherence Tomography", *Invest Ophthalmol Vis Sci.* 2013;54:7068-7074
- » Kohei Takayama, Nagahisa Yoshimura, "Three-Dimensional Imaging of Lamina Cribrosa Defects in Glaucoma Using Swept-Source Optical Coherence Tomography", *Invest Ophthalmol Vis Sci.* 2013;54:4798-4807
- » Yukiko Matsuo, Taiji Sakamoto, "Comparisons of Choroidal Thickness of Normal Eyes Obtained by Two Different Spectral-Domain OCT Instruments and One Swept-Source OCT Instrument", *Invest Ophthalmol Vis Sci.* 2013;54:7630-7636.
- » Jorge Ruiz-Medrano, Jos'e M. Ruiz-Moreno, "Macular Choroidal Thickness Profile in a Healthy Population Measured by Swept-Source Optical Coherence Tomography", *Invest Ophthalmol Vis Sci.* 2014;55:3532-3542
- » "Danjie Li, Shoji Kishi, Hirota Itakura, "Posterior Precortical Vitreous Pockets and Connecting Channels in Children on Swept-Source Optical Coherence Tomography", *Invest Ophthalmol Vis Sci.* 2014;55:412-2416."
- » Hirota Itakura, Shoji Kishi, "Vitreous Changes in High Myopia Observed by Swept-Source Optical Coherence Tomography", *Invest Ophthalmol Vis Sci.* 2014;55:1447-1452.
- » Kaweh Mansouri, Felipe A. Medeiros, Robert N. Weinreb, "Assessment of Choroidal Thickness and Volume during the Water Drinking Test by Swept-Source Optical Coherence Tomography", *Ophthalmology* 2013;120:2508-2516
- » Karen B. Schaal, Claudine E. Pang, Michael Engelbert, "The Premacular Bursa's Shape Revealed In Vivo by Swept-Source Optical Coherence Tomography", *Ophthalmology* 2014;121:1020-1028
- » LS Lim, G Cheung and SY Lee, "Comparison of spectral domain and swept-source optical coherence tomography in pathological myopia", *Eye* (2014) 28, 488-491
- » Anna L. Silverman, Andrew J. Tatham, Felipe A. Medeiros, Robert N. Weinreb, "Assessment of Optic Nerve Head Drusen Using Enhanced Depth Imaging and Swept Source Optical Coherence Tomography", *Silverman et al: J Neuro-Ophthalmol* 2014; 34: 198-205
- » Kaori Sayanagi, Fumi Gomi, Masahiro Akiba, Miki Sawa, Chikako Hara, Kohji Nishida, "En-face high-penetration optical coherence tomography imaging in polypoidal choroidal vasculopathy", doi: 10.1136/bjophthalmol-2013-304658
- » Zofia Michalewska, Janusz Michalewska, Zofia Nawrocka, Karolina Dulciewska-Cicecka, Jerzy Nawrocki, "Suprachoroidal Layer and suprachoroidal space delineating the outer margin of the choroid in swept-source optical coherence tomography", *Retina* 0;1-6,2014
- » Zofia Michalewska, Janusz Michalewska, Ron A. Adelman, EWA Zawlsak, Jerzy Nawrocki, "Choroidal Thickness Measured with Swept Source Optical Coherence Tomography before and after vitrectomy with interal limiting membrane peeling for idiopathic epiretinal membranes", *Retina* 0;1-5,2014
- » Janusz Michalewska, Zofia Michalewska, Zofia Nawrocka, Maciej Bednarski, Jerzy Nawrocki, "Correlation of choroidal thickness and volume measurements with axial length and age using swept-source optical coherence tomography and optical low-coherence reflectometry", *BioMed research international* volume 2014, article ID 639160
- » Tanawade RG, Muqit MM, McLeod D, Stanga PE. "Swept-source optical coherence tomography imaging in conservative and surgical management of premacular haemorrhages showing inflammatory response", *Clin Experiment Ophthalmol.* 2015 Jan;43(1):77-79
- » Muqit MM, Stanga PE. "Swept-source optical coherence tomography imaging of the cortical vitreous and the vitreoretinal interface in proliferative diabetic retinopathy: assessment of vitreoschisis, neovascularisation and the internal limiting membrane" *Br J Ophthalmol.* 2014 Jul;98(7):994-7
- » Stanga PE, Sala-Puigdollers A, Caputo S, Jaberansari H, Cien M, Gray J, D'Souza Y, Charles SJ, Biswas S, Henson DB, McLeod D, "In vivo imaging of cortical vitreous using 1050nm swept source deep range imaging optical coherence tomography", *Am J Ophthalmol.* 2014 Feb;157(2):397-404e2.
- » Sam Razavi, Eric H. Souied, Edoardo Cavallero, Michel Weber, Giuseppe Querques, "Assessment of Choroidal Topographic Changes by Swept Source Optical Coherence Tomography After Photodynamic Therapy for Central Serous Chorioretinopathy", *Am J Ophthalmol* 2014;157:852-860

Specifications

Observation & Photography of Fundus Image	
Photography Type	Color, FA*, FAF*, Red-free**
Picture Angle	45° Equivalent 30° (Digital Zoom)
Operating Distance	34.8mm
Photographable Diameter of Pupil	Normal:Φ4.0mm or more Small pupil diameter: Φ3.3mm or more
Observation & Photography of Fundus Tomogram	
Scanning Range (on fundus)	Horizontal Within 3 to 12mm Vertical Within 3 to 12mm
Scan Patterns	3D scan Linear scan (Line-scan/Cross-scan/Radial-scan)
Scan Speed	100,000 A-Scans per second
Lateral Resolution	20µm
In-depth Resolution	Digital: 2.6µm
Photographable Diameter of Pupil	Φ2.5mm or more
Observation & Photography of Fundus Image / Fundus Tomogram	
Fixation Target	Internal fixation target : • Dot matrix type organic electroluminescence (el) • The display position can be changed and adjusted • The displaying method can be changed Peripheral fixation target : • This is displayed according to the internal fixation target display position • External fixation target
Observation & Photography of Anterior Segment***	
Photography Type	IR
Operating Distance	17mm
Observation & photography of Anterior Segment Tomogram***	
Operating Distance	17mm
Scan Range (on cornea)	Horizontal Within 3 to 16mm Vertical Within 3 to 16mm
Scan Pattern	3D scan Linear scan (Line-scan/Radial-scan)
Scan Speed	100,000 A-Scans per second
Fixation Target	Internal fixation target External fixation target
Electric Rating	
Power Source	Voltage: 100-240V Frequency: 50-60Hz
Power Input	250VA
Dimensions / Weight	
Dimensions	320-359 mm(W) X 523-554 mm(D) X 560-590 mm(H)
Weight	21.8kg (DRI OCT Triton) 23.8kg (DRI OCT Triton Plus)

* FA photography and FAF photography can be performed in only DRI OCT Triton plus.

** In this digital red-free photography, the color image is processed and is displayed as a pseudo red-free photographed image.

*** Observation & photography of anterior segment can be performed only when the anterior segment attachment kit is used. The design and the specifications are subject to change without prior notice for the product improvement.

* Not available for sale in the US

** Not available in all countries, please check with your distributor for availability in your country.



IMPORTANT Subject to change in design and/or specifications without advanced notice.
In order to obtain the best results with this instrument, please be sure to review all user instructions prior to operation.

Topcon Europe Medical B.V.
Essebaan 11; 2908 LJ Capelle a/d IJssel; P.O. Box 145;
2900 AC Capelle a/d IJssel; The Netherlands
Phone: +31-(0)10-4585077; Fax: +31-(0)10-4585045
E-mail: medical@topcon.eu; www.topcon-medical.eu

Topcon Denmark
Praestemarksvej 25; 4000 Roskilde, Danmark
Phone: +45-46-327500; Fax: +45-46-327555
E-mail: info@topcon.dk
www.topcon.dk

Topcon Scandinavia A.B.
Neogatan 2; P.O. Box 25; 43151 Mölndal, Sweden
Phone: +46-(0)31-7109200; Fax: +46-(0)31-7109249
E-mail: medical@topcon.se; www.topcon.se

Topcon España S.A.
HEAD OFFICE; Frederic Mompou, 4;
08960 Sant Just Desvern; Barcelona, Spain
Phone: +34-93-4734057; Fax: +34-93-4733932
E-mail: medica@topcon.es; www.topcon.es

Topcon Italy
Viale dell' Industria 60;
20037 Paderno Dugnano, (MI) Italy
Phone: +39-02-9186671; Fax: +39-02-91081091
E-mail: info@topcon.it; www.topcon.it

Topcon France
BAT A1; 3 route de la révolte, 93206 Saint Denis Cedex
Phone: +33-(0)1-49212323; Fax: +33-(0)1-49212324
E-mail: topcon@topcon.fr; www.topcon-medical.fr

Topcon Deutschland GmbH
Hanns-Martin-Schleyer Strasse 41;
D-47877 Willich, Germany
Phone: (+49) 2154-885-0; Fax: (+49) 2154-885-177
E-mail: info@topcon-medical.de; www.topcon-medical.de

Topcon Polska Sp. z o.o.
ul. Warszawska 23; 42-470 Siewierz; Poland
Phone: +48-(0)32-670-50-45; Fax:
+48-(0)32-671-34-05
www.topcon-polska.pl

Topcon (Great Britain) Ltd.
Topcon House; Kennet Side; Bone Lane; Newbury
Berkshire RG14 5PX; United Kingdom
Phone: +44-(0)1635-551120; Fax: +44-(0)1635-551170
E-mail: medical@topcon.co.uk; www.topcon.co.uk

Topcon Ireland
Unit 276, Blanchardstown; Corporate Park 2
Ballycoolin; Dublin 15, Ireland
Phone: +353-18975900; Fax: +353-18293915
E-mail: medical@topcon.ie; www.topcon.ie