



Scanning Laser Imaging

“The detail and contrast in the MultiColor images has helped me identify pathologies which were unclear on the corresponding color fundus images.”

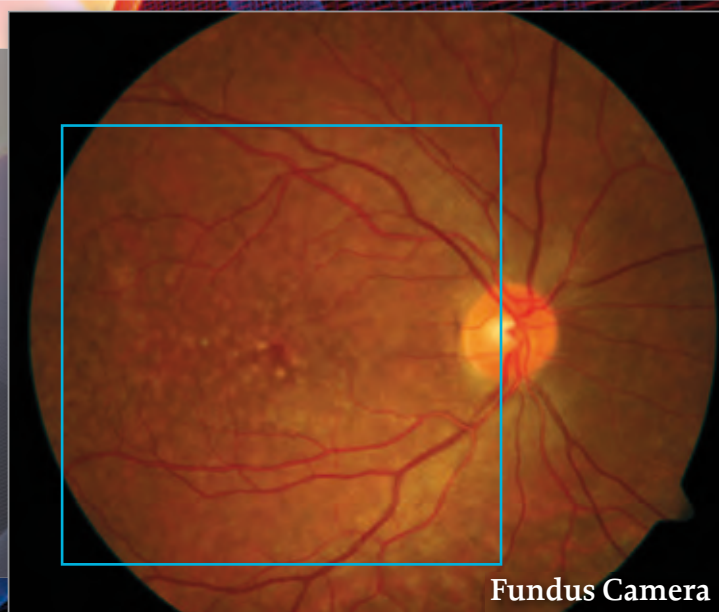
Sebastian Wolf, MD, PhD

MultiColor™ – Scanning Laser Imaging brings a new dimension to the SPECTRALIS multi-modality platform by combining simultaneous SD-OCT and selective color fundus imaging.

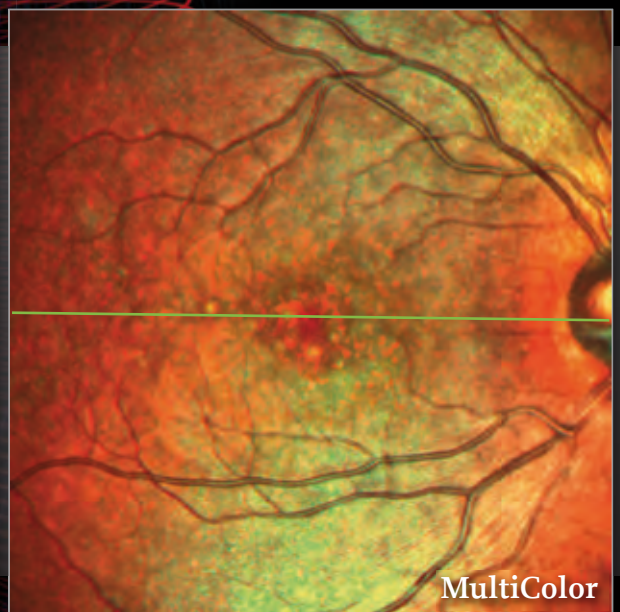Simultaneous imaging with multiple laser colors provides diagnostic information originating from various structures at different depths within the retina.

SPECTRALIS MultiColor imaging delivers high contrast, detailed images even in difficult patients like those with cataract or nystagmus. The image clarity and detail is a result of SPECTRALIS core technologies: confocal laser scanning, active live eye tracking and noise reduction technology.

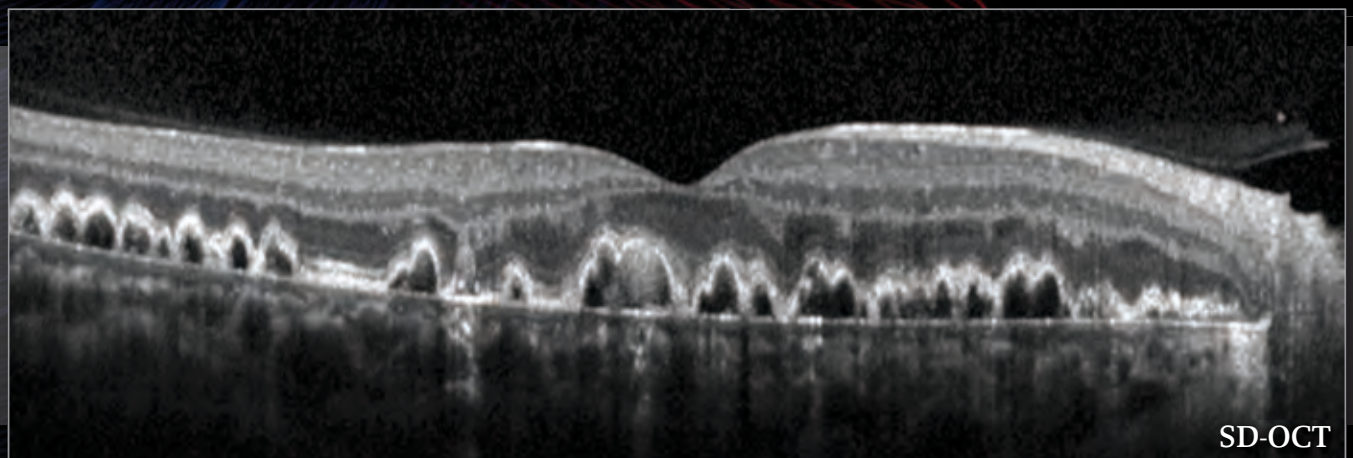
Multi-modality MultiColor Imaging



Fundus Camera



MultiColor

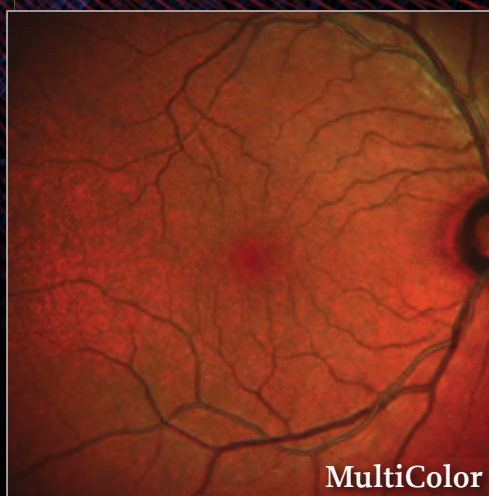
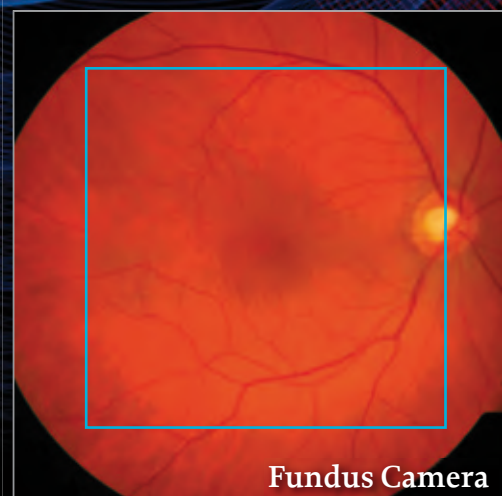
SD-OCT

Multiple small to mid-size drusen appear well delineated in the MultiColor image. The simultaneous SD-OCT image confirms the confluent drusen pattern.

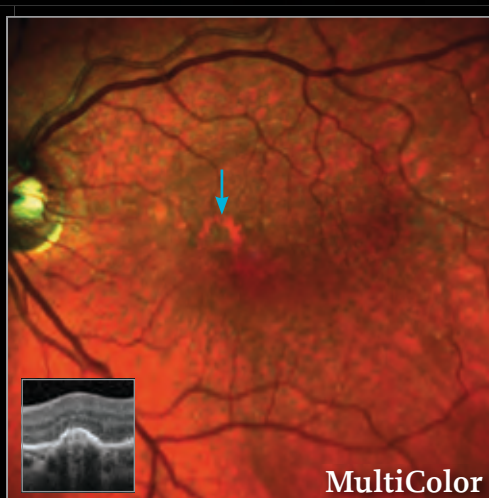
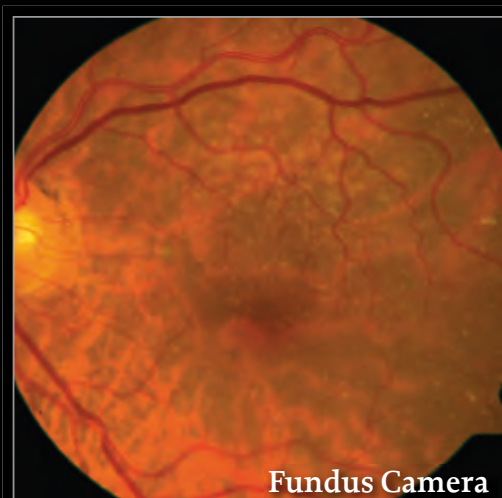
The Detail of SPECTRALIS MultiColor Scanning Laser Imaging

Healthy Subject



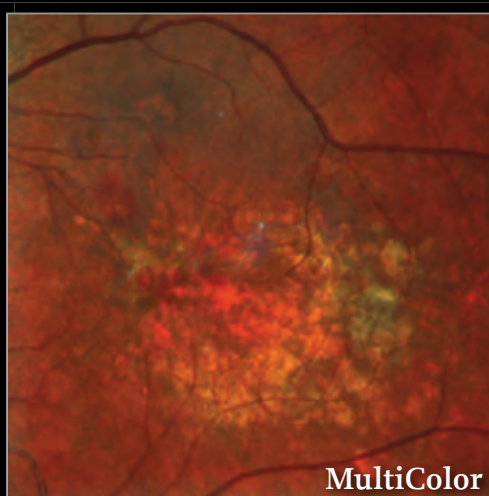
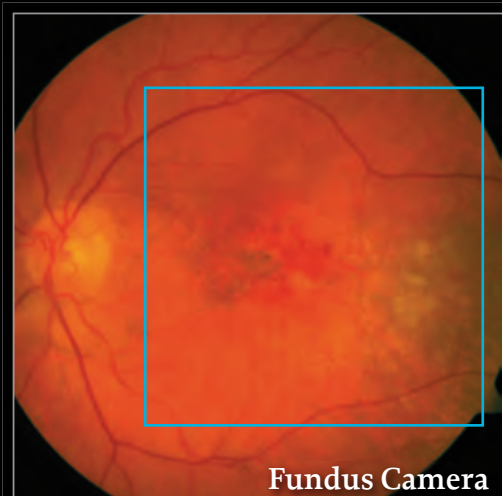
High contrast and quality of the MultiColor image allow identification of fine anatomic details.

Reticular Drusen



The presence and extent of multiple reticular drusen is readily visible in the MultiColor image. It also highlights an area of abnormal RPE (arrow) which might be difficult to identify in the fundus camera image. The simultaneous SD-OCT image confirms an elevation of the RPE at this location.

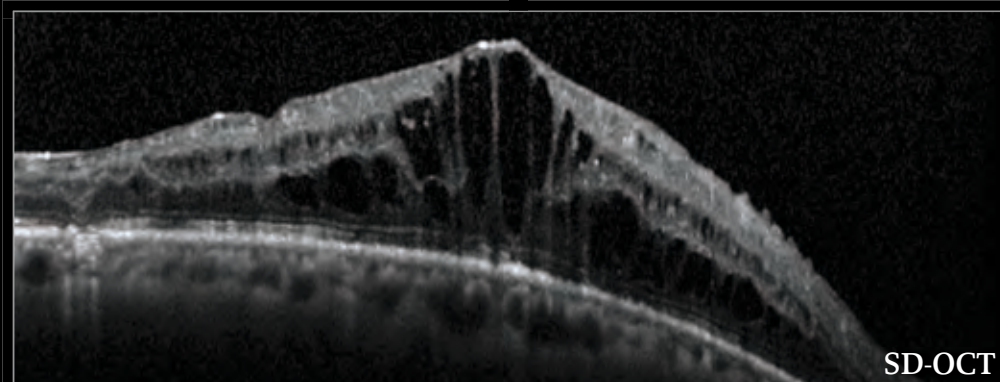
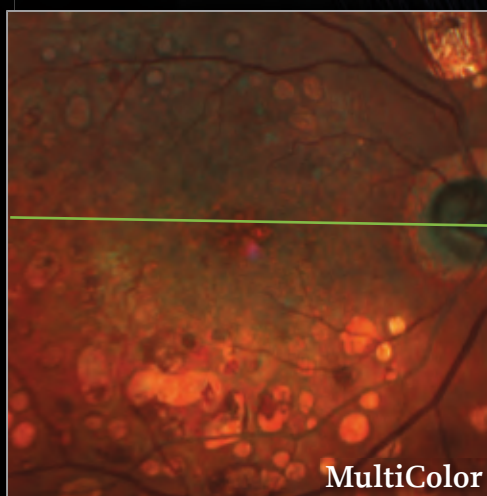
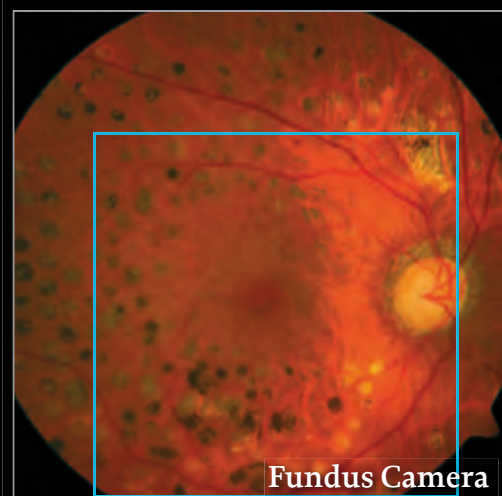
Exudative AMD



The MultiColor image reveals the full extent of subretinal and RPE alterations.

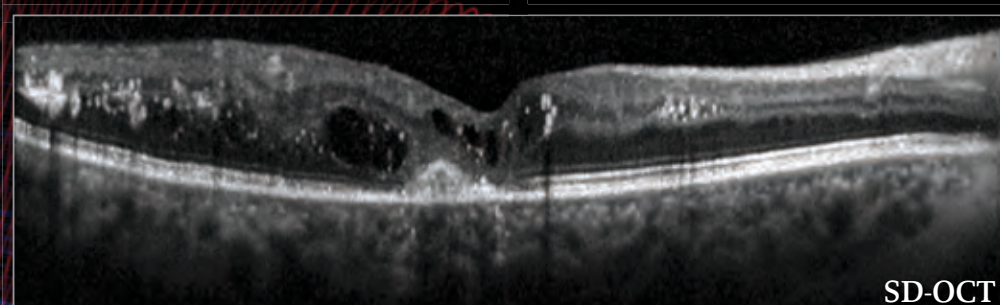
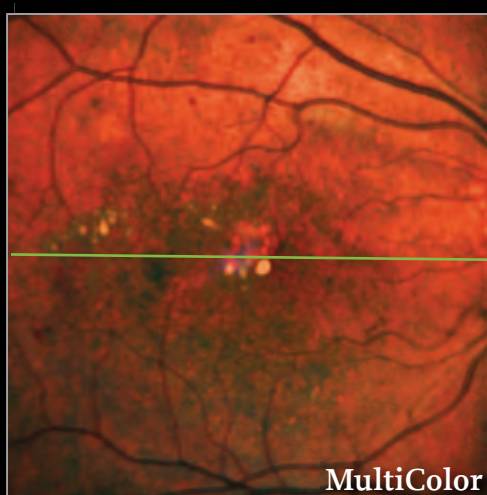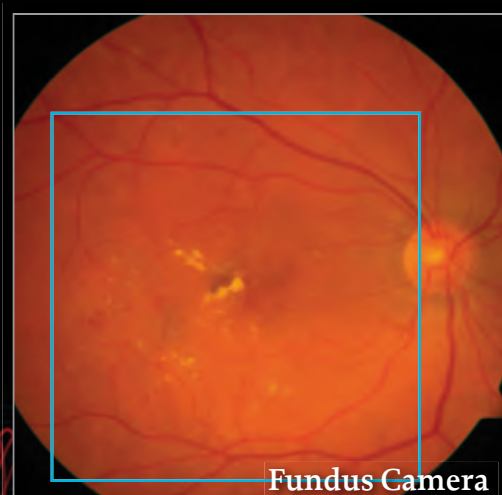
The Precision of Multi-modality Imaging with SPECTRALIS

Diabetic Retinopathy – Diabetic Macular Edema



Case 1

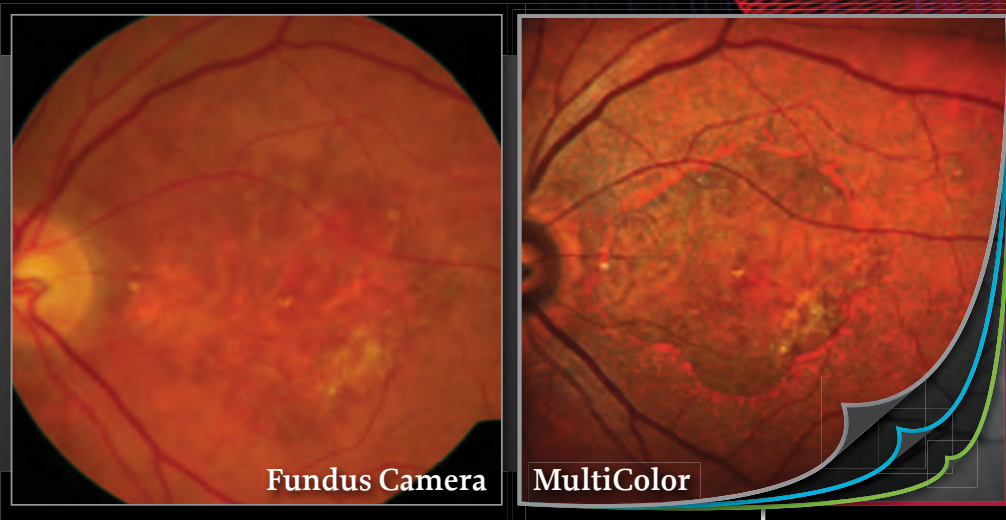
The fundus camera and SPECTRALIS MultiColor images show multiple areas of fibrotic tissue due to laser photocoagulation. The MultiColor image reveals an area of abnormal structure in the macula which may be difficult to identify on the fundus camera image. The simultaneous SD-OCT image shows diffuse thickening of the retina and cystoid macula edema.



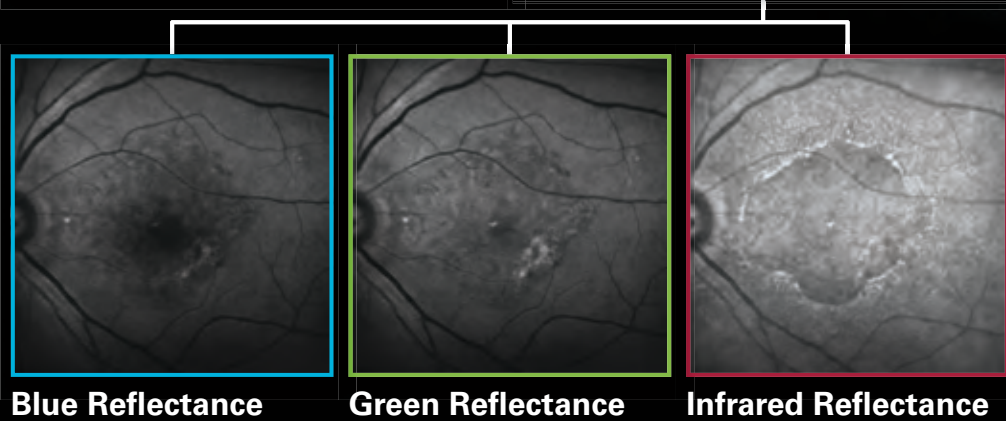
Case 2

Hard exudates and signs of bleeding in diabetic retinopathy. The full extent of structural change is visible in the MultiColor image which also shows the highly reflective macula alterations. The simultaneous SD-OCT confirms intraretinal cysts in this area.

The Versatility of MultiColor Imaging



The area of geographic atrophy is clearly demarcated in the MultiColor image. In addition, the peripheral reticular drusen are more easily identified.



The MultiColor image is composed of three simultaneously acquired selective color laser images. The versatility to view both the MultiColor image and the individual color images provides additional diagnostic power by highlighting structural detail from different depths within the retina.



Now available for all SPECTRALIS models

	OCT	OCT ^{Plus}	HRA	HRA+OCT
OCT	Spectral-Domain OCT	■	■	■
	EDI-OCT	■	■	■
	Anterior Segment Module*	■	■	■
Fundus Imaging	Infrared Reflectance	■	■	■
	MultiColor™ scanning laser imaging	■	■	■
	BluePeak™ blue laser autofluorescence	■	■	■
	Blue Reflectance	■	■	■
	Fluorescein Angiography	■	■	■
	ICG Angiography	■	■	■
Widefield Imaging		■	■	■
Panning Camera		■	■	■
Upgradable to HRA + OCT		■	■	n/a

TruTrack™ Active Eye Tracking - Heidelberg Noise Reduction™ - AutoRescan™ - HEYEX™ Image Management Software

■ optional * upgradable
93500-002 Er12 © Heidelberg Engineering GmbH

MultiColor not available for sale in the USA

Images courtesy of S. Wolf, MD, PhD and A. Zenger, MD, Inselspital Bern, Switzerland